


# **Congenital Heart diseases**

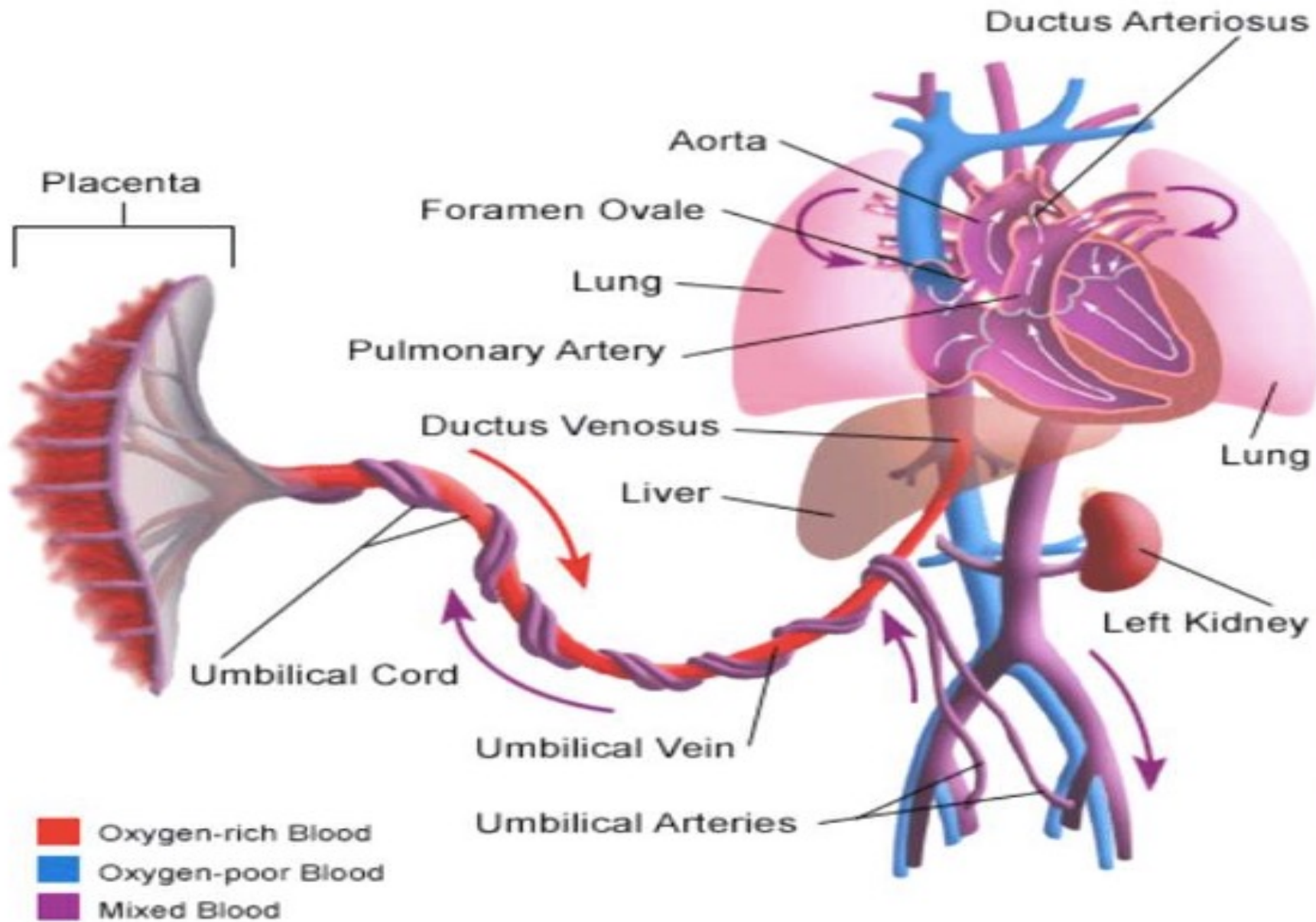


# OBJECTIVES

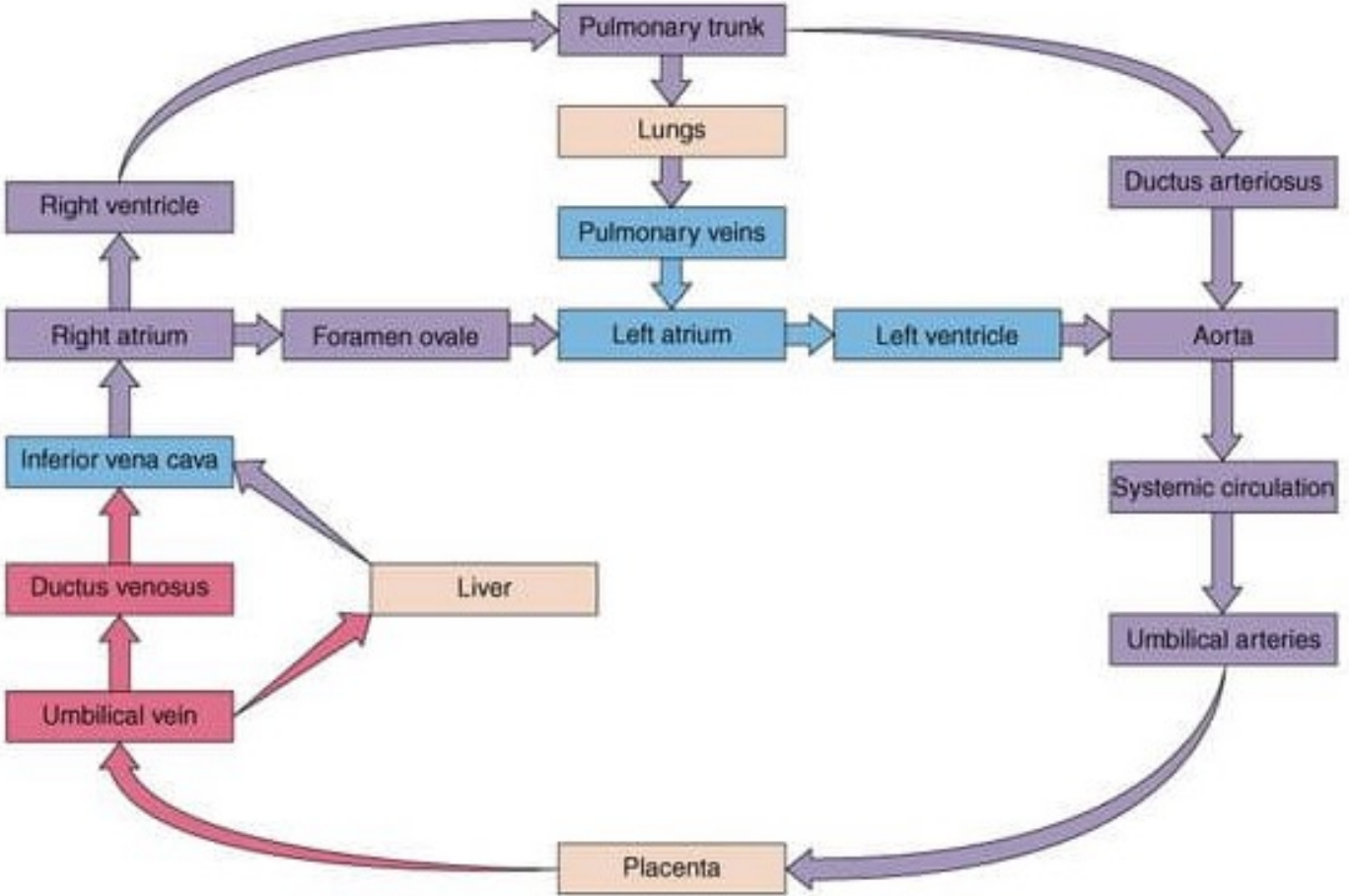
- Fetal Circulation
  - Congenital Heart Diseases (CHD)
    - ❑ Incidence
    - ❑ Mortality and Morbidity
    - ❑ Etiological Factors
  - Classification of CHD
    - ❑ Cyanotic
    - ❑ Acyanotic
  - Hemodynamics of Common CHD Assessment & Management
- 



# Fetal Circulation



# FETAL CIRCULATION




# Changes in Fetal circulation after birth

- Closure of umbilical arteries
- Closure of umbilical vein
- Closure of ductus venosus
- Closure of ductus arteriosus
- Closure of foramen ovale
- Enlargement of pulmonary veins

# Definition and Incidence

- malformation of the heart or great vessels which occurs during intrauterine development, irrespective of the age at presentation.
  - Congenital heart disease occurs in approximately 0.8% of live births.
  - The incidence is higher in stillborns (3-4%), spontaneous abortuses (10-25%), and premature infants (about 2% excluding patent ductus arteriosus [PDA])
- 



# Etiology

- **Environmental factors**

1. Viral Infections

- rubella during the first three months of pregnancy

2. Medication

- lithium (used to manage bipolar disorder), Accutane (acne medication), some anti-seizure medications


3. Alcohol

- with fetal alcohol syndrome (FAS)

4. Smoking

5. Cocaine

6. Maternal chronic illnesses –diabetes, phenylketonuria (PKU) and a deficiency in the B vitamin folic acid.




- **Genetic factors**

1. Hereditary : occur in siblings or offspring of individuals with heart defects than those without

2. Mutations –can affect the formation of the heart and lead to congenital heart malformations

3. Linked with other birth defects – More than one-third of children born with Down syndrome have heart defects. About 25% of girls with Turner syndrome have heart defects

---





# Classification Of CHD

## Acyanotic

Left to right  
shunt

Outflow  
obstruction

Ventricular septal  
defect

Atrial septal  
defect

Persistent ductus  
arteriosus

Pulmonary  
Stenosis

Aortic Stenosis

Coarctation of  
aorta

## Cyanotic

Tetralogy of Fallot (TOF)

Transposition of the great arteries

Tricuspid Atresia


Truncus arteriosus

Total anomalous pulmonary venous  
return

Common Ventricle

# **ACyanotic Heart Diseases**

---



# Atrial Septal defect (ASD)

- An abnormal opening in the atrial septum which allows oxygenated blood from the left atrium to mix with deoxygenated blood in the right atrium at a minor pressure difference
  - Right atrium receives blood from SVC, IVC as well as from left atrium leading to volume overload and pulmonary congestion
  - Occurs in about 4-10% of CHD
  - More common in female child
-


# Types of ASD

- **Ostium Secundum**
    - most common- 50-70%,
    - In the middle of the septum in the region of the foramen ovale
  - **Ostium primum**
    - 30% -Low position
    - Form of AV septal defect
  - **Sinus venosus**
    - Least common-10%
    - Site-at entry of superior venacava into right atrium
- 



# Types of ASD

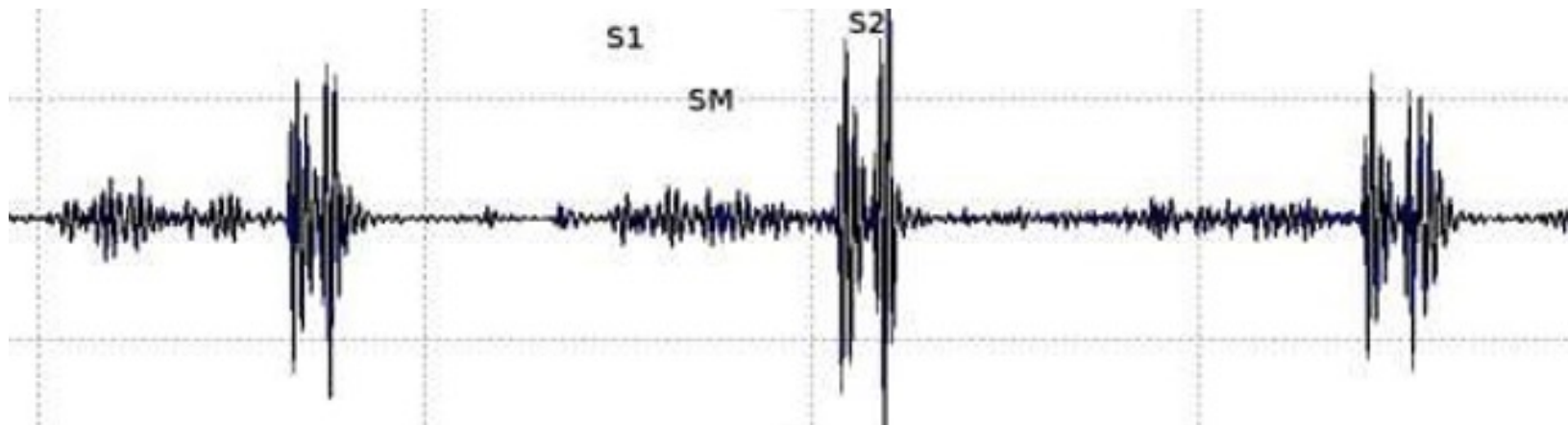
- Most infants and children are asymptomatic but over years to decades may experience the symptoms depending on type and severity of ASD
    - ✓ Infant gets tired during feeding
    - ✓ Child gets tired with playing/eating
    - ✓ Shortness of breath
    - ✓ Fatigue
    - ✓ Sweating
    - ✓ Palpitations
    - ✓ Stunted growth
- 




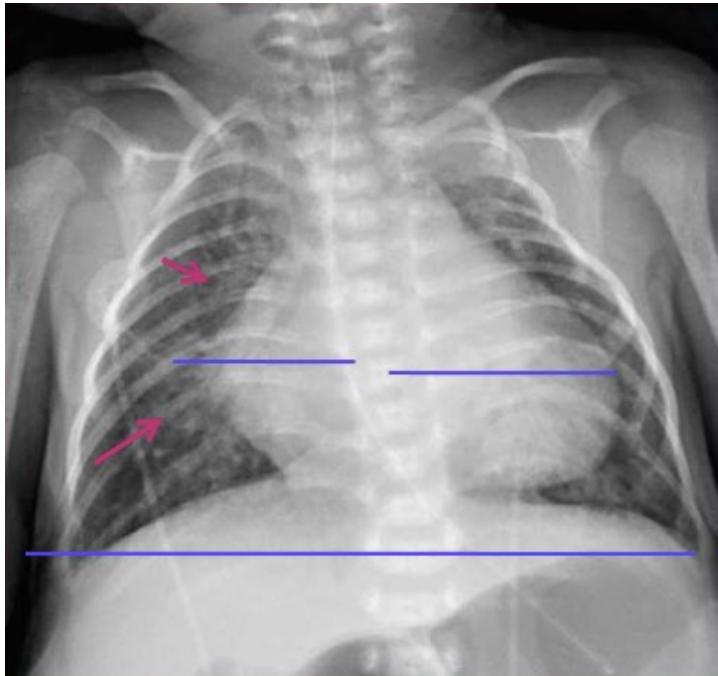
# Diagnosis

- On Auscultation-

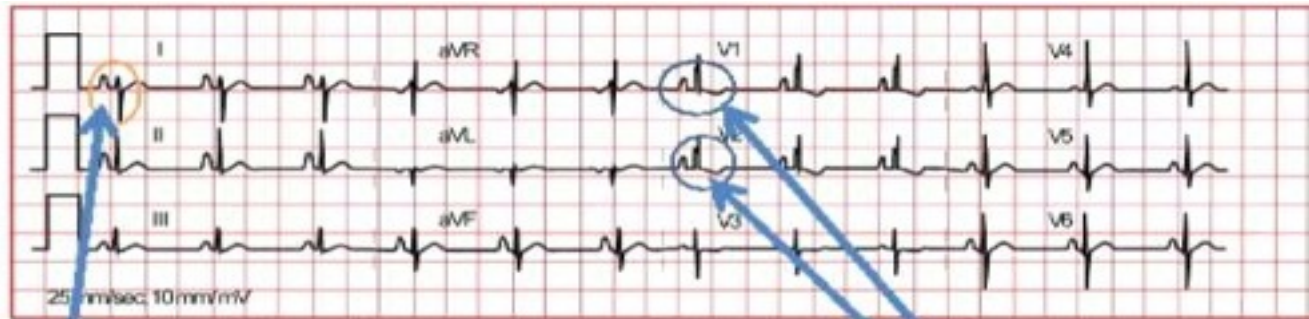
- ✓ S1 :normal
- ✓ S2: Widely split & fixed with P2 accentuated
- ✓ Ejection systolic murmur is present



- **Chest X-ray** - Mild to moderate cardiomegaly with enlarged right atrium & right ventricle, prominent pulmonary artery segment, increased pulmonary vascular markings



- ECG- Right Axis Deviation, Right ventricular strain pattern in lead V<sub>1</sub>
- Echocardiogram- position, size, signs of L→R shunt, flow



Enlarged 'p' wave indicating Right atrial hypertrophy

Also note that the aVF is predominantly upwards as compared to Lead I indicating Right Axis Deviation

rSR' seen and tall R wave indicating RBBB and RVH


LAD with rSR' in V1 is suggestive of Ostium primum defect



# Management


- 20% of atrial septal defects will close spontaneously in the first year of life or as the child grows
  - For defects of 3-8mm, or smaller, supportive
    - medical management – Digoxin, diuretics and
    - prophylactic antibiotics are sufficient up till spontaneous closure
-

- If defect is >8mm, surgical repair may be is required
  - If spontaneous closure does not occur by school-going age, surgical repair becomes essential to prevent lung problems that will develop from long-time exposure to extra blood flow
  - Surgical repair- defect may be closed with stitches or a special patch. The material utilized for patch closure of ASD's may be the patient's own pericardium, commercially available bovine pericardium, or synthetic material
- 



# Ventricular Septal Defect (VSD)

- An abnormal opening in the ventricular septum which allows oxygenated blood from the left ventricle to mix with deoxygenated blood in the right ventricle
  - Right ventricle receives blood from right atrium as well as from left ventricle leading to volume overload and pulmonary congestion
- VSDs are the most commonly occurring type of congenital heart defect, occurring in 14-17 % of babies born each year
- 



# Types of VSD

- **Supracristal VSD**
    - occurs just beneath the aortic valve at the left ventricular outflow tract
  - **Membranous VSD**
    - The most common type and originate inferior to the crista supraventricularis
  - **Muscular VSD**
    - Occur in the mid to apical interventricular septum
- 




# Clinical Presentation

- Signs and symptoms vary with the size of the defect.
  - Clinical symptoms are usually not seen at birth because of continued high pulmonary vascular resistance in the newborn
  - Infants with moderate to large defects will become symptomatic within the first few weeks of life.
    - ✓ Shortness of breath while feeding
    - ✓ Poor growth
    - ✓ Failure to gain weight
    - ✓ Pounding Heart
    - ✓ Frequent respiratory tract infections
    - ✓ If reversal of shunt occurs : cyanosis , clubbing , respiratory distress
-

# Diagnosis


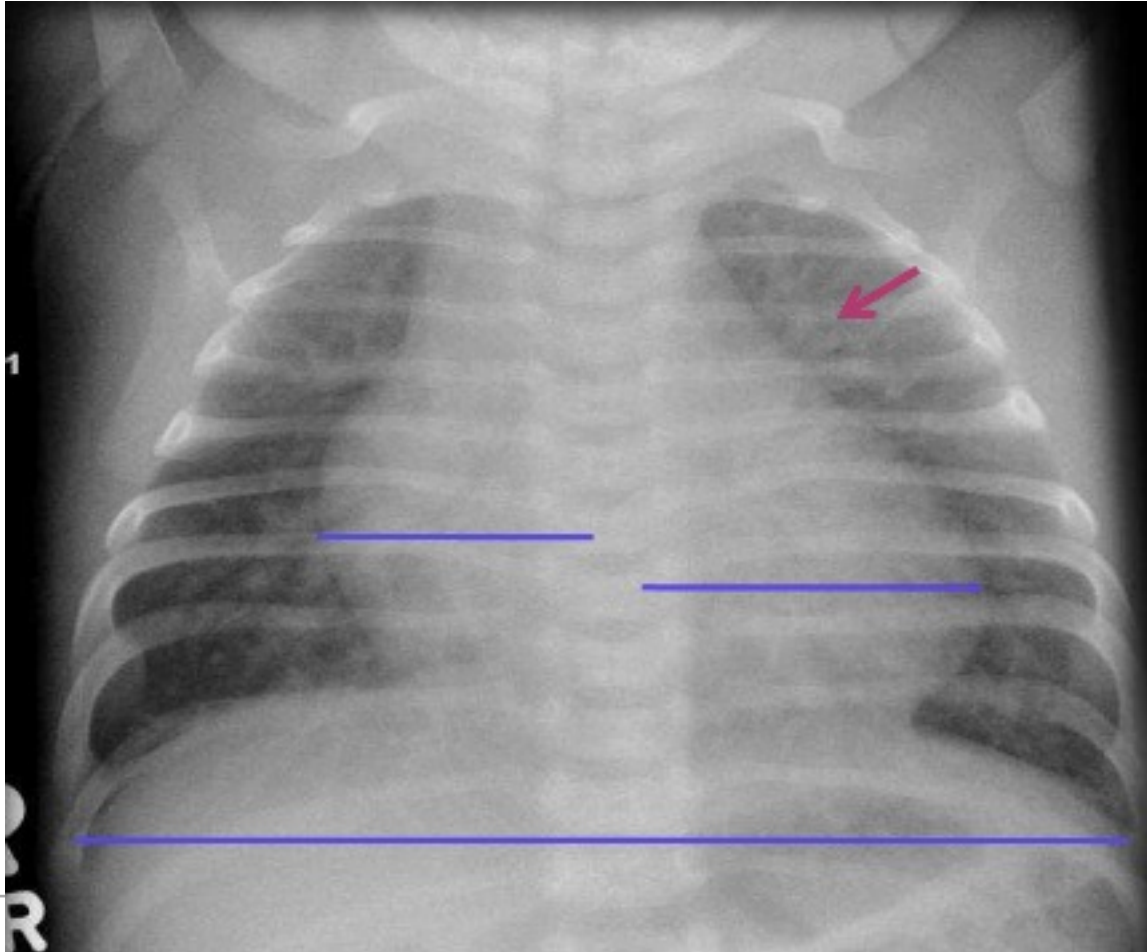
- **On Auscultation**

- ✓ Pansystolic murmur is present
  - ✓ S1 is masked by the murmur
  - ✓ S3 can be heard at the apex
- 




- Chest X-ray-

\_Cardiomegaly and increased pulmonary vascular markings



# Management

- Medical management
    - ✓ digoxin
    - ✓ Diuretics
  - Adequate nutrition
    - ✓ high-calorie formula or breast milk
    - ✓ supplemental tube feedings
  - Prophylactic antibiotics to prevent bacterial endocarditis
- 






- Surgical repair – closed stitches or special patch

Interventional cardiac catheterization – Septal occluder

Outcome of Surgery- 95% success rate, growth of child catches up in 1-2 years, size of the heart reduces, murmurs can be heard 2-3 months post-operative also but hold very little clinical importance




# Patent Ductus Arteriosis (PDA)

- Failure of closure of ductus arteriosus
    - **Incidence:** Mostly in premature infants or infants born to a mother who had rubella during the first trimester of pregnancy
    - characterized by a connection between the aorta and the pulmonary artery
    - All babies are born with a ductus arteriosus.
    - As the baby takes the first breath, the blood vessels in the lungs open up, and blood begins to flow the ductus arteriosus is not needed to bypass the lungs
    - Most babies have a closed ductus arteriosus by 72 hours after birth.
    - In some babies, however, the ductus arteriosus remains open (patent) .
    - The opening between the aorta and the pulmonary artery allows oxygenated blood to pass back through the blood vessels in the lungs.
    - PDA occurs in 6-11 % of all children with CHD
-

# Clinical Presentation

- Shortness of breath
  - Congested breathing
  - Disinterest in feeding, or tiring while feeding
  - Poor weight gain
  - Sweating
  - Tachypnea
  - Bounding pulse
- 




# Diagnosis

- **On Auscultation**

- ✓ Continuous machinery murmur in the left infraclavicular region

---



# Management

## ✓ **Medical Management**

- Indomethacin IV (prostaglandin inhibitor) may help close a PDA. It works by stimulating the muscles inside the PDA to constrict, thereby closing the connection
  - Digoxin
  - Diuretics

## ✓ **Adequate nutrition**


- High-calorie formula or breast milk
  - Special nutritional supplements may be added to formula or pumped breast milk that increase the number of calories in each ounce
-

## ✓ **Surgical Management**


- Repair is usually indicated in infants younger than 6 months of age who have large defects that are causing symptoms, such as poor weight gain and rapid breathing
  - Transcatheter coil closure of the PDA
  - PDA ligation-involves closing the open PDA with stitches or the vessel connecting the aorta and pulmonary artery may be cut and cauterized
-

# Cyanotic Heart Diseases

---




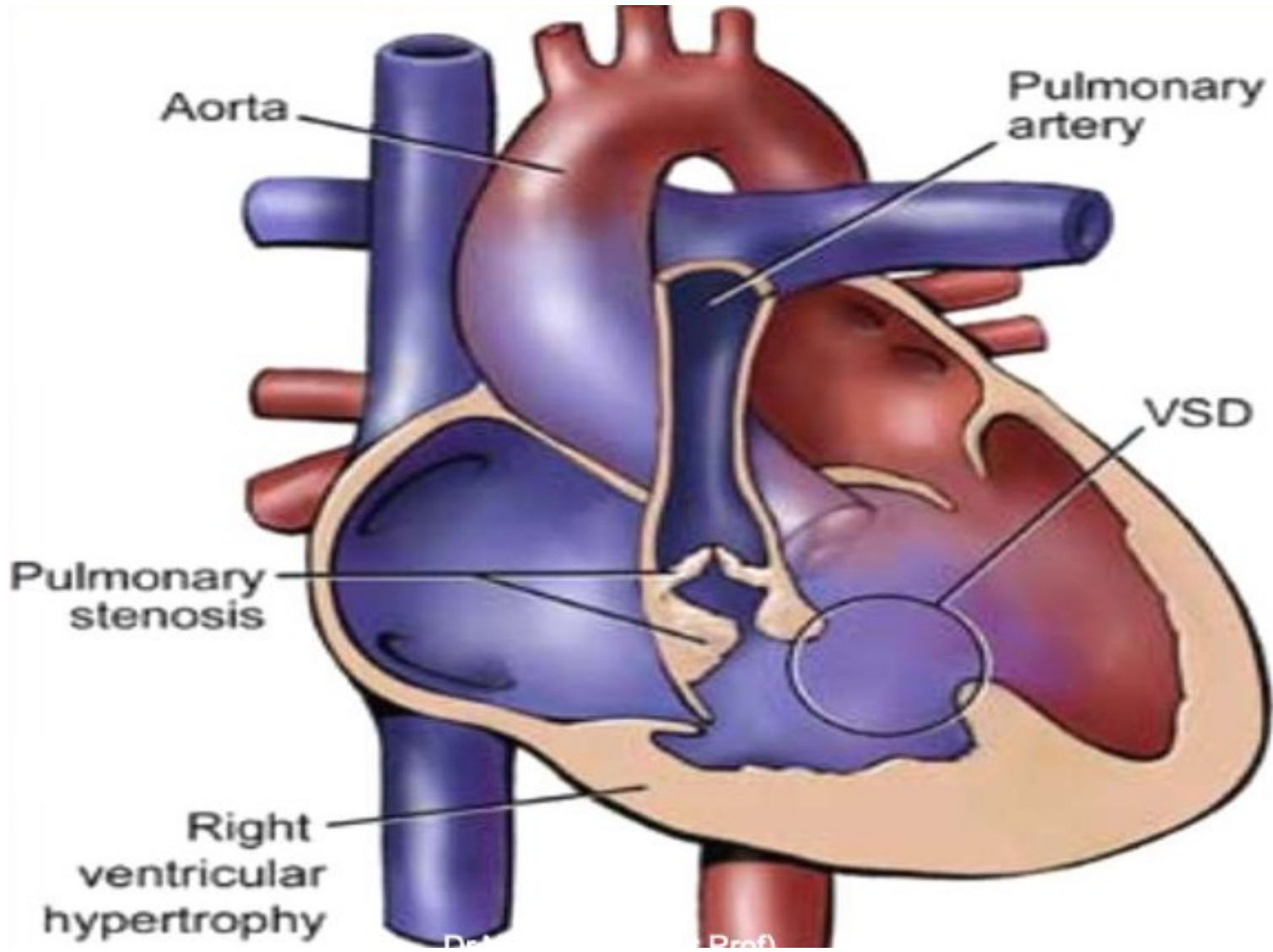
- These type of defects lead to either increased or decreased pulmonary blood flow
  - The primary pathology arises either due to an obstructive lesion; or due to abnormal anatomy or both
  - The shunt present is predominantly from Right to Left leading to shunting of venous blood without passing through the lungs to be oxygenated
  - Unoxygenated blood circulates in arteries → cyanosis
  - Example: Tetralogy of Fallot, TGV
- 





# Tetralogy of Fallot (TOF)

- A complex condition of several congenital defects that occur due to abnormal development of the fetal heart during the first 8 weeks of pregnancy
  - *'Tetra'* meaning *'four'*
    - ✓ Ventricular septal defect (VSD)
    - ✓ Pulmonary valve stenosis
    - ✓ Overriding aorta
    - ✓ Right ventricular hypertrophy
-



# Cont...


- Due to pulmonary artery stenosis, RV has to work harder to push blood into the lungs, thereby increasing the RV pressure and size

Presence of VSD facilitates blood to pass from the RV into the left ventricle, and mixing of blood takes place.

- Overriding of aorta- The aorta sits above both the left and right ventricles over the VSD, rather than just over the left ventricle. As a result, oxygen poor blood from the right ventricle can flow directly into the aorta instead of into the pulmonary artery to the lungs

Decreased pulmonary blood flow and poorly oxygenated blood circulating through out the body leads to CYNOSIS

---



# Clinical presentation

- Cyanosis (bluish color of the skin, lips, and nail beds) that occurs with such activity as crying or feeding
- Irritability
- Lethargic
- Reduced physical activity
- Fainting
- Clubbing of nails of fingers/toes
- Breathing difficulty

Children with Tetralogy of Fallot exhibit bluish skin during episodes of crying or feeding.




"Tet spell"

# Diagnosis

- **On Auscultation-**

An ejection systolic murmur is present at the Left parasternal region 3<sup>rd</sup> ICS due to pulmonary stenosis.

---




# Management

Requires surgical repair usually undertaken at 6-18 months age

It involves- closure of VSD with a tangential patch

- to correct the override and the pulmonary stenosis is relieved with a patch).




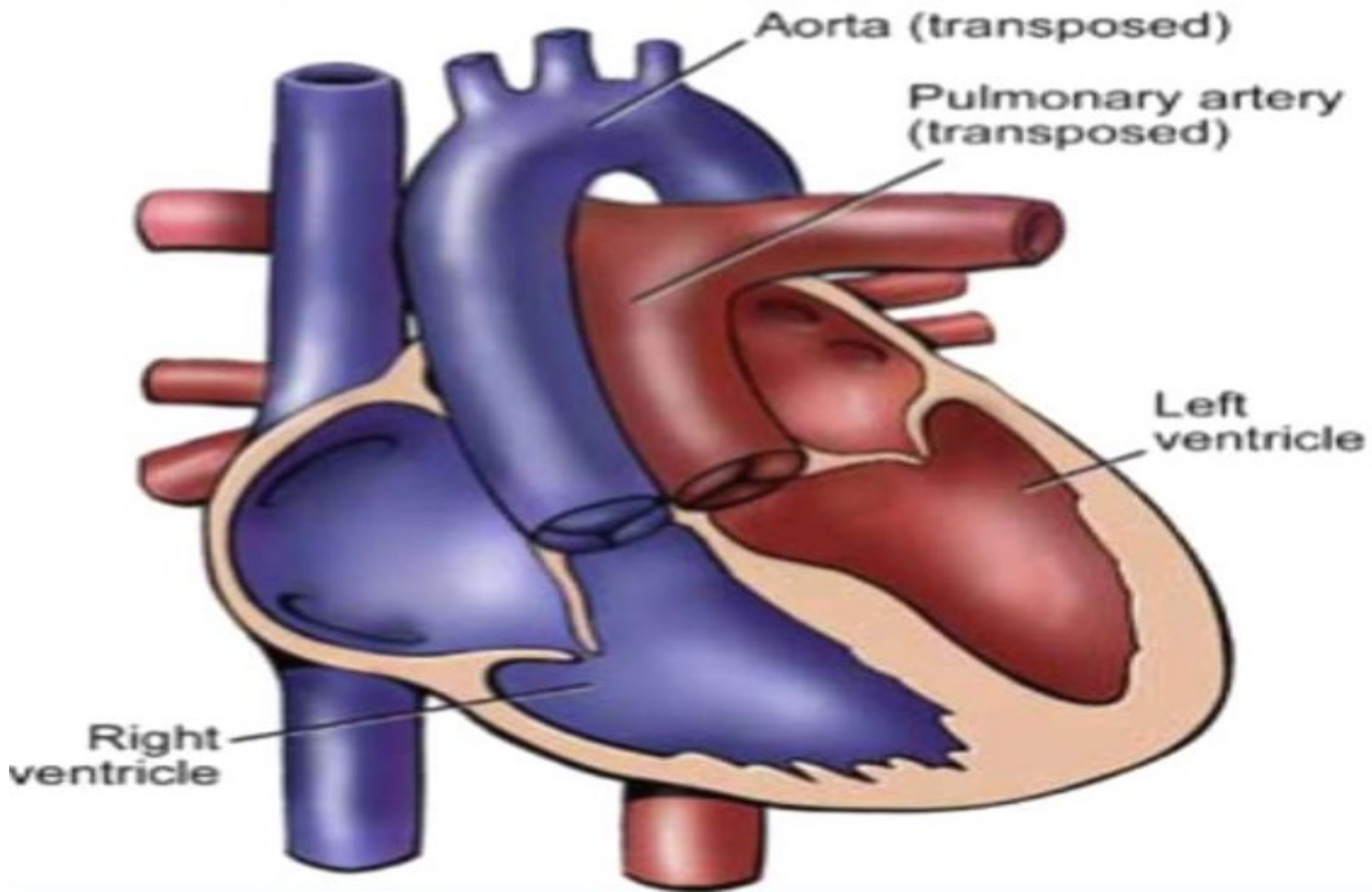
# Transposition of Great Vessels (TOG)

- The aorta is connected to the right ventricle, and the pulmonary artery is connected to the left ventricle

**Oxygen – poor (blue)** blood returns to the right atrium from the body passes through the right atrium and ventricle, into the misconnected aorta back to the body.

**Oxygen-rich (red) blood** returns to the left atrium from the lungs passes through the left atrium and ventricle, into the pulmonary artery and back to the lungs.


---





# Clinical Presentation:

- Cyanosis : (bluish color of the skin, lips, and nail beds) that occurs with such activity as crying or feeding
  - Rapid and laboured breathing
  - Cold and clammy skin
  - Failure to thrive
- 



# Management

- Admitted to NICU
  - On ventilator support
  - Cardiac Catheterization
  - Ballon Atrial Septostomy
  - I.v. Prostaglandins administered
  - By 2<sup>nd</sup> week of life, TGA repair is done
  - *'Switch'* operation
- 

