

TUBULAR DISORDERS AND TUBULOINTERSTITIAL DISEASES

Prof. Mohamed A. Sobh

This group of diseases are either specific tubular disorders or a tubulointerstitial nephritis

I. Specific tubular disorders

These includes the following:

- 1- Carbohydrate tubular transport defect
 - Renal glycosuria
- 2- Amino acid tubular transport defects
 - Hartnups disease
 - Cystinuria and cystinosis
- 3- Renal Tubular Acidosis (RTA)
 - Classic (Distal) RTA
 - Proximal RTA
- 4- Abnormal water Handling
 - Nephrogenic diabetes inspidus (NDI)
 - Water Retention
- 5- Others
 - Wilson's Disease
 - Bartters Syndrome
 - Oxalosis
 - Vitamin D Resistant Rickets
 - Fanconi Syndrome
 - Pseudohypoparathyroidism

II. Tubulointerstitial Nephritis:

- Acute tubulointerstitial nephritis
- Chronic tubulointerstitial nephritis
- Analgesic Nephropathy
- Reflux Nephropathy
- Pyelonephritis

Renal Glycosuria

Normally glucose does not appear in the urine until plasma concentration reaches up to 180 mg/dl (10 mmol/L). This is called renal threshold.

Maximum glucose excretion is reached at plasma concentration of 270 mg/dl (15 mmol/L). This is called (tubular maximum or T_m).

Renal glucosuria means the detection of glucose in urine while plasma glucose is less than 180 mg/dl (i.e. decreased renal threshold).

There are two types of renal glycosuria, type A in which both renal threshold and T_m are reduced; and type B in which renal threshold is decreased but T_m is not.

Genetics: It is transmitted as autosomal recessive, few families have been reported with autosomal dominant inheritance.

Clinical features:

These are persistent throughout the life with no symptoms unless starvation occurs, the patients will suffer from severe hypoglycemia, hypovolaemia and ketosis.

Diagnosis:

By detection of glycosuria while plasma glucose is less than 135 mg/dl (7.3 mmol/L).

ACUTE INTERSTITIAL NEPHRITIS (AIN)

Etiology:

1. Drug or Toxin induced:

Antibiotics are the most commonly implicated drugs, in acute interstitial nephritis.

Methicillin is the most frequent but penicillin, ampicillin, rifampicin, phenandione, sulfonamides, co-trimoxazole, thiazides and phenytoin are frequently implicated and are more important clinically.

Drugs involved but less frequently are non-steroidal anti-inflammatory drugs (NSAIDS), diuretics, analgesics and H2-antagonists.

Toxins which can induce tubulointerstitial nephritis are organic solvents, ochratoxin (fungal toxin).

2. Infection-related acute interstitial nephritis:

May result from direct invasion of the renal interstitium by the organism (mainly the renal medulla which is involved with picture of acute pyelonephritis) or may be associated with a systemic infection without direct renal involvement by bacteria.

The lesion will be caused by bacterial toxin or through an immunologic process triggered by bacterial infection.

3. Idiopathic and immune mediated disease: Such as Sjogren's syndrome, SLE and transplant rejection.

Pathology:

Macroscopically, the kidney looks normal or increased in size.

Microscopically, there is interstitial edema and cellular infiltrate. Tubules may look normal or show necrosis, glomeruli; and blood vessels are intact. The infiltrating inflammatory cells are predominantly lymphocytes and plasma cells. In addition, neutrophils and eosinophils will be seen in drug induced AIN.

The condition may regress completely or progress to chronic interstitial nephritis if the offending cause is persistent.

Clinical Presentation:

The disease varies from severe hypersensitivity syndrome with fever, rash, eosinophilia and acute renal failure to asymptomatic increase in plasma creatinine or abnormal urinary sediment without evidence of renal insufficiency.

In cases of drug induced AIN the interval between exposure to drug and the onset of symptoms varies from hours to months.

Differential diagnosis:

This includes acute tubular necrosis, rapidly progressive glomerulonephritis and athero-embolic renal artery disease.

History of drug intake or exposure to toxic substance or infection is important. Presence of skin rash, fever, eosinophilia, tubular proteinuria (usually < 1g/24 h), leucocyturia, microscopic haematuria and eosinophiluria are findings supporting the diagnosis of AIN. Kidney biopsy will settle the final diagnosis.

N.B. Absence of eosinophilia or eosinophiluria does not exclude AIN.

Treatment:

1. Discontinuation of the causative drug and treatment of infection and supportive treatment may be sufficient to induce recovery.
2. Steroids are sometimes given (unless there are contraindications) to shorten the course of illness and prevent permanent renal damage

CHRONIC INTERSTITIAL NEPHRITIS (CIN)

There are many conditions that may lead to CIN. The most common are analgesic nephropathy, reflux nephropathy, gouty nephropathy, obstructive nephropathy and chronic pyelonephritis.

Complete list of CAUSES OF CHRONIC INTERSTITIAL NEPHRITIS

1. Chronic phase following acute interstitial nephritis.
2. Drugs (analgesics, lithium).
3. Heavy metals (cadmium, mercury, lead).
4. Reflux nephropathy.
5. Metabolic (gout, hyperoxaluria, hypercalcaemia).
6. Radiation.
7. Sarcoidosis.
8. Balkan endemic nephropathy.
9. Sjögren syndrome.
- 10 Neoplastic disorders (multiple myeloma,
- 11 leukemia, lymphoma, light chain nephropathy).
- 12 Transplant rejection.

Pathology:

Macroscopically, the kidney is small, atrophic.

Microscopically, non-specific changes are seen including interstitial fibrosis, chronic inflammatory cellular infiltration and tubular atrophy.

Clinical presentation :

1. Manifestations of the etiologic cause.
2. Manifestations of chronic renal impairment which may progress to end stage renal disease.

Treatment:

1. Of the etiologic cause, and
2. Treatment of the chronic renal failure, whether conservative or with renal replacement therapy in advanced stages (dialysis and transplantation).

PYELONEPHRITIS

Is a microbial infection involving renal pelvis and renal parenchyma.

Pyelitis means an infection mainly affecting the renal pelvis.

Pyelonephritis is usually associated with constitutional symptoms (fever, rigors,...) due to parenchymatous involvement, while pyelitis like other viscous organ infection (e.g. cystitis and urethritis) is not.

Pyelonephritis may be acute or chronic

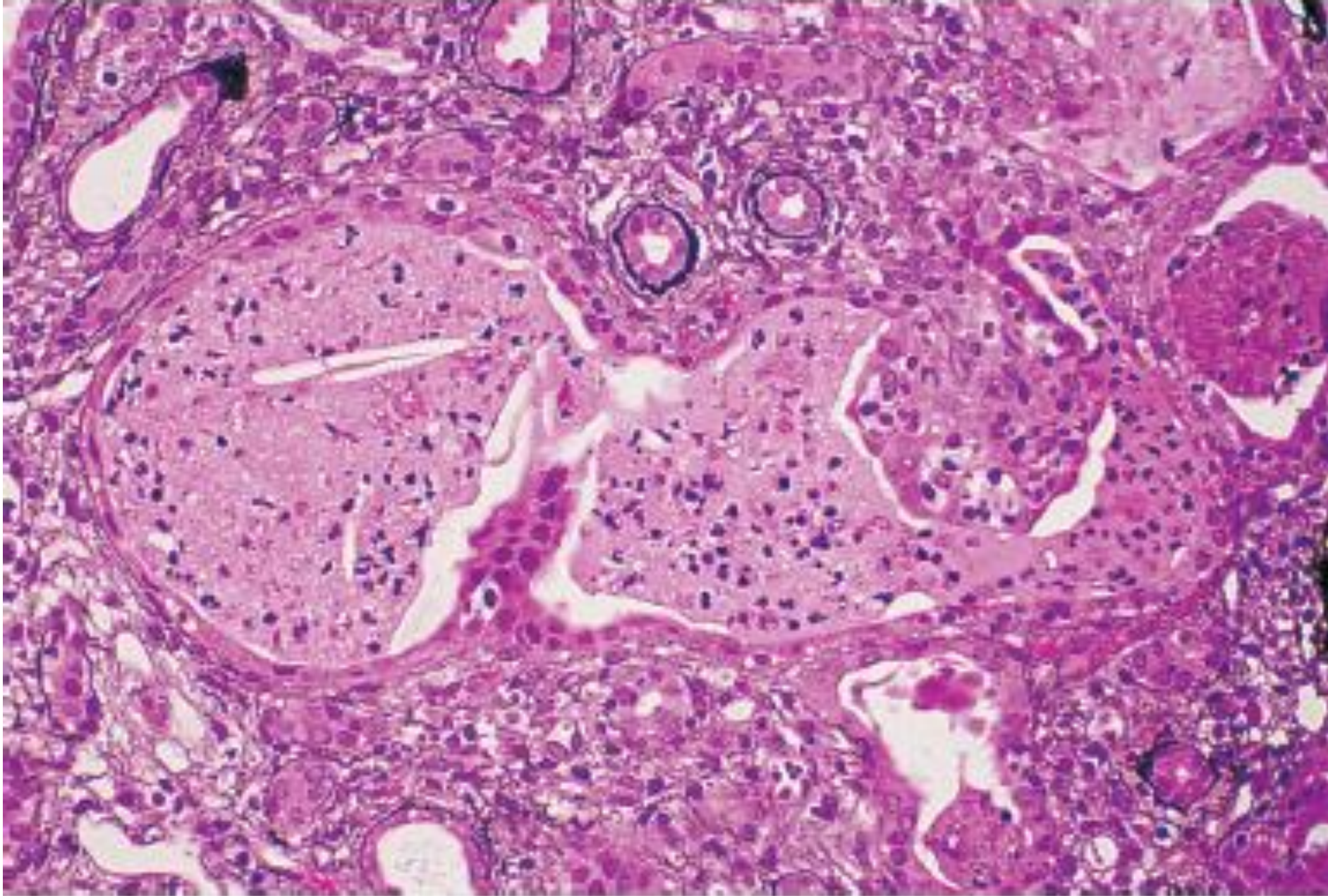
ACUTE PYELONEPHRITIS

Predisposing factors:

1. Anatomical abnormalities: as vesico-ureteric reflux, ureteric stricture or congenital kidney disease as horse shoe kidney.
2. Renal stones.
3. Obstruction of the urinary tract causing stasis of urine as in cases of senile prostatic enlargement and bladder neck obstruction.
4. Diabetes mellitus: due to its predisposition to infection, this risk will be magnified on presence of diabetic nephropathy.
5. Analgesic nephropathy: due to the interstitial fibrosis and the abnormal urinary epithelium caused by chronic exposure to these drugs.
6. Instrumentation: as cystoscopy which may introduce organisms into the urinary tract.
7. Neurogenic bladder which leads to residual urine in the bladder and stasis creating a good medium for bacterial multiplication.
8. Following primary renal disease e.g. nephrotic syndrome.

Precipitating factors specific for female patients:

1. Short urethra allowing easy passage of bacteria from the perineal area to the bladder.
2. Trauma such as honey moon cystitis (cystitis occurring in early marriage).
3. Stasis with pregnancy: due to hormones secreted during pregnancy causing relaxation of ureteric muscles and ureteric dilatation.



Acute pyelonephritis. Renal tissue shows a dilated tubule with neutrophils enmeshed in proteinaceous debris (“pus casts”) with adjacent interstitial inflammation.

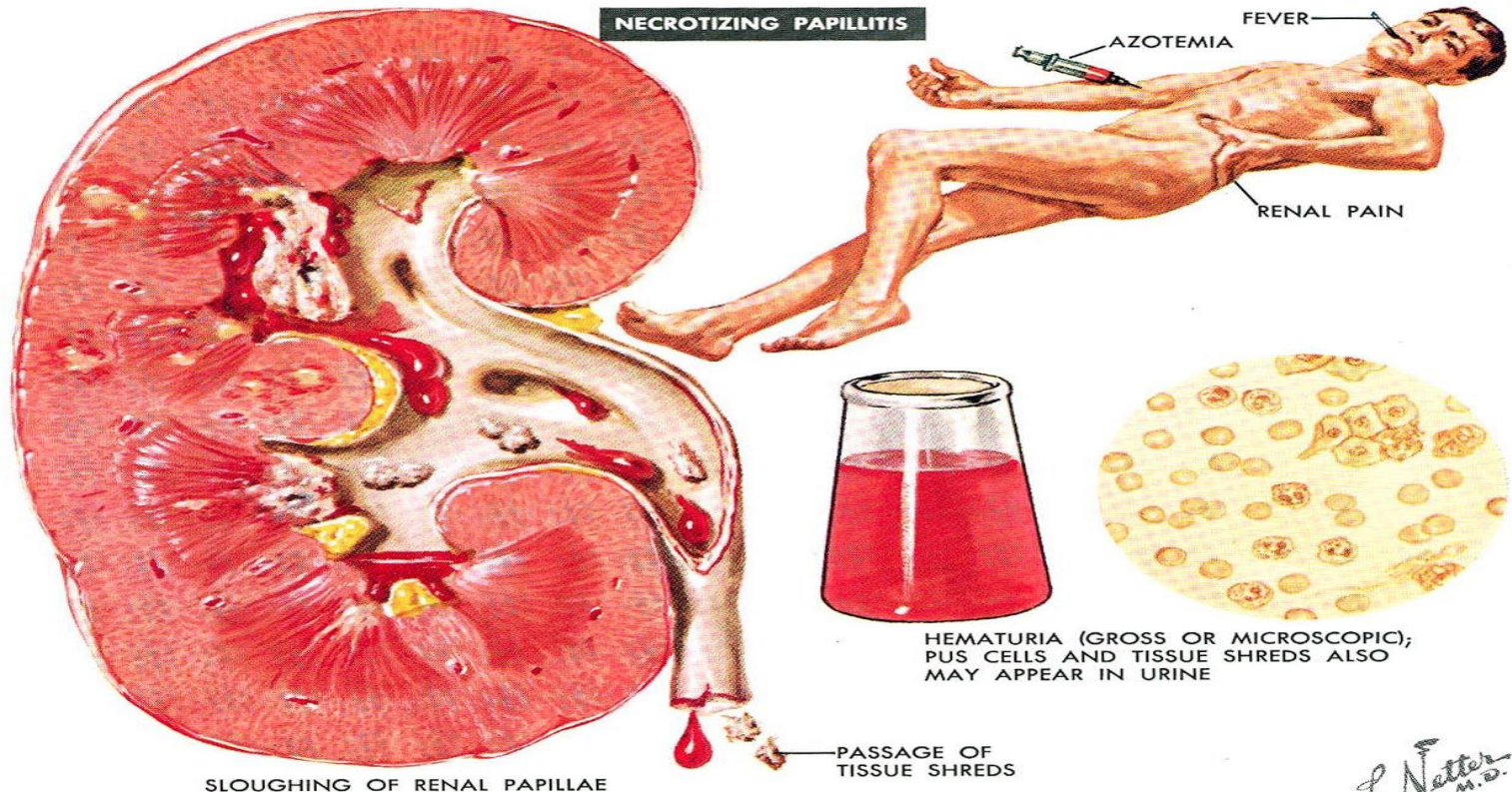
Symptoms:

Fever, malaise, aches, dysuria, frequency of micturition, hematuria and papillae may pass in urine causing renal colic (especially in diabetic patients). In children, abdominal pain and screaming on micturation.

Signs:

Tender loin and suprapubic area and the urine may look turbid and may smell fishy (in Proteus infection).

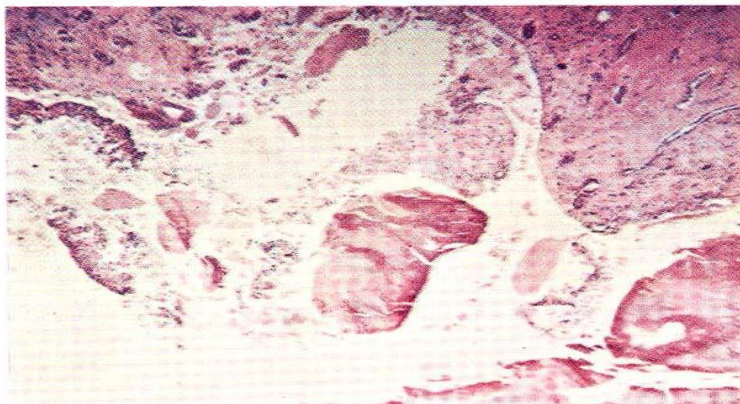
NECROTIZING PAPILLITIS



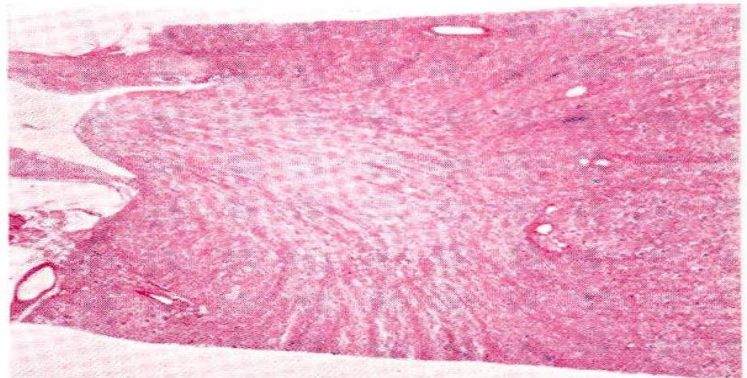
SLOUGHING OF RENAL PAPILLAE

HEMATURIA (GROSS OR MICROSCOPIC); PUS CELLS AND TISSUE SHREDS ALSO MAY APPEAR IN URINE

F. Netter
M.D.
© CIBA



PAPILLARY NECROSIS WITH SLOUGHING, LEAVING A CONCAVE INNER BORDER OF THE MEDULLA. DETACHED DEAD FRAGMENTS CAN BE FOUND IN THE URINE



PAPILLARY NECROSIS WITHOUT INFLAMMATORY REACTION: BELIEVED BY SOME TO BE CHARACTERISTIC OF ANALGESIC PAPILLARY NECROSIS

Investigations:

1. Urine examination including:

- (a) Microscopic examination which will show pus cells and sometimes bacteria .
- (b) Urine culture to detect bacterial count (significant count is $> 100,000$ bacteria/ml urine), for identification of type of organism, and to detect degree of sensitivity to antibiotics which is important for treatment, especially in complicated cases.

For urine culture, the urine should be free of contamination. This could be achieved by using midstream urine sample in adults or suprapubic aspiration of urine in children. This is done by puncturing the full bladder by a fine needle after disinfecting the skin of suprapubic area.

The most common organism causing acute pyelonephritis is E.coli, followed by coliforms bacteria.

In cases with anatomic abnormality in urinary tract or with instrumentation the common organisms are pseudomonas, proteus, and k. aurogenosa.

Causes of sterile pyuria (pus cells with negative repeated cultures) are:

1. Urinary T.B. (needs special media to grow).
2. Renal stones.
3. Urethritis (caused by virus, fungus or chlamydia.... etc.)
4. Analgesic nephropathy.
5. Nonspecific inflammation of the bladder.

2. Kidney function tests: Serum creatinine and creatinine clearance. Renal dysfunction could be a preceding event or a complication of pyelonephritis and its presence will affect the mode of treatment of acute pyelonephritis.

3. Renal ultrasonography to diagnose precipitating factors as stone or back pressure

4. IVP , CT with contrast : After single attack in male and repeated attacks in females to diagnose stone disease or anatomic abnormality, e.g. ureteric stricture, back pressure changes.

5. Kidney biopsy: Is not indicated for diagnosis as it may disseminate infection.

Treatment:

1. High fluid intake to induce diuresis to wash pus and bacteria out.
2. Antimicrobial therapy:

For first or uncomplicated infection we may start with fluoroquinolone (ciprofloxacin , levofloxacin) , Amoxicillin-clavulanate or Septrin for 7-10 days.

For resistant, recurrent or complicated infection antibiotic may be chosen according to urine culture and antibiotic sensitivity test.

Changing urine pH is indicated with anatomic abnormalities especially when the sensitivity test shows gentamicin as the best choice. Alkaline urine is needed for gentamicin, sulfonamide, streptomycin. Acidic urine is needed for tetracycline and mandelamine.

Relapse of infection (same organism) or reinfection (different organism) is usually due to wrong choice of antibiotic, inadequate dose or duration of treatment, female sex and anatomic abnormality.

This could be managed through a proper vulval hygiene, long antibiotic suppressive therapy (after full course of antibiotic give a daily evening dose for 3-6 months) and correcting any anatomic abnormality

CHRONIC PYELONEPHRITIS

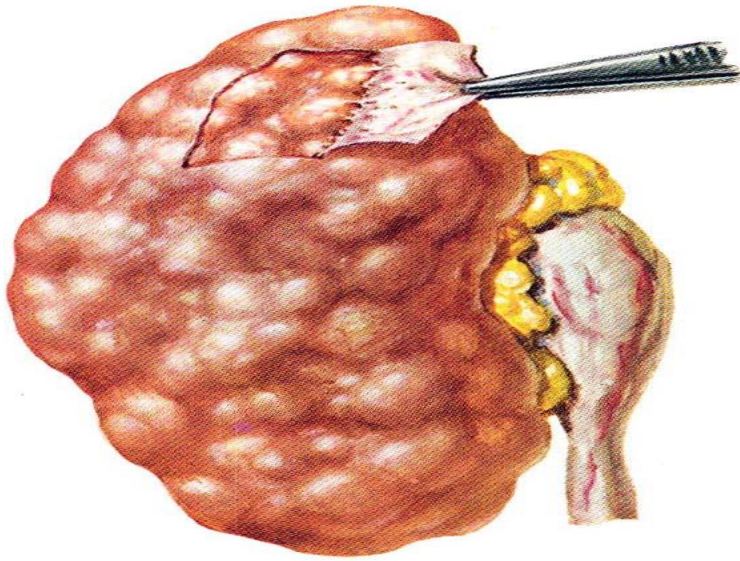
Is believed to be the result of chronic or repeated renal bacterial infection.

Often at presentation, proof of the bacterial etiology is unavailable

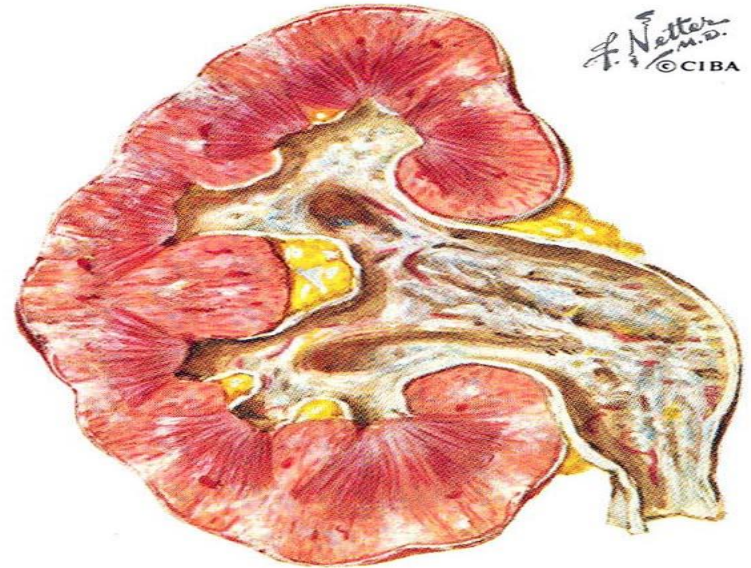
Pathology:

Gross Appearance: Affected kidney is decreased in size with irregular outline (due to underlying scars).

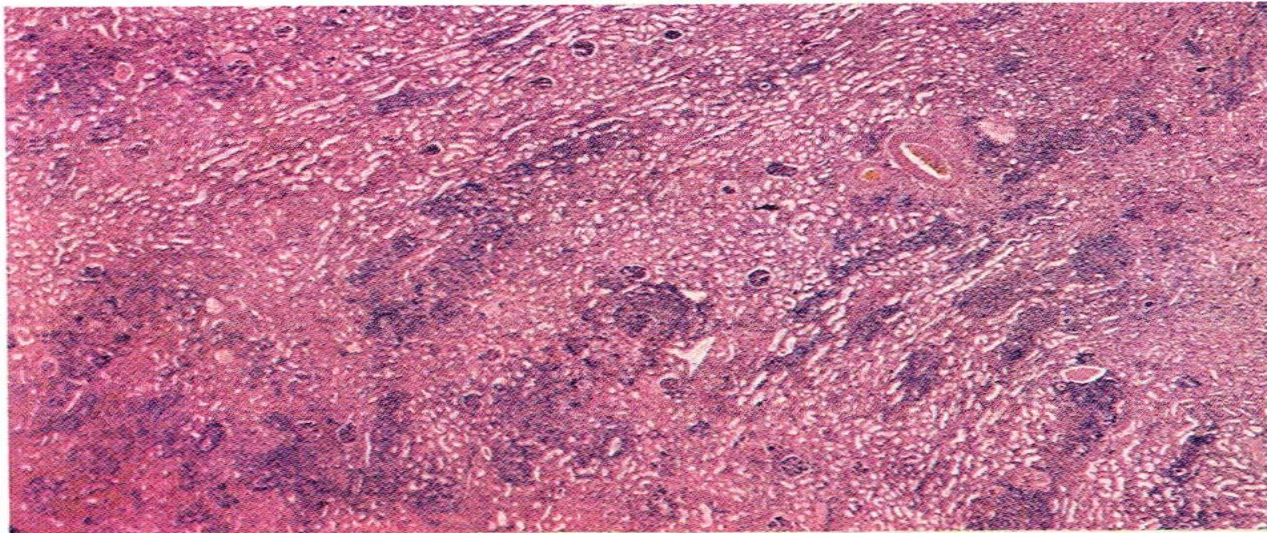
Microscopy: A nonspecific appearance is similar to any type of chronic interstitial nephritis. There is irregular, patchy, cortical infiltration with inflammatory cells, tubular atrophy and interstitial fibrosis. Vascular changes of hypertension may be evident (thickening of the wall with duplication of internal elastic lamina and narrowing of arterial lumen).



COARSELY GRANULAR CONTRACTED KIDNEY, WITH BLUNT, U-SHAPED DEPRESSIONS SOMETIMES SEEN IN CHRONIC PYELONEPHRITIS; IN MANY INSTANCES THE KIDNEY IS INDISTINGUISHABLE FROM THAT OF NEPHROSCLEROSIS; THICKENED CAPSULE IS ADHERENT



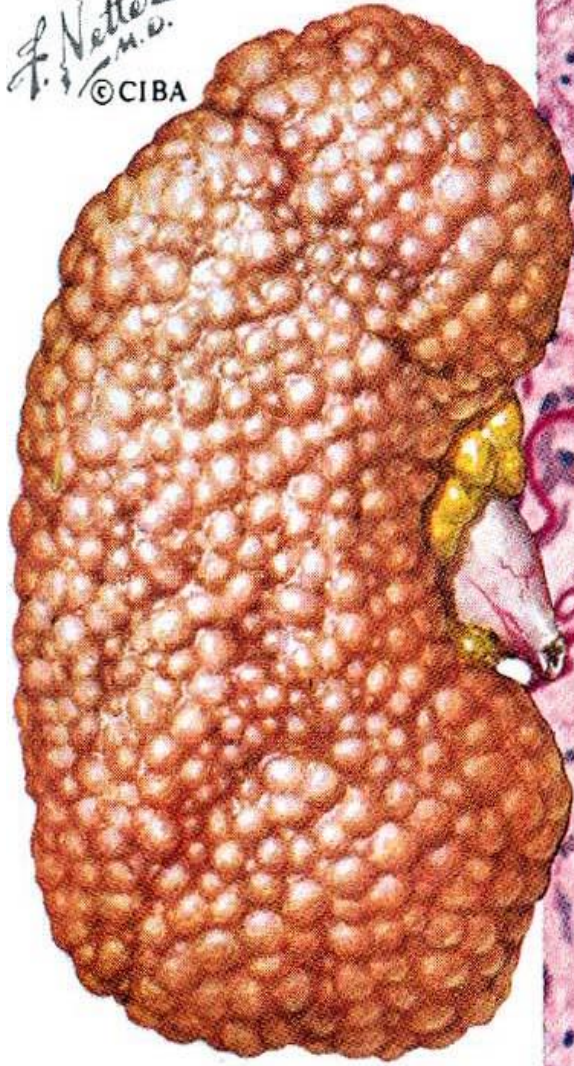
THINNING OF RENAL PARENCHYMA WITH WEDGE-SHAPED SUBCAPSULAR SCARS; BLURRING OF CORTICOMEDULLARY JUNCTION; DILATED, FIBROSED PELVIS AND CALYCES SEEN IN MANY BUT NOT ALL CASES OF CHRONIC PYELONEPHRITIS



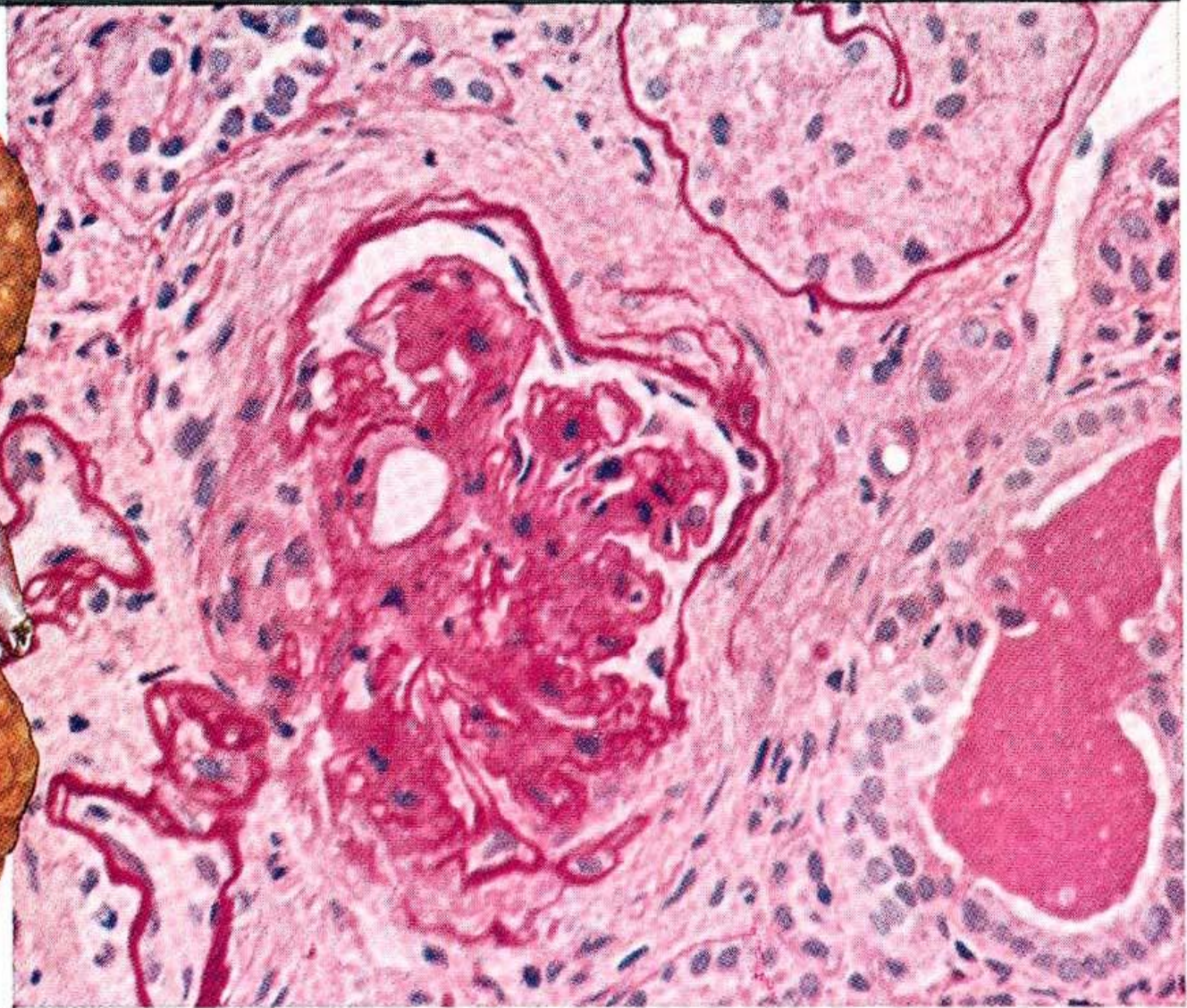
LOW-POWER SECTION SHOWING FOCAL NATURE OF INVOLVEMENT: AREAS OF LYMPHOCYtic INFILTRATION ALTERNATING WITH AREAS OF RELATIVELY NORMAL PARENCHYMA

LATE STAGE OF CHRONIC GLOMERULONEPHRITIS

F. Netter
M.D.
© CIBA



CONTRACTED, PALE,
COARSELY GRANULAR KIDNEY

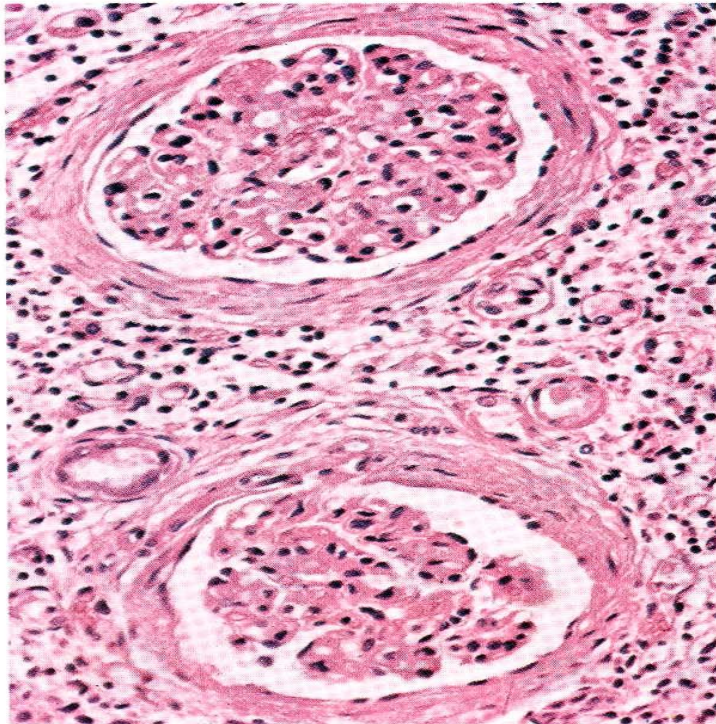
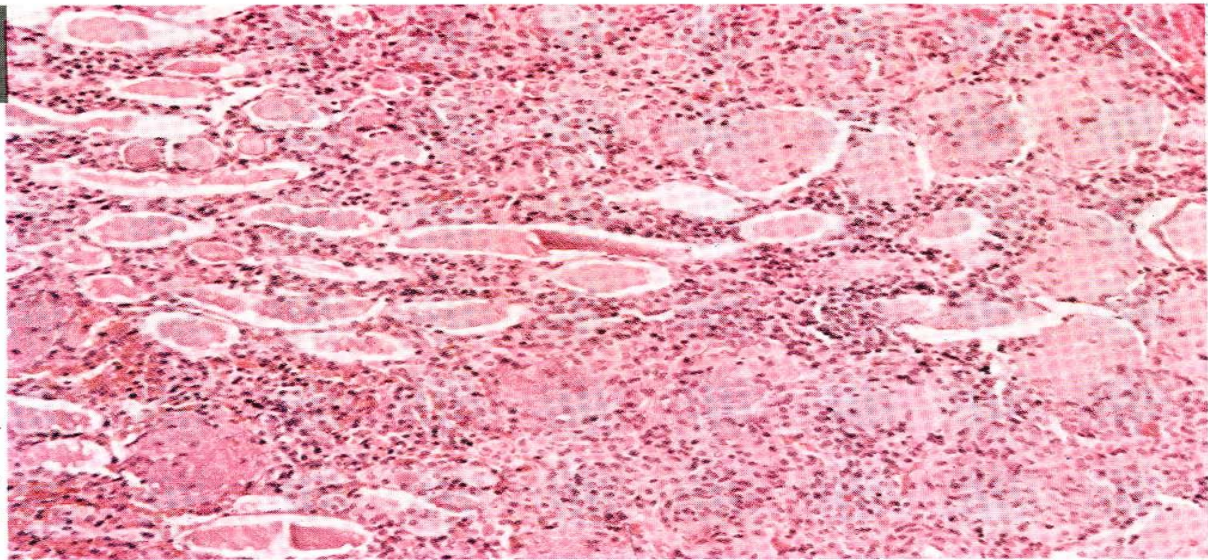


GLOMERULI IN VARIOUS STAGES OF OBSOLESCENCE; DEPOSITION OF PAS-STAINING MATERIAL, HYALINIZATION, FIBROUS CRESCENT FORMATION, TUBULAR ATROPHY, INTERSTITIAL FIBROSIS

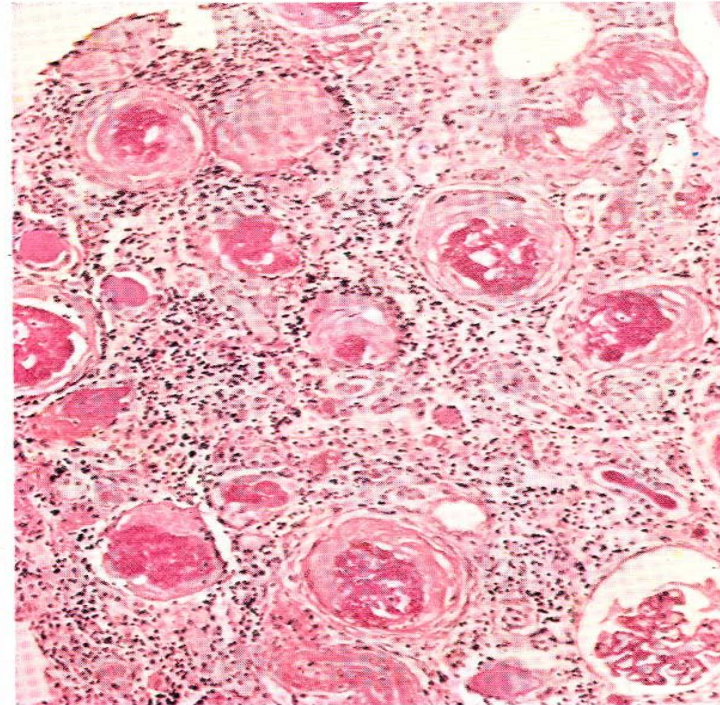
**CHRONIC
PYELONEPHRITIS:
PATHOLOGY
(CONTINUED)**

© CIBA

COLLOID CASTS
WITHIN LUMINA
OF TUBULES
WITH FLATTENED,
ATROPHIC
EPITHELIUM, IM-
PARTING THYROID-
LIKE APPEARANCE:
INTERSTITIAL
LYMPHOCYTTIC AND
PLASMA CELL
INFILTRATION WITH
GLOMERULAR
HYALINIZATION



PERICAPSULAR GLOMERULAR FIBROSIS WITH TUBULAR ATROPHY AND INTERSTITIAL INFLAMMATION



INTRACAPSULAR HYALINIZING GLOMERULAR FIBROSIS: PAS-POSITIVE MATERIAL IN BOWMAN'S SPACE WITH COMPRESSED CAPILLARY TUFT

Clinical presentation:

1. History of recurrent episodes of urinary tract infection.
2. Hypertension.
3. Insidious onset of renal failure.
4. Sometimes patient may be asymptomatic with non-nephrotic proteinuria.

Investigations:

1. Urine culture: should be repeated 3-4 times. A positive culture is obtained only in 30% of cases.

Ultrasound : may show asymmetry in kidney size and distortion of calyx.

3. GFR: may be reduced, increase in 24-hour proteinuria and manifestations of distal tubular dysfunction (e.g. renal tubular acidosis, inability to concentrate urine).

4. Renal biopsy: is **not** indicated.

Treatment:

- 1.** Antimicrobial therapy: according to culture and sensitivity testing and a long suppressive regimen is indicated.
- 2.** Surgical treatment for anatomic abnormality or stone disease.
- 3.** Treatment of hypertension.
- 4.** If the patient presents with chronic renal failure, treatment will be provided as described in lecture on chronic renal failure.

A pink rose with water droplets on a light background. The rose is the central focus, with its petals and green leaves visible. The background is a soft, light color with a pattern of water droplets of various sizes, creating a fresh and clean aesthetic.

THANK YOU

M. Sobh MD, FACP