

Pelvic Organ Prolapse (POP)

Osama M Warda MD

**Prof. of obstetrics &
gynecology**

Mansoura University



Professor of Obs/Gyn



The information included in this presentation are not the only source for this topic and you should explore other valuable references in order to satisfy the ILOs of this topic.



DEFINITION

- Pelvic organ prolapse (POP) can be defined as descent of the pelvic organ(s) ; bladder, rectum, vagina, uterus; below their normal anatomical position due to distortion of their **dynamic** and **integrated** support.



Symptoms from POP

- POP can cause symptoms directly due to the prolapsed organ or indirectly due to organ dysfunction secondary to displacement from the anatomical position.
- **Direct POP symptoms include:**
 - (1) a sensation of vaginal bulge,
 - (2) heaviness or a visible protrusion at or beyond the introitus.
 - (3) lower abdominal or back pain, or a dragging discomfort relieved by lying or sitting.



Symptoms from POP

- **Indirect symptoms:** will depend on which other organs are involved in the prolapse.

They include:

- (1) difficulty in urination or defecation (obstructive defecation)
- (2) sensations of incomplete emptying of bladder or rectum.
- (3) Patients may have to support or reduce the prolapse with their fingers to be able to void or evacuate stool completely (i.e. digitation)
- (4) Urinary or fecal incontinence may also be present
- (5) Sexual dysfunction due to introital laxity
- (6) Bleeding from abrasion of the prolapsed part

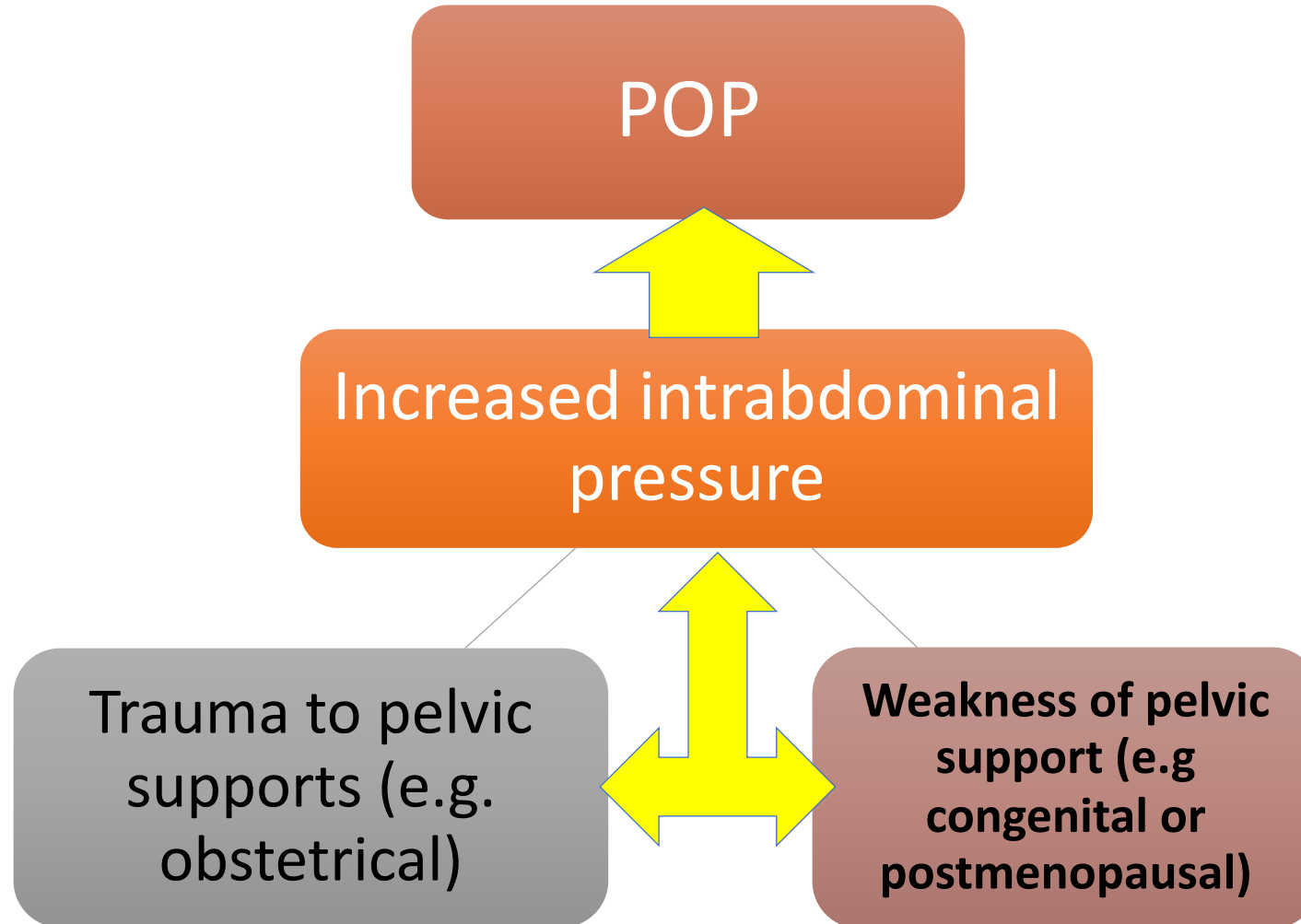


ETIOLOGY OF POP

- **Risk factors** predisposing to prolapse either congenital weakness of the mesenchyme or due to obstetric trauma.
- *Obstetric trauma* causes:
 - 1- Pudendal nerves damaged , with increased nerve conduction times
 - 2- Thinning or avulsion of the puborectalis muscle from its insertion on the pubic ramus on one or both sides.

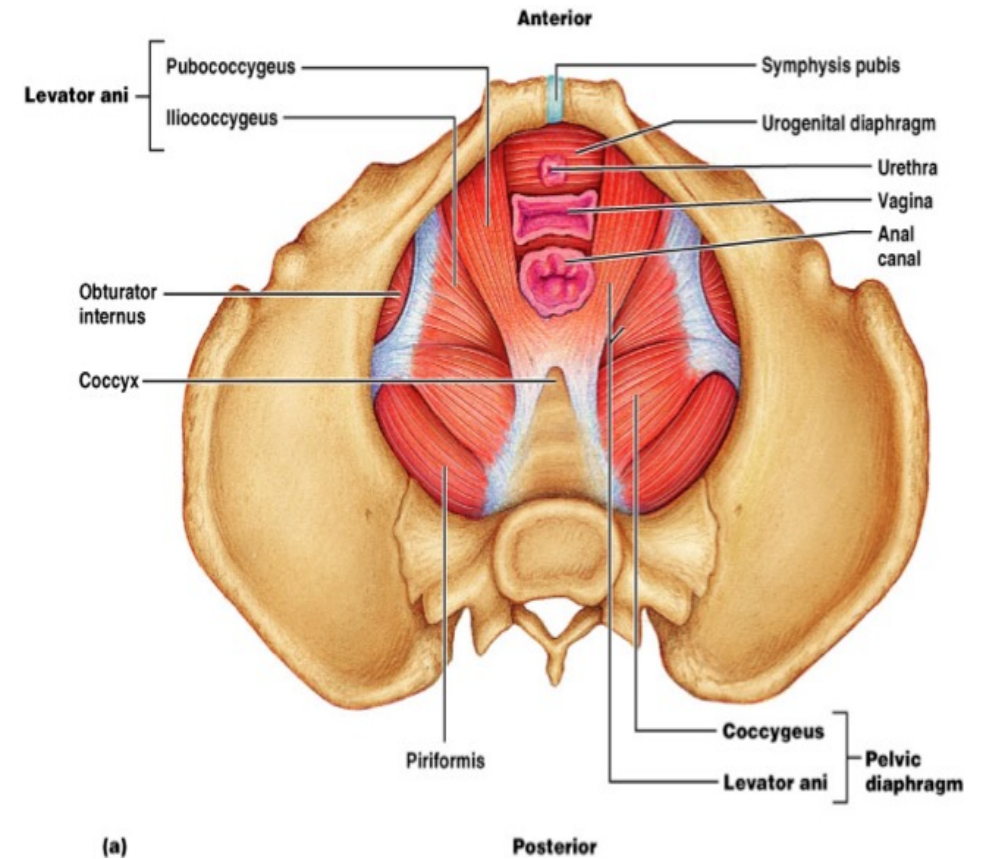


ETIOLOGY OF POP



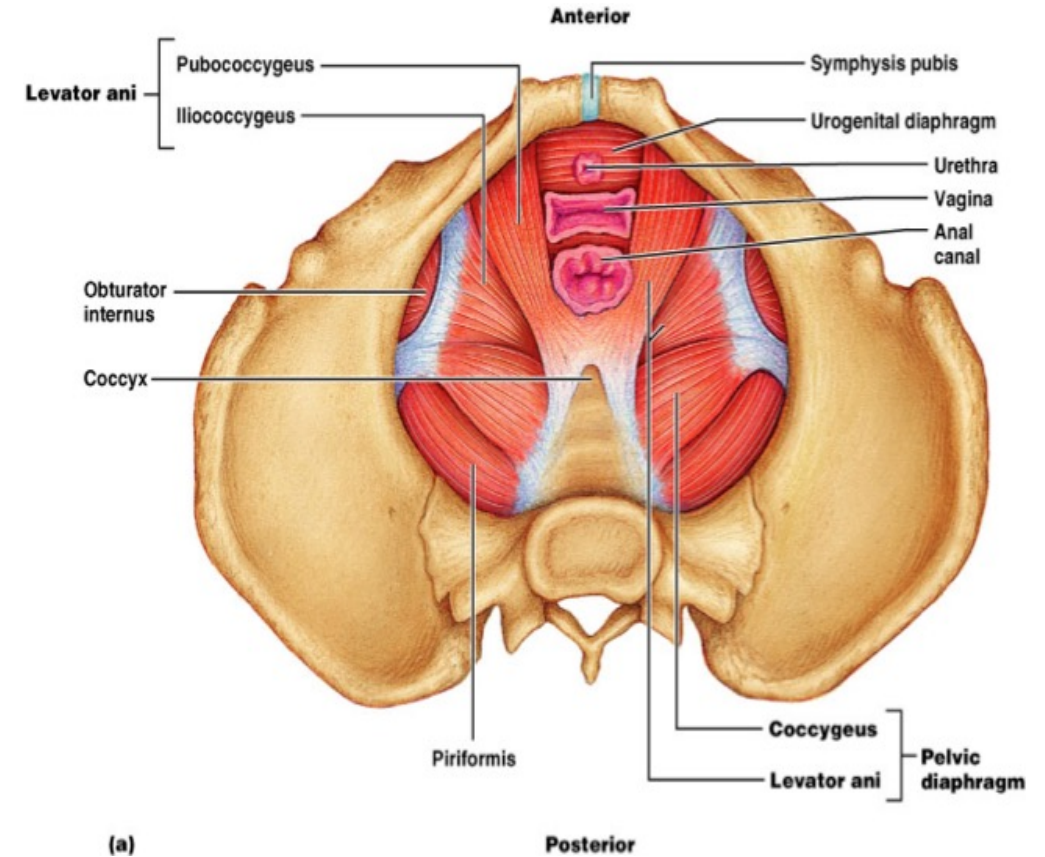
Relevant Anatomy

- Utero-vaginal prolapse is caused by *failure of the interaction between the levator ani muscles and the ligaments and fascia that support the pelvic organs.*
- The levator ani muscles are *puborectalis, pubococcygeus and iliococcygeus.*
- They are attached on each side of the pelvic side wall from the pubic ramus anteriorly (pubococcygeus), over the obturator internus fascia to the ischial spine to form a bowl-shaped muscle filling the pelvic outlet and supporting the pelvic organs

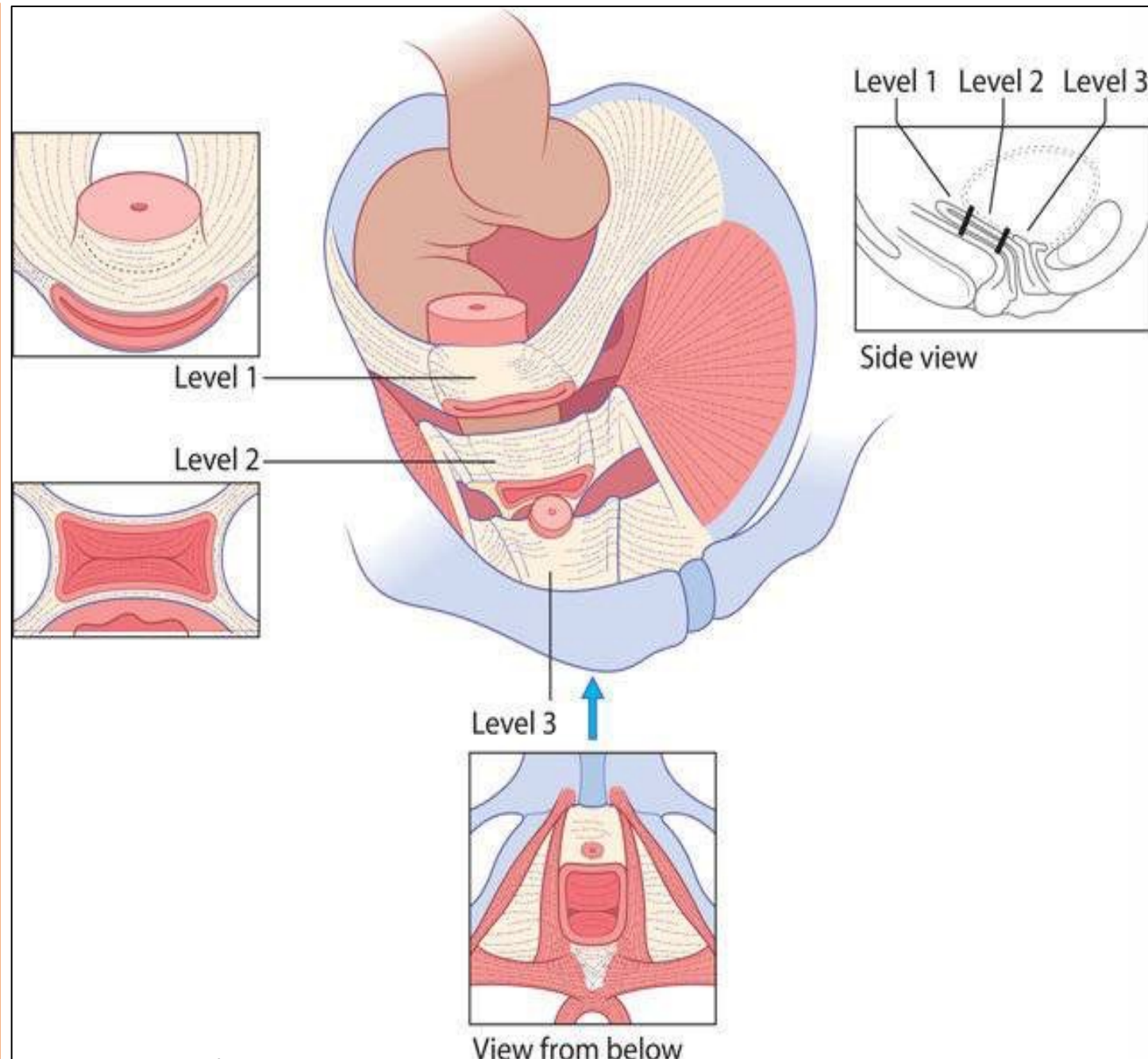


Relevant Anatomy

- There is a gap between the fibres of the puborectalis on each side to allow passage of *the urethra, vagina and rectum, called the urogenital hiatus.*
- The levator muscles support the pelvic organs and prevent excessive loading of the ligaments and fascia.

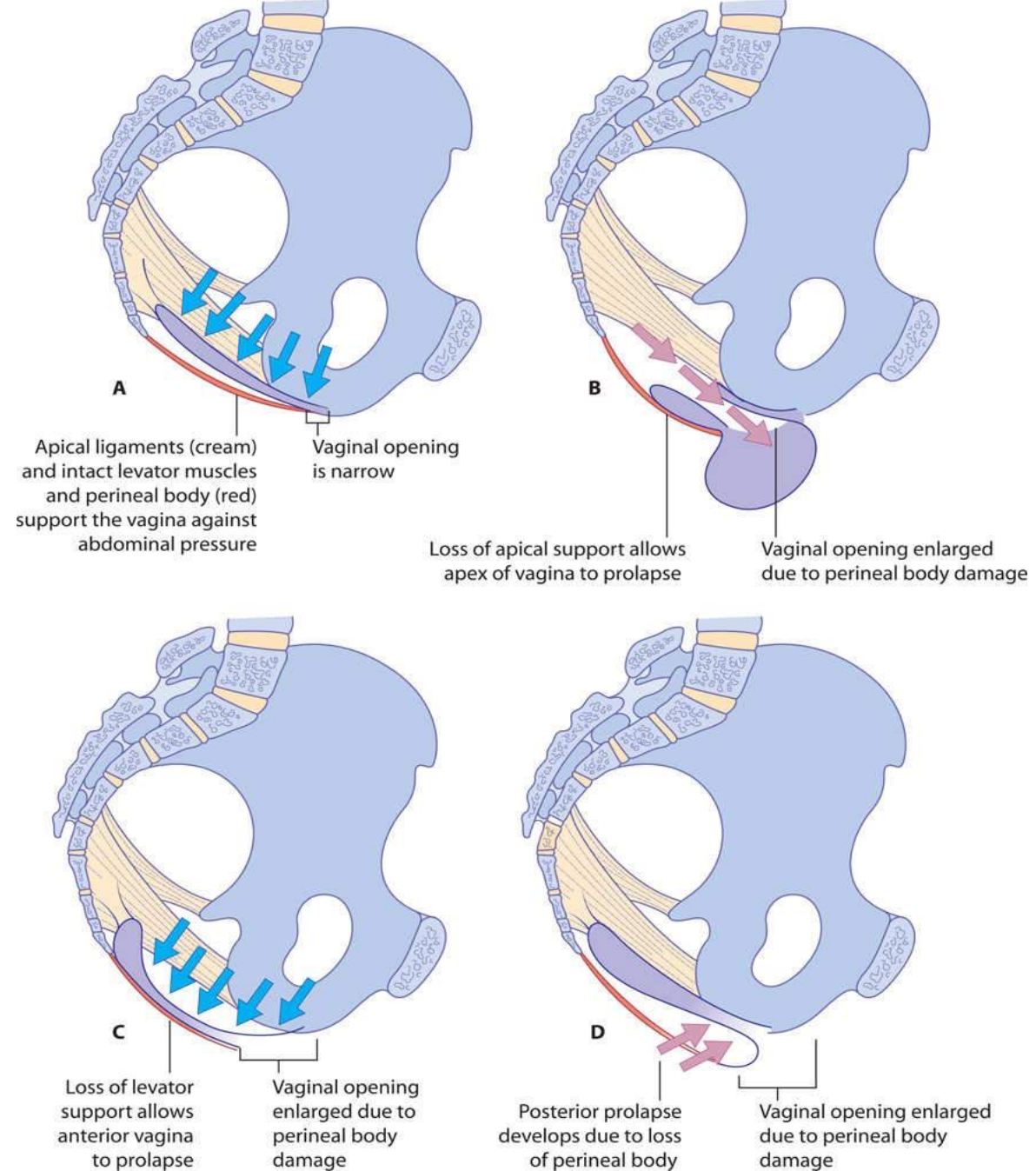


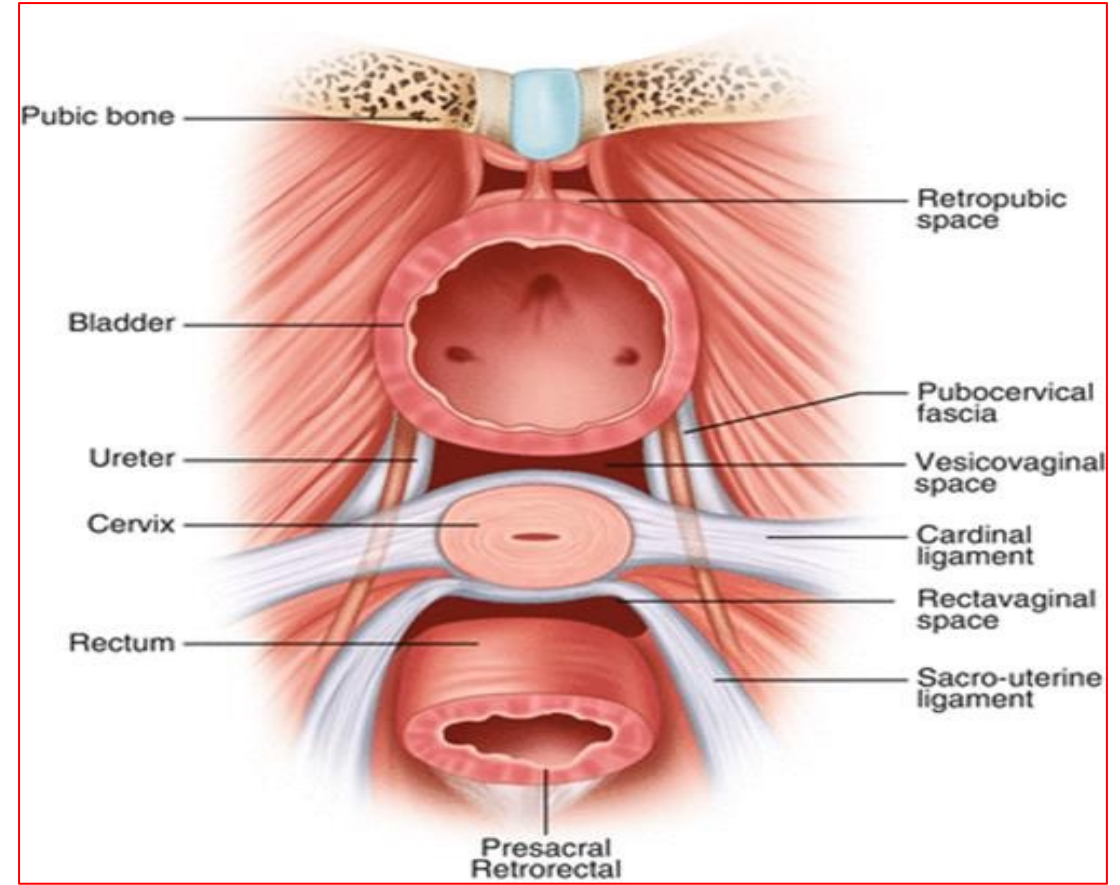
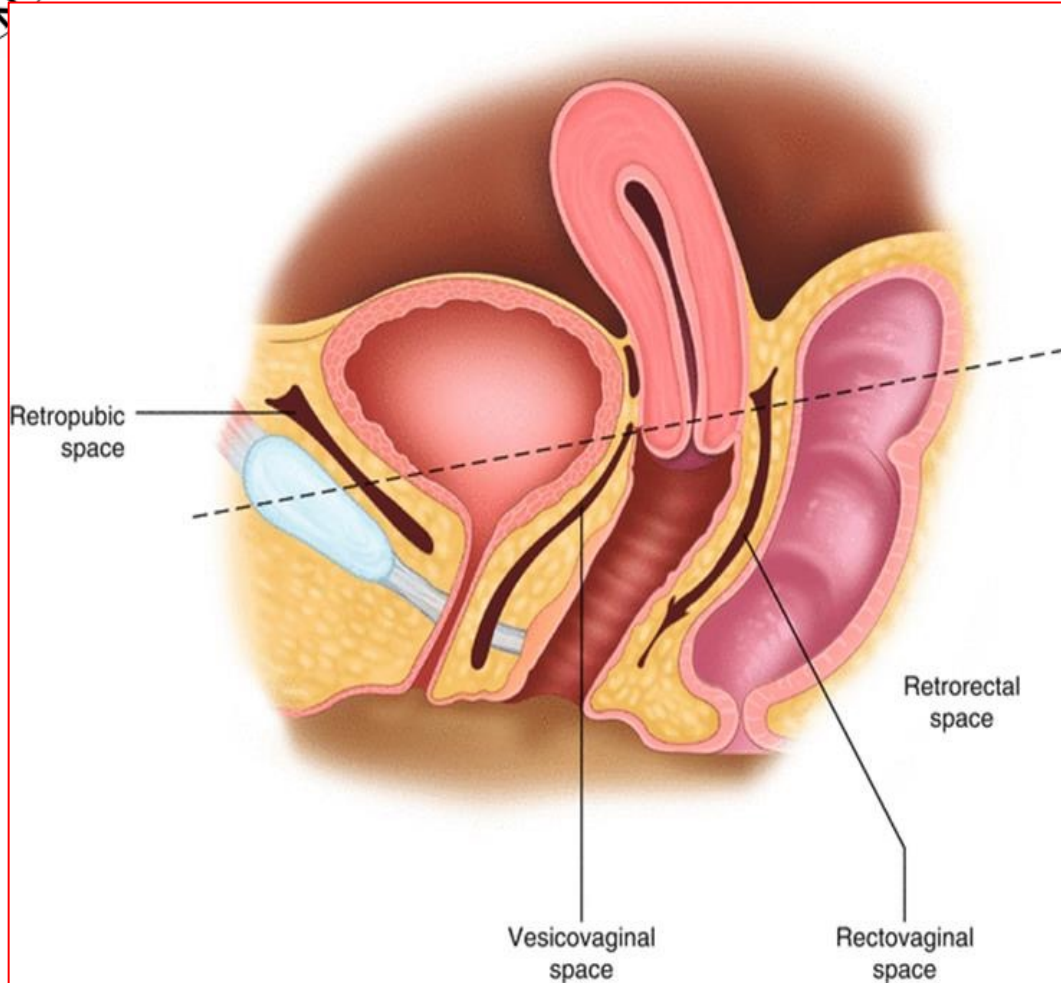
Fascial supports of the pelvic organs. Level 1 support is provided by the *uterosacral* ligaments, suspending the uterus and attached *vaginal vault*. Level 2 (midvagina) support is provided by the **fascia** lying between the **vagina and the bladder or rectum** that fuses laterally and runs to attach on the pelvic side wall. Level 3 support is provided by the **perineal body**, which has the posterior vaginal fascia fused to its upper surface.



Development of prolapse. The pelvic floor and ligaments work together to provide support against increases in abdominal pressure (A).

Prolapse is almost invariably associated with perineal body damage causing an enlarged vaginal opening. Prolapse can then occur if the apical (level 1) support is lost (B), or if the pelvic floor muscles are ineffective (C) or directly as a result of perineal body deficiency (D). Often, a combination of factors is at work.







Relevant Anatomy

Key Learning Points:

- **The levator ani muscles** (puborectalis, pubococcygeus and iliococcygeus) support the pelvic organs and relieve excessive pressure from the ligaments and fascia.
- **The uterosacral ligaments** provide essential apical support (*level 1 support*).
- **Vaginal fascia** supports the vagina (*level 2 support*).
- **The perineal body** is very important in supporting the lower vagina (*level 3 support*).
- All the structures provide a **dynamic** and **integrated** support to the pelvic organs.



De Lancey's three levels of vaginal support

- **Apical suspension (LEVEL 1)**

- ✓ Upper para-colpium suspends apex to pelvic walls and sacrum

- Damage results in prolapse of vaginal apex (vault prolapse)

- **Mid-vaginal lateral attachment (LEVEL 2)**

- ✓ Vaginal attachment to arcus tendineus fascia and levator ani muscle fascia

- ✓ Pubo-cervical and recto-vaginal fasciae support bladder and anterior rectum

- Avulsion results in cystocele or rectocele

- **Distal perineal fusion (LEVEL 3)**

- ✓ Fusion of vaginal fascia to perineal membrane, perineal body and levators

- Damage results in deficient perineal body or urethrocele



Clinical assessment of prolapse

THE HISTORY:

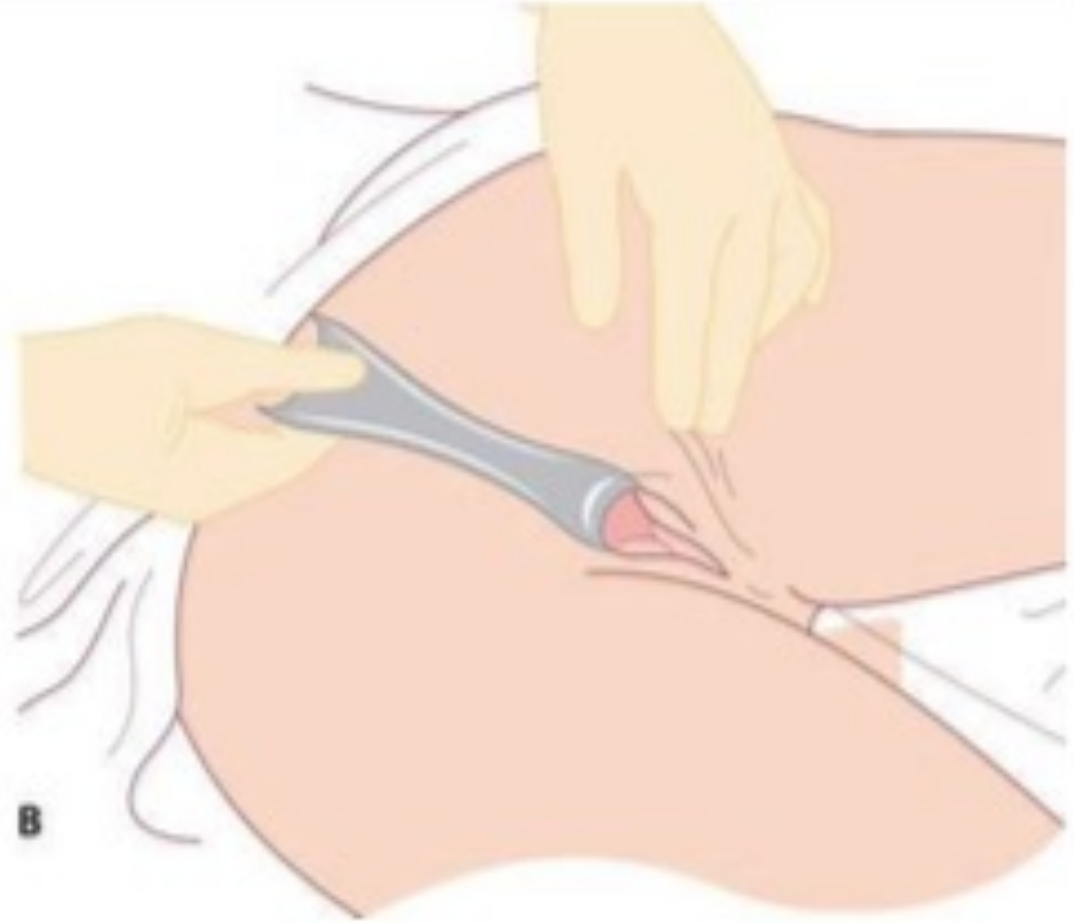- You should elicit the presenting symptom(s) and severity, and include questions to ascertain if the patient has any coexisting urinary, fecal or sexual symptoms .
- One should be sensitive to the emotional aspect of the problem, but specific questions should be asked about sexual discomfort and difficulty achieving orgasm.



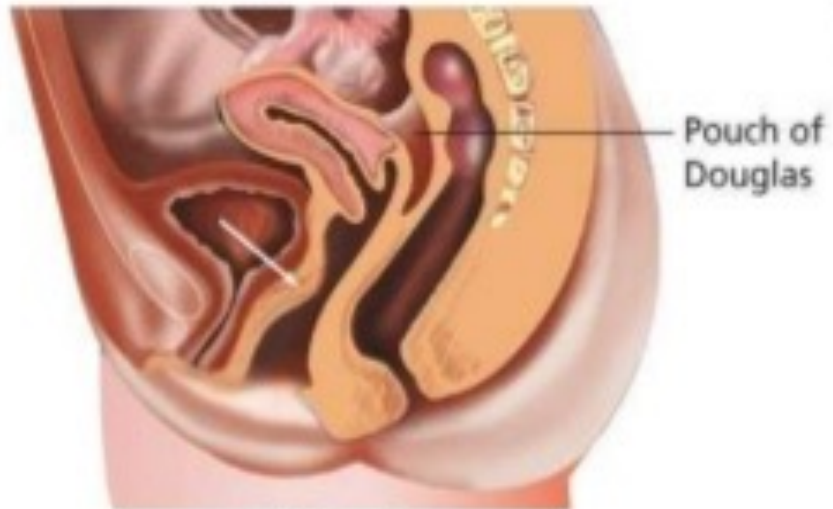
Clinical assessment of prolapse

CLINICAL EXAM

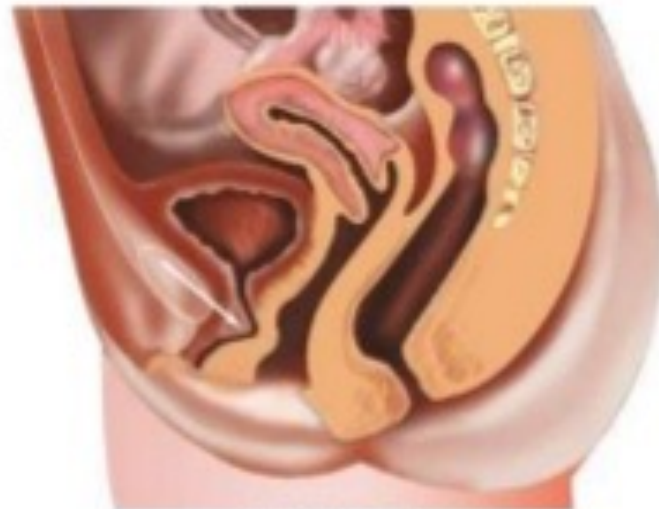- should ideally be done in the **lithotomy** position with a Sims speculum . This allows retraction of the anterior and posterior vaginal wall in turn, to allow full assessment of the degree of prolapse and to assess how much descent of the cervix and uterus is present.
- Prolapse is classically described in three stages of descent, and note should be made of whether it occurs at patient straining or at rest and whether traction has been applied:



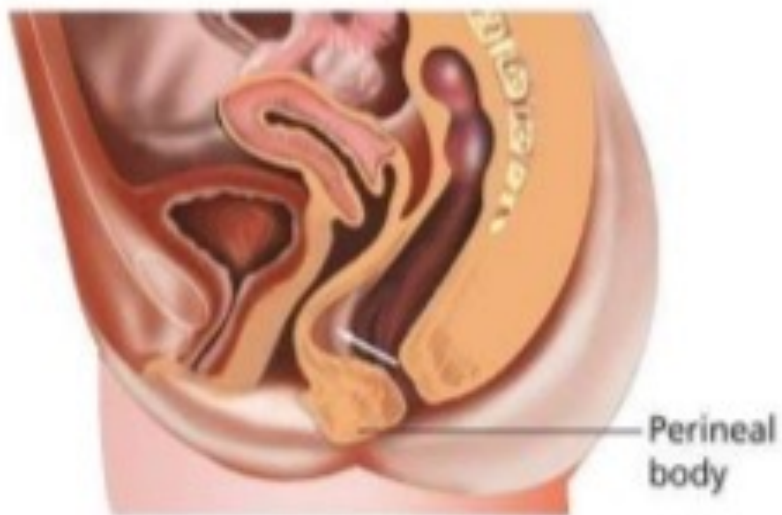A: Sim's speculum; **B:** Sim's speculum inserted with the patient in the left lateral position. The speculum is being used to hold back the posterior vaginal walls to allow inspection of the anterior wall and vault. The speculum can be rotated 180° or withdrawn slowly to visualize the posterior wall.



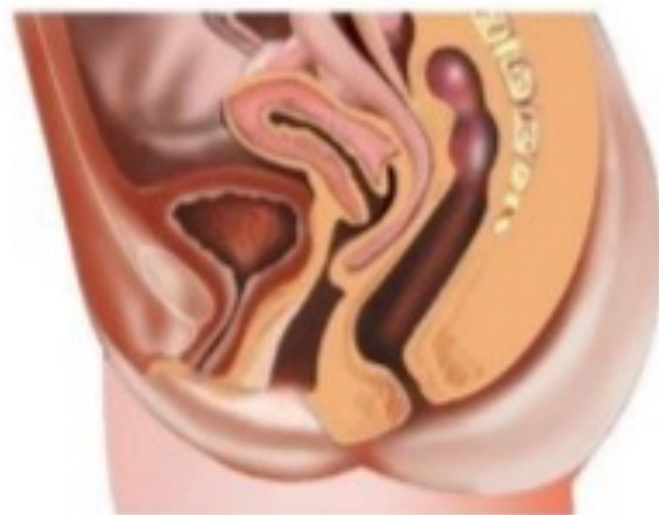Cystocele



Urethrocele

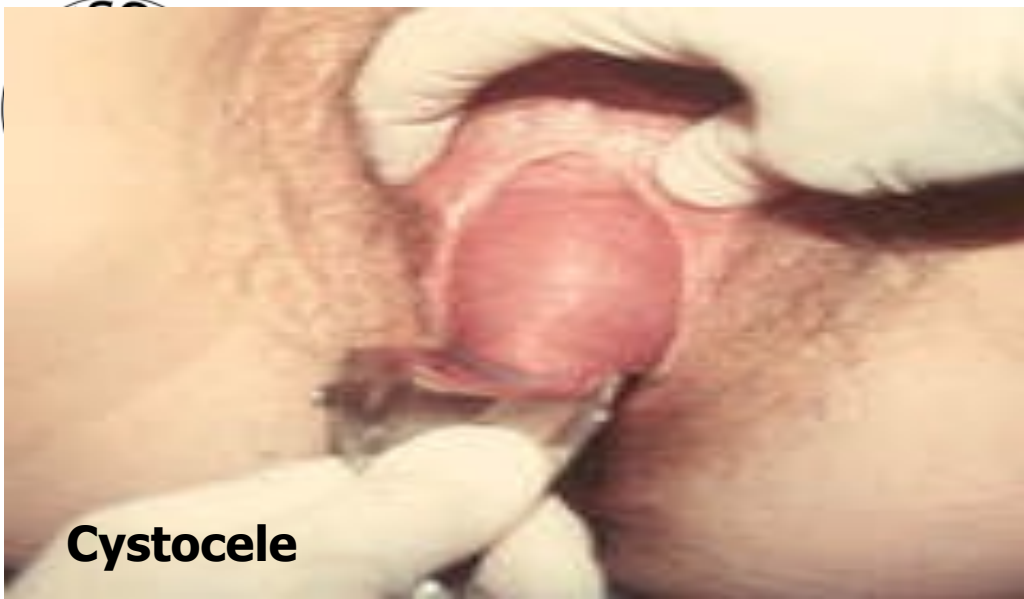

Rectocele

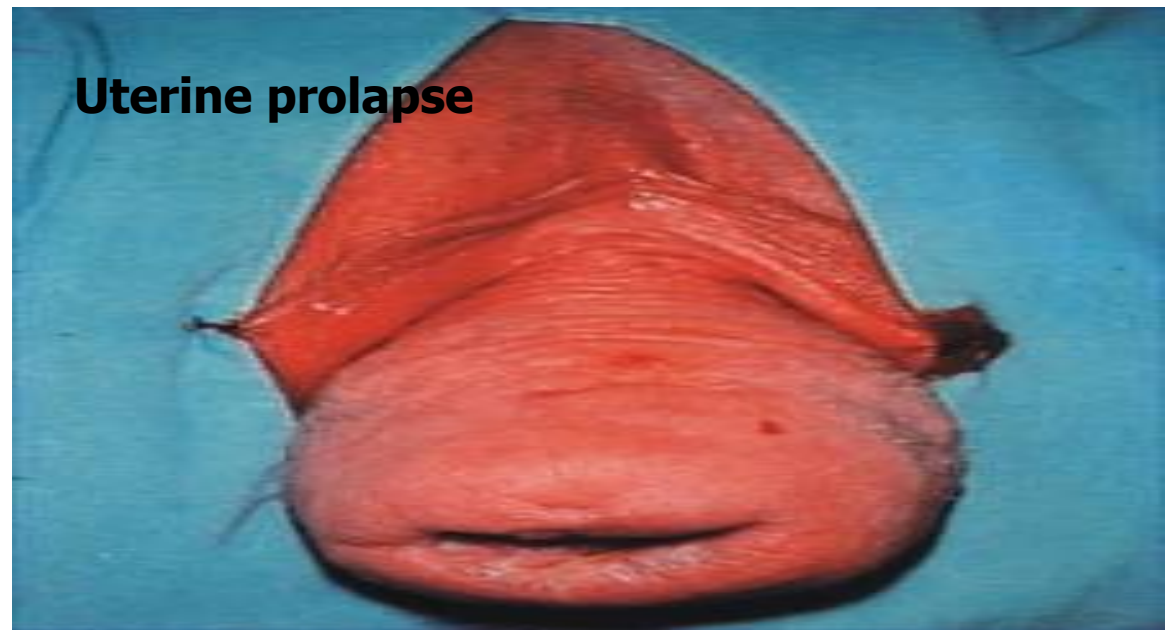


Enterocele

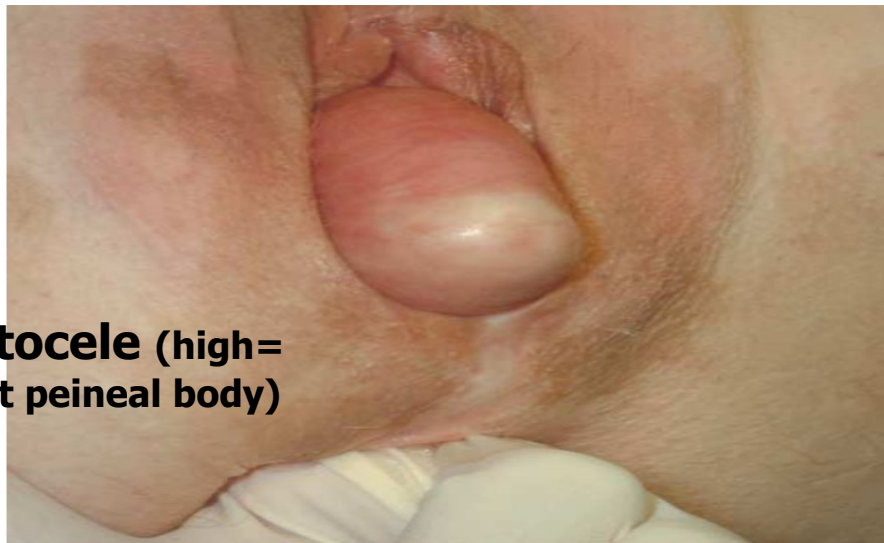
Padubidri & Daltary: Shaw's Textbook of Gynaecology, 15e
Copyright © 2011 by Elsevier India. All rights reserved.



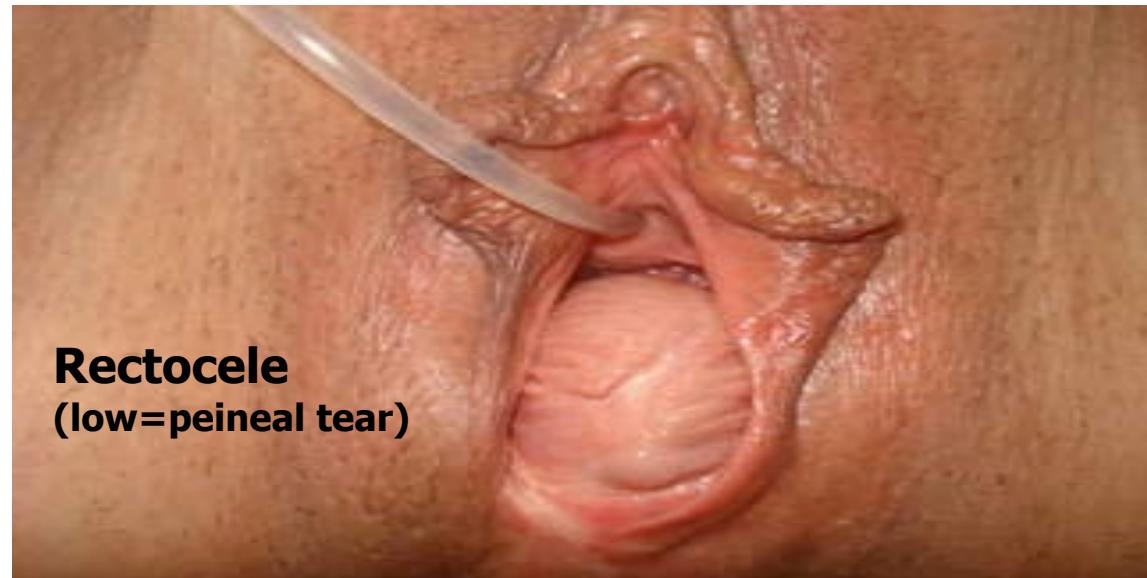Cystocele



Uterine prolapse

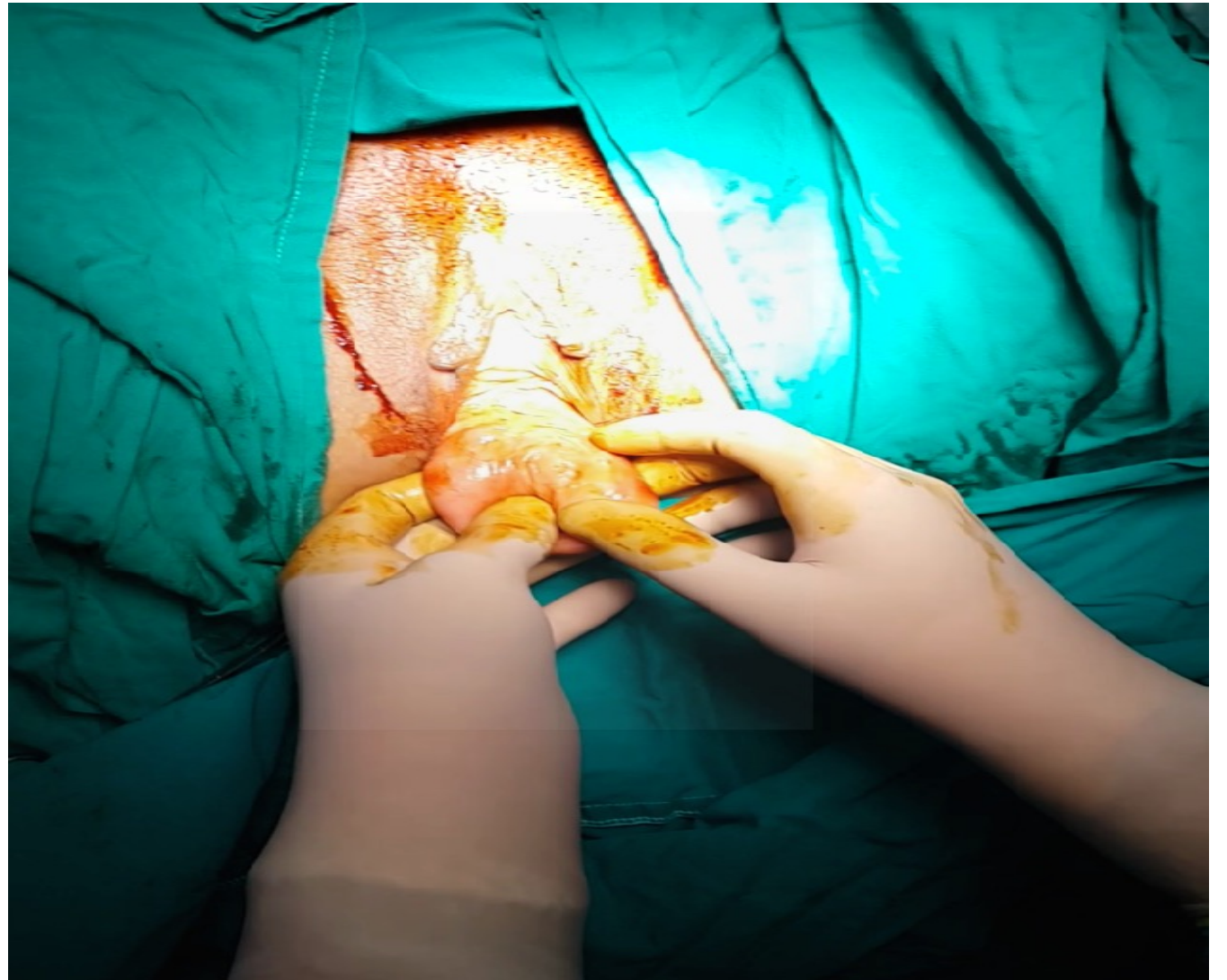
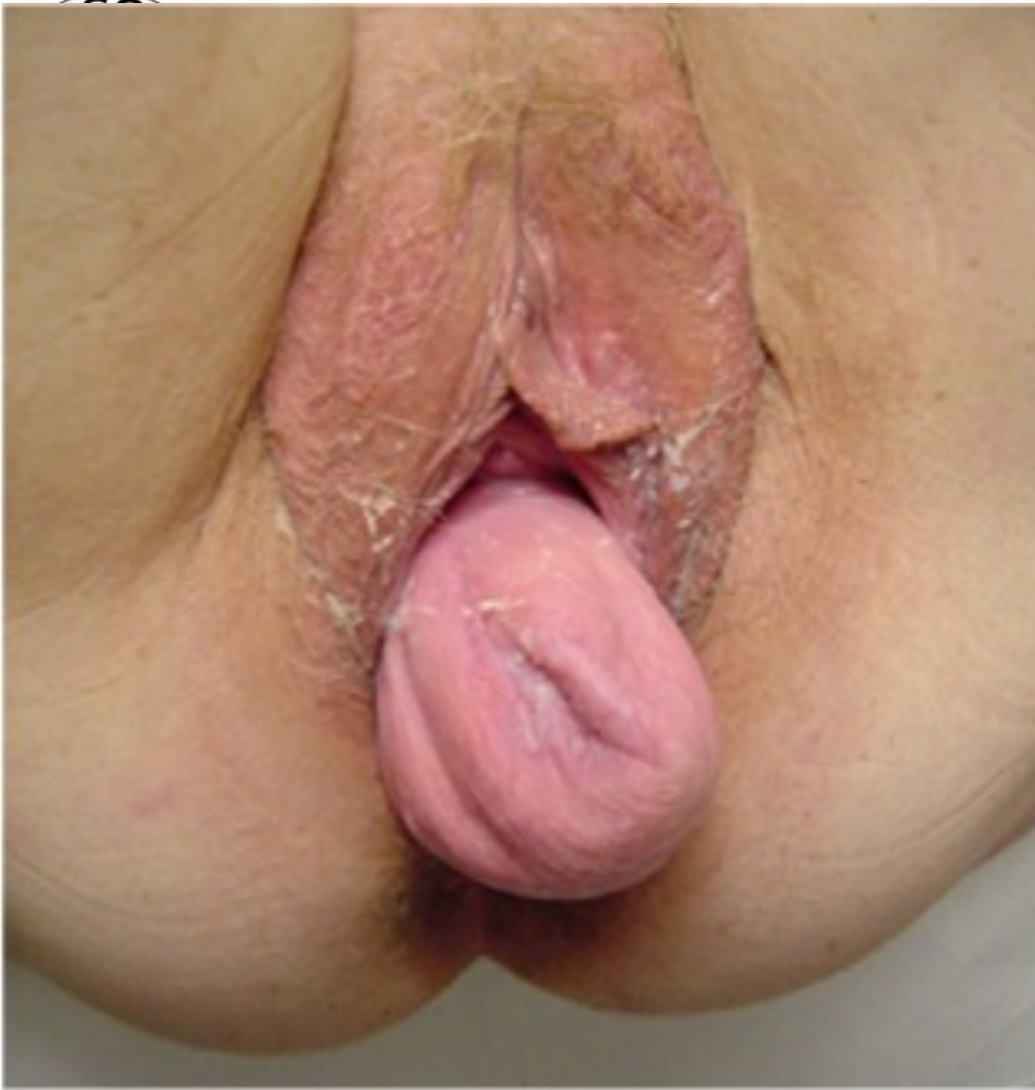

**Rectocele (high=
intact peineal body)**



**Rectocele
(low=peineal tear)**

FIGURE 14. Mid-vaginal posterior prolapse that protrudes through the introitus despite a normally supported perineal body. (© DeLancey 2004)



Post-hysterectomy vaginal vault prolapse



Clinical assessment of prolapse

- In view of the complex relationship between prolapse and *bladder* or *bowel* functions, if women have additional indirect symptoms, then it is prudent to arrange *urodynamic assessment or functional tests of the lower bowel*, which may include
 - 1- endoanal ultrasound** to check for anal sphincter defects,
 - 2- rectal manometry**,
 - 3-flexible sigmoidoscopy** ,
 - 4- defaecating proctogram.**
- Ideally, such patients should be reviewed with the completed investigations in a MDT meeting including a *gynecologist*, colorectal *surgeon*, *continence nurse* and *physiotherapist*.



Stages of POP

Many systems have been used in staging of POP, however, the basis are

- **Stage I:** where the prolapse does not reach the hymen.
- **Stage II:** where the prolapse reaches the hymen.
- **Stage III :** when the prolapse is mostly or wholly outside the hymen.
- When the uterus prolapses wholly outside this is termed **procidentia**.



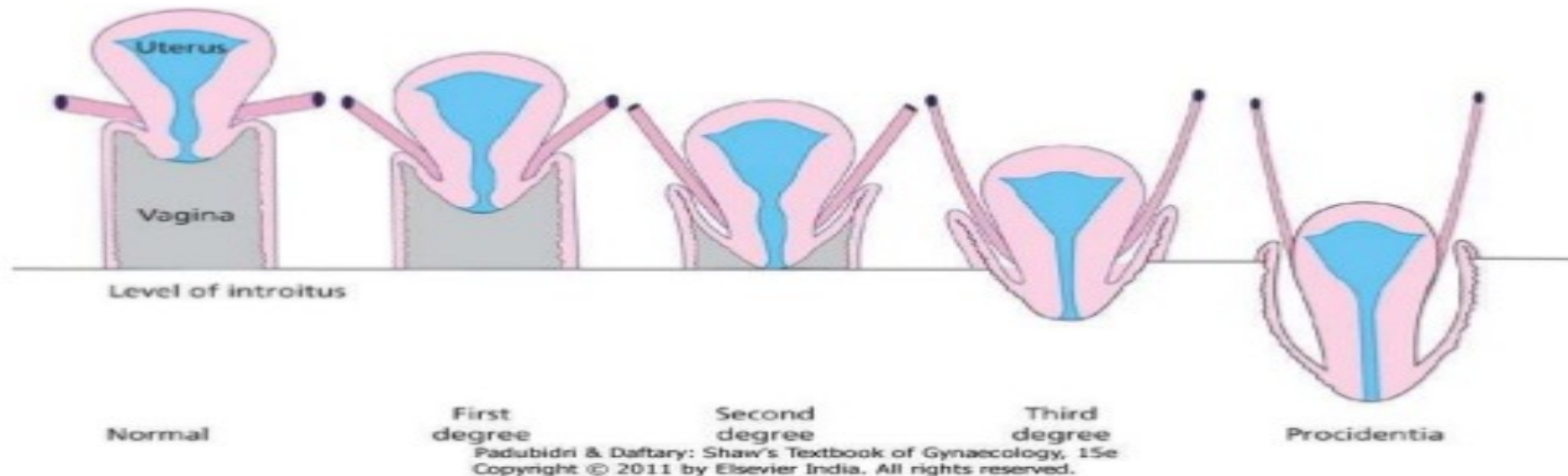
Stages of POP

- Vaginal prolapse is formally staged using different methods, but the most important assessment is whether the vaginal prolapse reaches to, or beyond, the hymen. Finally, it is important to assess whether the perineal body is intact or has become attenuated, resulting in an enlarged vaginal opening.

Stages of POP

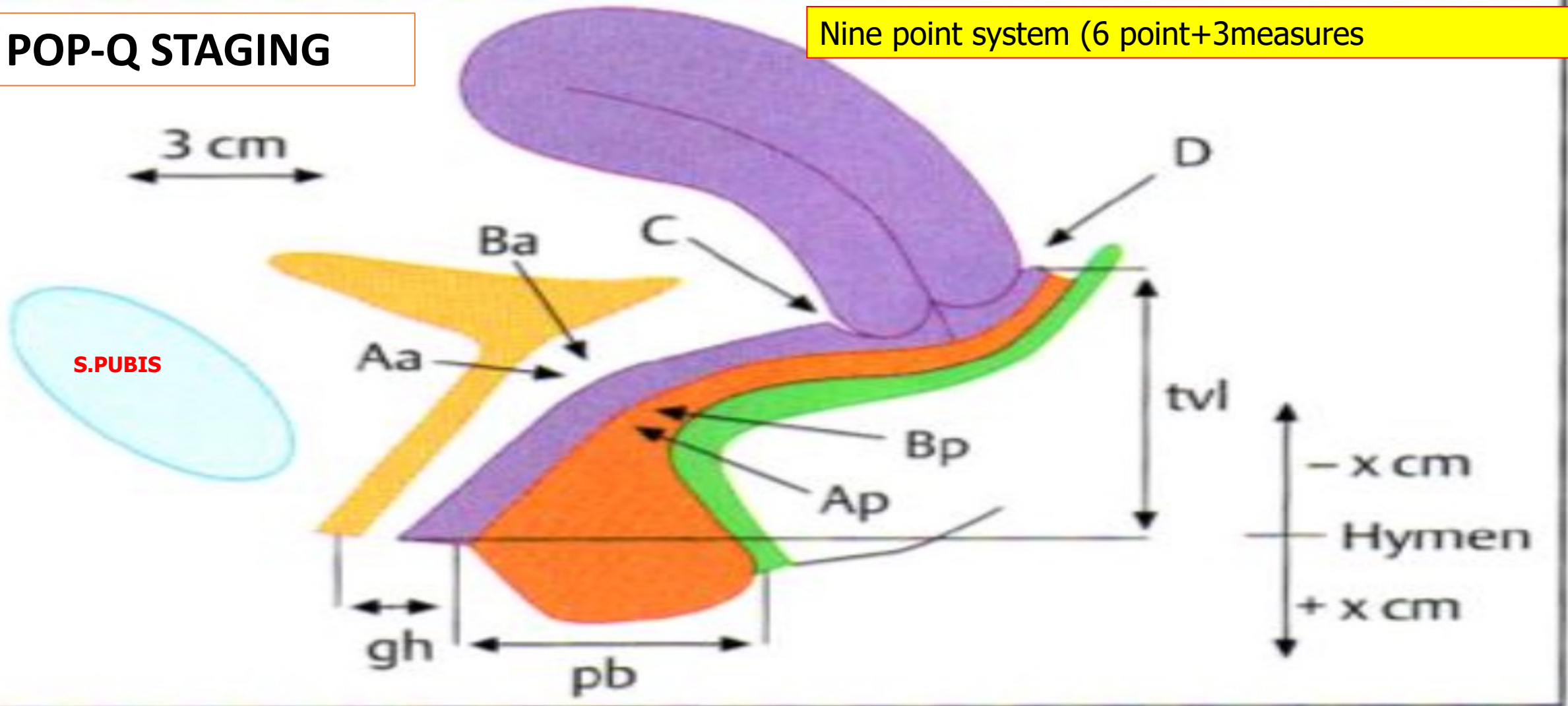
- **Old systems:** not objective, not validated for describing the spectrum of pelvic support in individual patients and in study populations:

a). Uterine prolapse:



POP-Q STAGING

Nine point system (6 point+3measures)



Points and landmarks for POP-Q system examination. **Aa**, point A anterior, **Ap**, point A posterior, **Ba**, point B anterior; **Bp**, point B posterior; **C**, cervix or vaginal cuff; **D**, posterior fornix (if cervix is present); **gh**, genital hiatus; **pb**, perineal body; **tv**, total vaginal length.



POP-Q Stages of POP

- Once the measurements are taken, the patients are assigned to the corresponding stage:
- **Stage 0** = no prolapse.
- **stage I** = most distal portion of prolapse is > 1cm above level of hymen
- **Stage II**= the most distal part of prolapse is <1cm **proximal** to or **distal** to the plane of hymen
- **Stage III**=the most distal portion of the prolapse protrudes more than 1 cm **below** the hymen but **no farther than 2 cm** less than the total vaginal length (for example, not all of the vagina has prolapsed).
- **Stage IV**=complete vaginal eversion is essential.

Treatment for prolapse

Conservative treatment: includes

- 1- **pelvic floor muscle exercises** and
- 2- **the use of supportive vaginal pessaries.**



- For women with urinary or bowel symptoms as well, conservative treatment for these symptoms can be commenced at the same time as for the prolapse.



Treatment for prolapse

Conservative treatment: Pelvic floor exercises

- A course of supervised *pelvic floor exercises* will reduce the symptoms of prolapse and for women who are keen to **avoid** surgical treatment, this can be an *effective first step*, although there is *less evidence that pelvic floor exercise will reduce the anatomical extent of the prolapse and it is unlikely to be helpful for women whose prolapse is beyond the vaginal introitus.*

Treatment for prolapse

Conservative treatment: Pessary treatment:



- A ***vaginal support pessary*** is inserted to reduce the prolapse, which leads to resolution of many of the symptoms.
- Pessary use can be very effective at relieving symptoms and has the advantage of **avoiding surgery** and the associated risks, which can be extremely useful in the *medically unfit and elderly*.
- A range of shapes of pessary is available (see picture)



Conservative treatment: Pessary treatment: (cont.)

- *Ring pessaries* are usually tried first, but an **intact** perineal body is necessary for these to be retained.
- *Shelf pessaries*, **Gelhorn** pessaries and others are useful for women with **deficient** perineal bodies.
- It is usual practice to replace *a pessary every 6 months* and to examine the patient for signs of vaginal ulceration, although this frequency is **traditional** and not based on any evidence.



Conservative treatment: Pessary treatment: (cont.)

- Complications are uncommon and usually minor (*bleeding, discharge*), although rarely the pessary can become *incarcerated*, requiring general anesthesia to remove, and rare cases of *rectovaginal or vesicovaginal fistula formation* have been reported.
- *Sexual intercourse* remains theoretically possible with a well-placed **ring pessary**, but **not** with the others, *so would not generally be suitable for women who are sexually active.*
- Motivated patients can be taught to insert and remove their own pessaries if they do wish to remain sexually active.



SURGERY FOR POP

- Surgical treatment for prolapse is **common**, and can be offered if conservative treatments have failed or if the patient chooses surgery from the outset.
- There are a wide range of **specific procedures** .
- The procedure chosen depends on *(1).which compartment is affected,*
(2).whether the woman wishes to retain her uterus and
(3).whether the vaginal or abdominal route of surgery is chosen.
- The essential principles of prolapse surgery apply for all procedures.



SURGERY FOR POP

- Prolapse surgery is performed *through the vagina* to restore the ligamentous tissue supports to the apex, anterior and posterior vagina (anterior repair, posterior repair) and repair of the perineal body.
- The vaginal route can also be used for *pos-thysectomy vault prolapse*, *attaching the vaginal vault to the right sacrospinous ligament with non-absorbable or slowly absorbable sutures*, but here an abdominal approach to perform a ***sacrocolpopexy*** is an option that will provide excellent, durable long-term cure.



SURGERY FOR POP

- In the last 3–5 years, there has been an increasing number of women wishing to **avoid hysterectomy** during prolapse surgery, so both ***sacrospinous fixation*** ***and sacrocolpopexy*** can be performed by attaching a mesh or sutures to the cervix rather than the vaginal vault.
- Vaginal repair using mesh **improves** the *anatomical outcome and reduces the risk of recurrent prolapse*. **No difference** in symptom relief between standard repair and mesh repair. Mesh repair carries the risk of later **erosion** and **need for removal**, which is challenging surgery.

Procedure	Key point	Short description	Complications
Anterior vaginal repair (ant.colporrhaphy)	<ul style="list-style-type: none"> -For anterior vaginal prolapse. -NOT for stress incontinence 	Suture to reinforce fascia between vagina & bladder	<ul style="list-style-type: none"> - Bladder injury - High recurrence
Posterior vaginal repair Post. colporrhaphy	<ul style="list-style-type: none"> -For posterior vaginal prolapse - Can improve obstructed defecation - Risk of recurrence is low 	Suture to reinforce fascia between vagina & rectum	<ul style="list-style-type: none"> - Risk of rectal injury - Postoperative dyspareunia
Vaginal repair with polypropylene mesh	<ul style="list-style-type: none"> - Usually reserved for recurrent prolapse - Surgical repair reinforced with mesh - Very low recurrence rates - Excellent anatomical results 	Mesh can be inlay (not fixed), or fixed to the pelvic ligaments to mimic the native uterosacral ligaments and fascial attachments	<ul style="list-style-type: none"> -mesh erosion through the vagina (5%) - Mesh erosion through bladder or rectum (<5%) - Dypareunia - Chronic pelvic pain - Excision of mesh is difficult



Principles of POP surgery

- **Remove/reduce the vaginal bulge.**
- **Restore the ligament/tissue supports to the apex, anterior and posterior vagina.**
- **Replace associated organs in their correct positions.**
- **Retain sufficient vaginal length and width to allow intercourse.**
- **Restore the perineal body.**
- **Correct or prevent urinary incontinence.**
- **Correct or prevent fecal incontinence.**
- **Correct obstructed defecation.**



KEY LEARNING POINTS

- **Uterovaginal prolapse causes troublesome symptoms but is not life threatening.**
- **A course of pelvic floor exercises can reduce symptoms and may reduce prolapse progression in women with mild/moderate prolapse.**
- **Vaginal pessaries are a useful conservative treatment but do not suit all women.**
- **Surgery for prolapse is effective, but has a recurrence rate of about 5%.**
- **It is not essential to perform hysterectomy for prolapse.**
- **Mesh repairs for prolapse give a better anatomical cure, but there is no convincing evidence that symptom relief is different from standard surgery.**
- **Mesh complications are common and can be extremely difficult to manage.**



Thank you