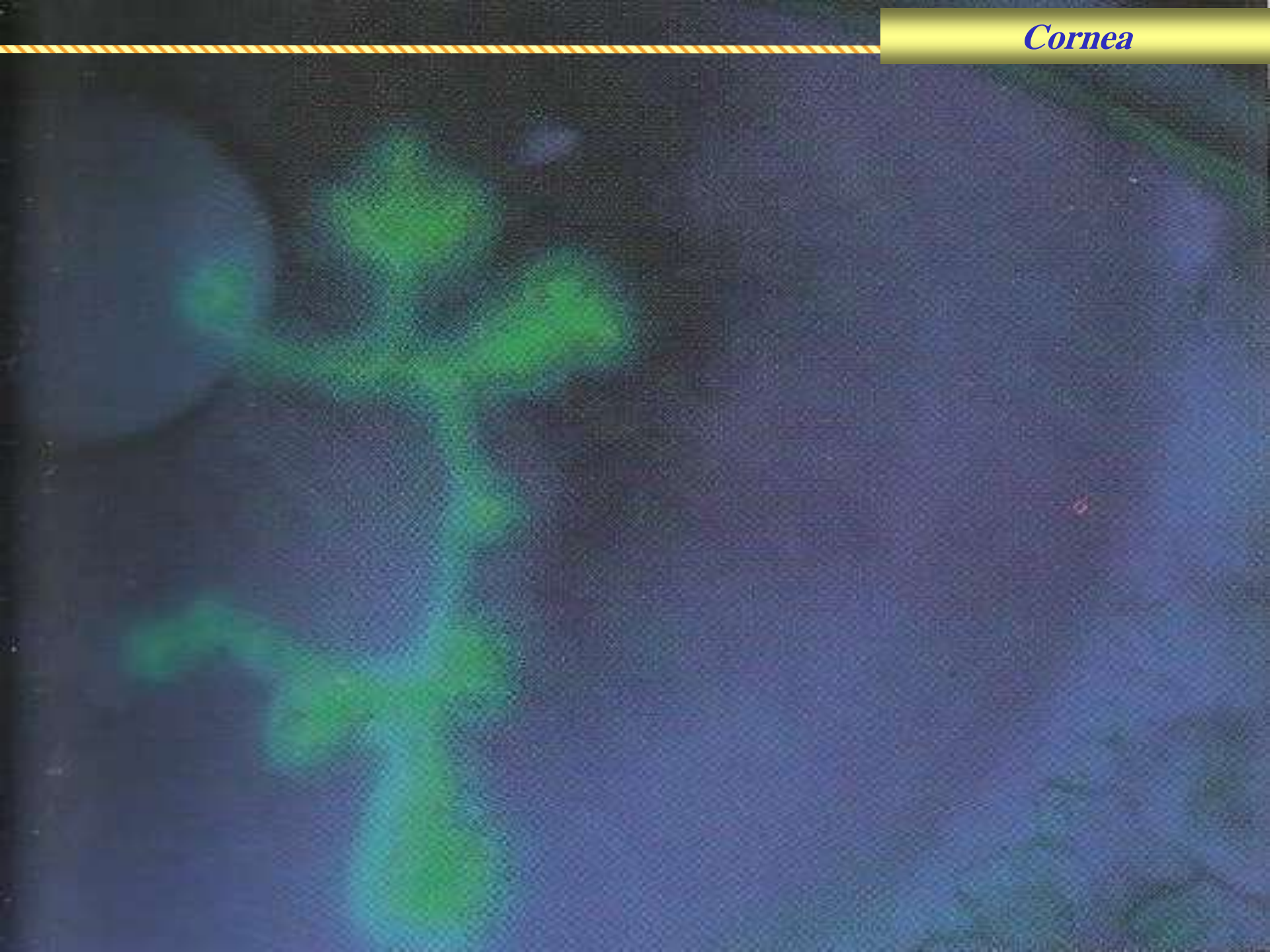

بِسْمِ اللَّهِ الرَّحْمَنِ الرَّحِيمِ

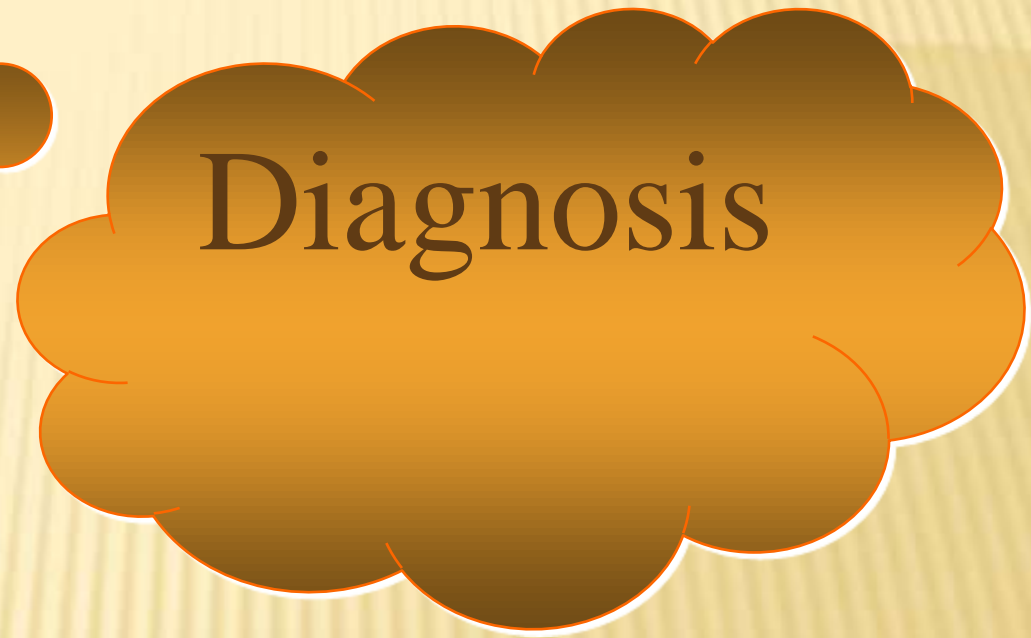
Cornea


A 5 year-old boy with history of atopy was recently started on prednisone for a flare up of his eczema. His mother brought him in because his right eye is red and painful. He had similar episode during last summer's vacation on the beach with his family. The right eye is injected. Staining of the cornea with fluorescein shows a dendritic pattern.



Clinical features

- Immunosuppressive state
- Recurrent
- Typical dendrite that stains with fluorescein
- ?? Corneal sensation





Differential
diagnosis



Treatment

THANK YOU