

Basic

Ophthalmology

Seventh Edition

By
Staff Members of Ophthalmology
Mansoura University



بِسْمِ اللَّهِ الرَّحْمَنِ الرَّحِيمِ

قُلْ هُوَ الْغَيْبُ أَنْشَأَكُمْ وَجَعَلَ لَكُمُ السَّمْعَ

وَالْأَبْصَارَ وَالْأَفْئِدَةَ قَلِيلًا مَّا تَشْكُرُونَ

سورة الملك (الآية 23)



Preface

“Basic Ophthalmology” book - written by the staff members of Ophthalmology Department, Faculty of Medicine, Mansoura university - has been made to provide the basic knowledge of ophthalmology in a systematic, concisely written, well illustrated and comprehensive manner to be easily memorized by the undergraduate students.

We hope that this book provides our students with adequate basic ophthalmology knowledge to make accurate clinical observations, reach a diagnosis and to be aware of the relevant differential diagnosis.

Also we hope that this book will be beneficial to general practitioner helping them to diagnose and manage some medical diseases with ocular manifestations.

Finally we would like to thank all the staff members of the ophthalmology department for their great effort, time and participation in the production of this book.

Staff Members of the Ophthalmology

Editor in chief

Prof. Hany Abd El-Rahman

Contents

Chapter 1	Ocular Examination	1
Chapter 2	Eyelids	14
Chapter 3	Lacrimal System	46
Chapter 4	Orbit	56
Chapter 5	Conjunctiva	72
Chapter 6	Cornea	108
Chapter 7	Sclera	125
Chapter 8	Uveal Tract	130
Chapter 9	Lens	149
Chapter 10	Glaucoma	172
Chapter 11	Retina	200
Chapter 12	Vitreous	234
Chapter 13	Errors of Refraction	237
Chapter 14	Strabismus	251
Chapter 15	Neuro-Ophthalmology	278
Chapter 16	Ocular Trauma	300
Chapter 17	Medical Ophthalmology	319
Chapter 18	Laser in Ophthalmology	325
Chapter 19	Differential Diagnosis	329
Chapter 20	Problem Solving.....	340

Tables

Table 1	Differential diagnosis of inflammatory proptosis	64
Table 2	Types of exophthalmos	68
Table 3	Difference between conjunctival and ciliary injection	79
Table 4	Differential diagnosis of phlycten	100
Table 5	Differential diagnosis of pterygium	106
Table 6	Corneal vascularization	121
Table 7	Difference between senile nuclear sclerosis and nuclear cataract	157
Table 8	Types of Senile cortical cataract	159
Table 9	Purkinje sanson Images	164
Table 10	Differential diagnosis of posterior cortical cataract	167
Table 11	Differential diagnosis of acute red painful eye	189
Table 12	Difference between open and closed angle glaucoma	191
Table 13	Differential diagnosis of retinopathies	220
Table 14	Differential diagnosis of retinal detachment	231
Table 15	Types of myopia	240
Table 16	Types of squint	276
Table 17	Difference between papilledema & papillitis	285
Table 18	Types of optic atrophy	288
Table 19	Differential diagnosis of gradual painless progressive diminution of vision	290
Table 20	Hutchinson's pupil	295
Table 21	Differential diagnosis of subconjunctival hemorrhage	302

Chapter 1

Ocular Examination

Ophthalmic History Taking

• *Personal history:*

1. Age.

2. Occupation:

(a) Farmers & outdoor workers are more liable to pterygium because they are exposed to ultraviolet rays of the sun and dust.

(b) Industrial workers are more susceptible for mechanical, chemical & physical trauma.

3. Personal habits: Alcoholics and tobacco smokers are liable to toxic amblyopia (retrobulbar neuritis).

• *Past history:*

1. General systemic disease:

Diabetes, hypertension, renal disease and arthritis.

2. Medical history:

Previous medication e.g. corticosteroids, antiglaucoma drugs and antidepressants.

3. Ocular history:

Trauma, previous eye operations, recurrent attacks of pain and redness with drop of vision may be suggestive of acute glaucoma or irido-cyclitis.

• *Family history:*

1. High myopia (short sight).
2. Glaucoma (high ocular tension).
3. Retinal degeneration (e.g. retinitis pigmentosa).
4. Positive consanguinity in hereditary diseases.

Complaint (Ocular Symptoms):

A. Visual Disturbances:

1. Diminution of vision:

- *Onset:* May be sudden (e.g. central retinal artery occlusion) or gradual (e.g. senile cataract).
- *Duration:* The complaint of the patient may be recent or long-standing.
- \pm *Pain:* Diminution of vision may be painless as in cataract or associated with pain as in acute glaucoma and iridocyclitis.
- *Course:* May be stationary or progressive.

2. Blurred vision: As in errors of refraction.

3. Nyctalopia (Night blindness):

Decreased vision could be more at night as in senile cortical cataract and retinitis pigmentosa.

4. Hemeralopia (Day blindness):

Decreased vision during the day as in nuclear cataract.

5. Field defects:

The patient may complain that he cannot see in certain areas of the visual field, which may be:

- Unocular as in retinal detachment, glaucoma and optic nerve lesions.
- Binocular as in any lesion at or above the level of the optic chiasma.

6. Visual illusions (Opsias = Dysmegalopsia):

- Metamorphopsia: Objects appear distorted as, in macular lesions and retinal detachment.
- Macropsia: Objects appear bigger in size.
- Micropsia: Objects appear smaller in size.

7. Visual Hallucinations:

A- Simple Hallucinations (Photopsia):

Patient sees flashes of light. It can be due to retinal detachment, retinitis, or choroiditis. It is due to mechanical stimulation of the rods and cones or due to inflammation.

B- Color Hallucinations (Chromatopsia): colored vision

- a. Cyanopsia: Blue vision.
- b. Erythroptopsia: Red vision.
- c. Chloropsia: Green vision.
- d. Xanthopsia: Yellow vision as in digitalis toxicity.

C- Formed hallucinations:

Temporal lobe tumors.

8. Scintillations:

Colored zigzag lines seen in the aura of migraine.

9. Diplopia (double vision):

It can be monocular as in subluxation of the lens and iridodialysis or, binocular as in paralytic squint.

10. Musca Volitantes (floaters):

The patient may complain of seeing moving or flying insect-like floaters in front of the eye. They move with the eye movement and appear more on a white surface. Musca may be due to:

- Vitreous floaters as in high myopes.
- Vitreous hemorrhage following trauma or in proliferative diabetic retinopathy.

11. Photophobia:

Inability to open the eye facing light of ordinary intensity. This is a common complaint that may be due to:

- Keratitis, iritis and iridocyclitis.
- Corneal ulcers and conjunctival foreign bodies.

B. Pain:

The character of pain differs from one disease to the other. (See chapter 19)

C. Discharge:

Depending on the type and severity of conjunctivitis, the discharge may be:

1. **Watery (serous):** As in viral conjunctivitis.
2. **Mucous:** As in allergy.
3. **Mucopurulent:** As in mucopurulent conjunctivitis.
4. **Purulent:** As in purulent conjunctivitis.
5. **Sanguinous (Blood tinged):** As in diphtheritic conjunctivitis.

D. Watering of the Eye:

1. Epiphora:

Watering of the eye due to obstruction of the lacrimal passages:

- a) Naso-lacrimal obstruction.
- b) Dacryocystitis.
- c) Trauma in the region of the medial canthus.

2. Lacrimation:

Increased production of tears due to:

- a) Keratitis.
- b) Iridocyclitis.
- c) Conjunctival foreign body.
- d) Corneal foreign body.
- e) Viral conjunctivitis.

f) Allergic conjunctivitis.

g) Emotions.

E. Disfiguring:

1. Redness:

- *Conjunctival injection:*
 1. Conjunctivitis.
 2. Episcleritis.
 3. Scleritis.
- *Ciliary injection:*
 1. Corneal ulcer or foreign body.
 2. Keratitis.
 3. Iridocyclitis.
 4. Endophthalmitis & panophthalmitis.
- *Conjunctival & ciliary injection:*

Acute or subacute attacks of angle closure glaucoma.

2. Leucocoria:

White colored pupil, as in cases of cataract. In children, retinoblastoma must be excluded.

3. Protrusion of the globe:

a. Proptosis:

- Painful or painless, with or without diminution of vision.
- Onset: Sudden or gradual.
- May be related to trauma.
- Presence of symptoms and signs of inflammation.

b. Exophthalmos:

History and symptoms of thyrotoxicosis.

c. Pseudoproptosis:

- Large globe: Staphyloma, buphthalmos, high axial myopia.

- Shallow orbit.
- Lid abnormalities: Retraction, coloboma.

4. Squint:

Disturbance of the parallel relation between the axes of the two eyes.

Common Childhood Complaints

Preverbal children cannot complain of pain or defective vision. It is the mother who first notices any defect in appearance or defective vision. Examination of an infant or a child often requires general anesthesia.

The most common complaints are:

A. Squint:

- Onset: May be shortly after birth or few years later.
- History of trauma or fever often precedes the squint.
- Were defective vision glasses prescribed?
- Was occlusion therapy received?
- History of previous surgical operations to correct the squint.

B. Leukocoria (white pupil):

Immediately after birth or later in childhood

- May be unilateral or bilateral.
- The commonest cause is cataract and most serious is retinoblastoma.

C. Epiphora:

Due to incomplete canalization of the lacrimal passages, it is commonly unilateral and causes unilateral conjunctivitis and discharge.

D. Proptosis:

Congenital causes or acquired.

E. Large cornea, pain, photophobia and Lacrimation:

Often due to congenital glaucoma (Buphthalmos).

Ophthalmic Examination

1. The eyelids should be examined for:

- Position.
- Lid margin thickness and position.
- Signs of inflammation (redness, pain, tenderness, and edema).
- The presence of misdirected lashes.

2. Regurgitation test: Pressure on the skin below the medial canthal ligament while observing the punctum shows no regurge in the normal person but pus or mucopurulent secretion is seen in cases of naso-lacrimal duct obstruction associated with chronic dacryocystitis.

3. Palpebral conjunctiva: Should be examined by everting the eyelid, signs of trachoma as PTDs, scar should be noted.

4. Bulbar conjunctiva: Should be examined in all directions of gaze. Any abnormality in color should be noted. The normal conjunctiva is transparent through which the white sclera could be seen. Fine pigmentation may be noticed.

5. Cornea: Should be examined for its diameter (normally 12mm), transparency (normally transparent). Any opacity should be noted (nebula, leucoma, leucoma adherent).

6. Anterior chamber: Should be examined for depth, clarity or cloudiness of the aqueous, the presence of blood (hyphema), the presence of pus (hypopyon). Abnormalities in depth should be noted. The anterior chamber may be shallow as in hypermetropia and angle closure glaucoma or deep as in aphakia.

7. Iris: Should be examined for color and pattern. Any difference between the color in the right and left eyes should be noted.

8. Pupils: Should be inspected for size, shape, and reaction to direct and consensual (in the opposite eye) light reflex as well as the near reflex.

The pupil is normally rounded, regular and reactive to light (RRR). The normal size of the pupil is about 3-5 mm in room light. Pupils smaller than 3 mm occur in old age and people using miotics, pupils larger than 7mm are abnormally wide.

9. Lens: Is normally clear. Any opacity in the lens should be noted. The lens normally lies just behind the iris; any abnormality in position should be noted (as in subluxation or dislocation of the lens).

10. Ocular tension: Should be measured.

11. Ophthalmoscopy: To examine the fundus is necessary in some patients.

12. Visual acuity of the patient should be tested using the visual acuity chart.

13. Color vision: Should be tested using the Ishihara (pseudo-isochromatic plates).

14. Ocular motility: Motility should be free in all directions of gaze. The examiner should note any limitation of movement or diplopia in any direction.

Special investigations are done when indicated as:

1. Fluorescein angiography (FA).
2. Ultrasonography (US).
3. Perimetry (visual field mapping).
4. Optical Coherence Tomography (OCT).
5. Electro-physiological tests :
 - Electro Retino-graphy (ERG).
 - Electro Oculo-graphy (EOG).
 - Visually Evoked Potential (VEP).

Visual Acuity Test

Visual acuity chart such as Landolt's chart (also called broken ring chart or Snellen chart) is used.

- The patient sits at a distance of 6 meters from the chart.
- The lowest line that can be read is recorded. For example, if vision is 6/24, it means that the patient can see at 6 meters what a normal person can see at 24 meters.
- If the patient cannot see the largest ring (6/60), the patient gets closer to the chart (one meter at a time) until he sees the largest ring (5/60, 4/60, 3/60, 2/60, 1/60).
- If the patient cannot see the largest ring at a distance of one meter, ask him to count fingers.
- **Counting fingers (CF):** In a well illuminated room, ask the patient to count fingers. Write down the distance at which he could count fingers, {75 cm, 50 cm, 25 cm}.

If the patient cannot count fingers, proceed to testing for hand movement.

- **Hand movement (HM):** Move your hand in front of the patient, if the patient can see the hand moving, vision is (HM).
- **Perception of light (PL):** If the patient cannot see HM do the perception of light test, if he can see light, write (PL). If he cannot see light, vision is (No PL).

Projection of light test:

If the patient can see HM, shine a light in his eye in all directions (up, down, nasal, temporal), one eye at a time with the other eye covered. If he can see the light in all directions, the projection is good, if he cannot see the

light in all directions, the projection is bad. This is a rough method to test the functions of the periphery of the retina in presence of opaque media.

Fundus Examination

Fundus examination is done after dilating the pupil with a mydriatic as Tropicamide or Cyclopentolate. In infants, Atropine eye ointment should be used to dilate the pupil to avoid systemic absorption of the eye drops.

Examination of the fundus allows the examiner to comment on the optic disc, macular area, periphery of the fundus and the state of the retinal vessels.

The fundus is examined using:

1. Direct ophthalmoscope: A hand held instrument that gives a magnified view allowing detailed examination of the optic disc and macular area. The field of examination is small and not suitable for examination of the periphery of the fundus.

2. Indirect ophthalmoscope with the aid of a convex +20D or +30D lens, the central and peripheral fundus can be examined. The field seen using the binocular indirect ophthalmoscope is large and gives a stereoscopic view of the fundus but the magnification is small.

3. Slit lamp biomicroscopy: Using the slit lamp and a non-contact +90D lens, a stereoscopic view of the fundus allows detailed examination of the central fundus. The fundus can also be examined using a contact panfundusopic lens.

Retinal function tests:

When visualization of the fundus is obscured by a dense opacity as in mature cataract or vitreous hemorrhage, the function of the retinal periphery can be roughly estimated using the light projection test. No examination is complete without testing the macular functions in the presence of opaque media.

a. Light projection: See above.

b. Macular function tests:

Visual acuity, color and form sense are the main macular function tests. In opaque media, the color and form may be tested as follows:

i. Color test:

A colored light is projected from a torch or using the red & green color filters of the slit lamp/one eye at a time, with the other eye carefully covered. If the patient can distinguish between red and green, then color sense is intact giving a fair idea about the function of the cones.

ii. Form test:

An opaque disc is placed in front of the eye to be examined with the other eye covered. Holes are made in the center of the disc and a light is put behind the opaque perforated disc. If the patient can count the number and or the shape of the holes, the form sense is intact, giving a fair idea about the function of the cones.

Intraocular tension measurement:

Normal intraocular pressure (IOP) ranges between 10 mmHg to 22 mm Hg. Any rise above 22 mm Hg is considered a high IOP.

- The difference between the IOP in both eyes is usually less than 4 mm Hg.
- The diurnal variation does not usually exceed 4 mm Hg.

Methods of measurement of IOP

i. Indentation tonometry (Schiotz):

Based on the principle that a plunger will indent a soft eye more than a hard eye. The amount of indentation is measured on a scale and then the reading is converted into mmHg by the use of special tables.

ii. Applanation tonometry (Goldmann):

Applanation tonometry is based on the principle of flattening an area of the cornea with a double prism that has a diameter of 3.06 mm. In order to take a reading the tear film is stained with fluorescein and a cobalt blue filter is used. When the prism touches the cornea, two blue semicircles will be seen, which represent the fluorescein-stained tear film touching the prism. When the cornea has been perfectly flattened, the inner edges of the semicircles will just touch.

iii. Air-puff non-contact tonometry:

A jet of air flattens the central part of the cornea. The main advantage is that there is no risk of transmitting infection from one patient to another; however, the readings may be higher than the actual intraocular pressure. It is valuable in screening the patients.

Field of vision

It is the portion of space in which objects are visible during steady fixation of the gaze in one direction.

Types of visual field defects:

- 1- Concentric contraction of the field.
- 2- Sector field defect:
 - Hemianopia
 - Quadrantanopia
- 3- Isolated defect (Scotoma).
- 4- Irregular defect with distorted edges.

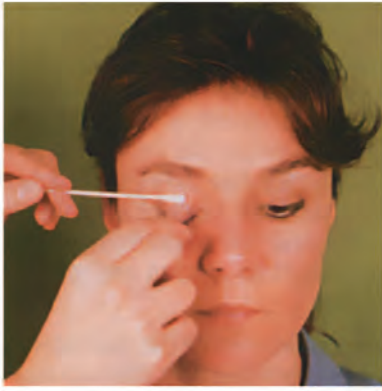NB: Scotoma is an isolated area of diminished or lost retinal sensitivity within the field margin surrounded by an area of normal vision.

Perimetry

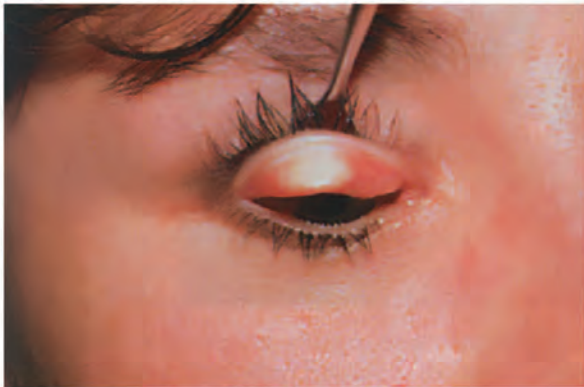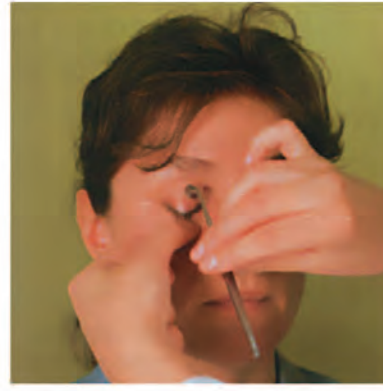
Means determination of topography of the field of vision so as to recognize any variation from normal.

Methods of estimation of visual field:

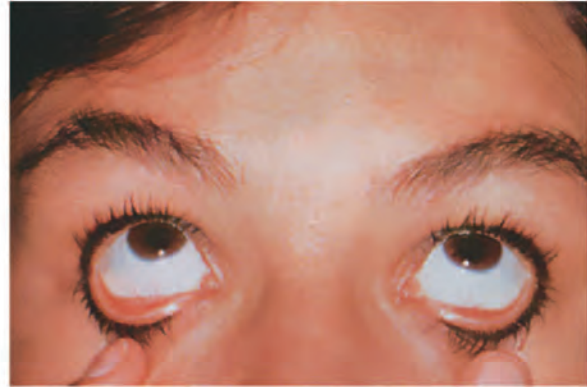- 1- Confrontation methods.
- 2- Scotometry or campimetry.
- 3- Amsler chart.
- 4- Arc perimeter.
- 5- Hemispherical protection perimeter.
- 6- Automated perimeter.



Technique for upper lid eversion



Examination of the upper tarsal conjunctiva



Examination of the lower tarsal conjunctiva



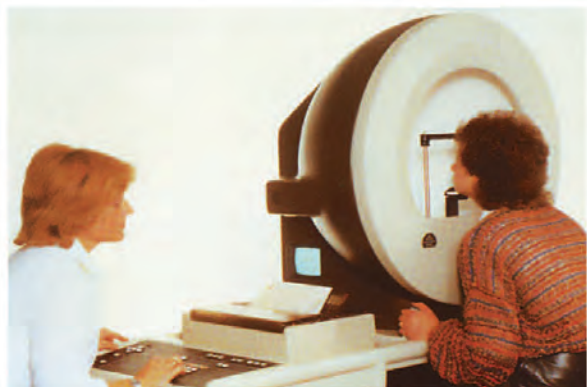Instruments used for ophthalmoscopy



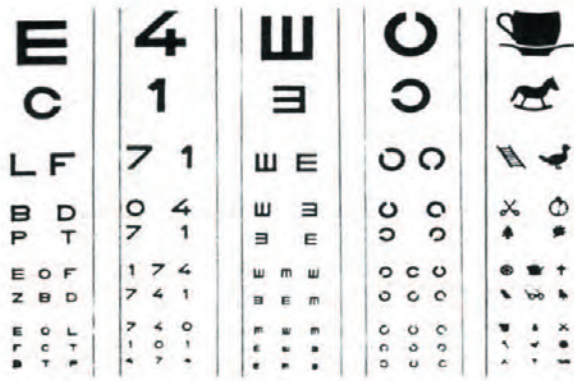Technique of direct ophthalmoscopy



Confrontation method for visual field testing



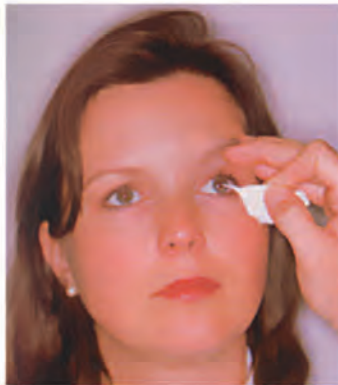Automated perimetry



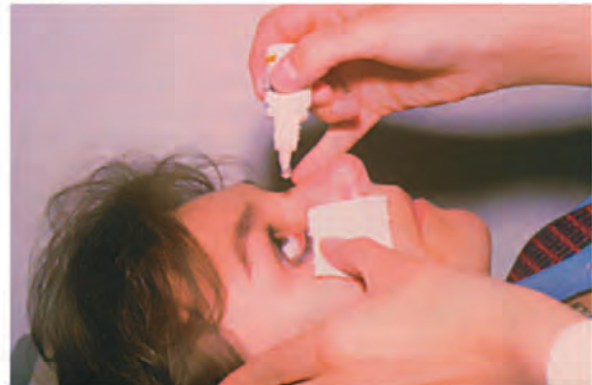Different visual acuity charts



Testing for direct and indirect pupillary light reaction



Testing the corneal reflex



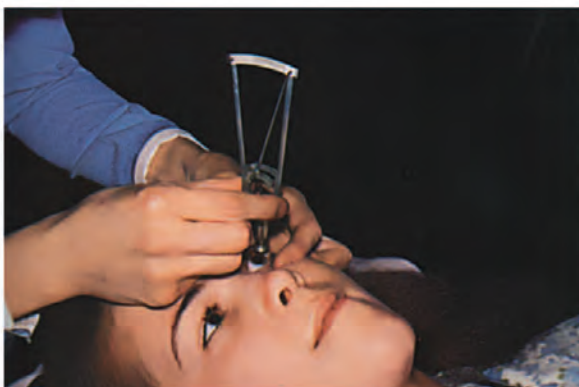Technique of eye drops instillation



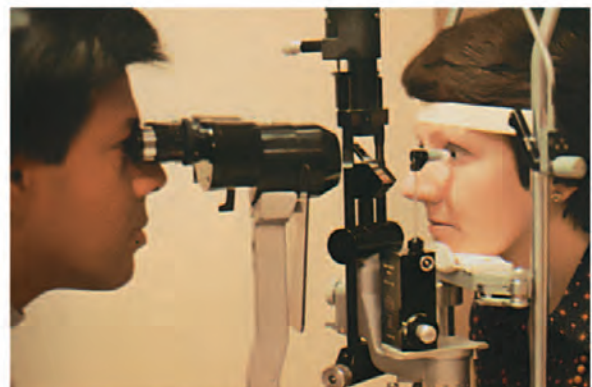Testing ocular motility in different directions of the gaze



Digital palpation of the ocular tension



Indentation (Schiotz) tonometry



Applanation tonometry

Chapter 2

Eyelids

Anatomy of the eyelids

Gross anatomy

Two movable muco-cutaneous folds, covering the eyeball. The upper lid is more movable and covers the upper 1/6 of the cornea when the eye is opened. The upper lid shows palpebral furrow, which lies above the cutaneous insertion of the levator palpebrae superioris muscle.

The palpebral fissure:

The 2 lids meet at 2 angles or canthi, with an elliptical palpebral fissure in-between. It ranges from 10 to 12 mm vertically and 25 to 30 mm horizontally.

Free lid margin is 2 mm broad with an anterior and posterior border and is divided into:

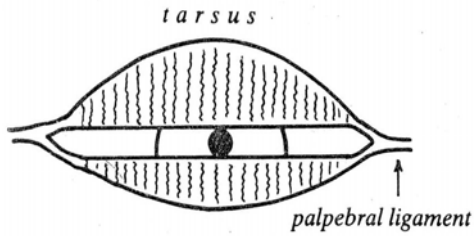
A) The ciliary portion: is divided into:

- Rounded anterior border, from it arise 2-3 rows of strong short cilia or eyelashes, about 100 in upper lid and 50 in lower lid. Modified sebaceous (Zeis) glands and sweat glands (Moll's) are in relation to the hair follicle.
- Right angled posterior border: In contact with the globe with the orifices of Meibomian glands in front of it, which secrete oily material that makes the lid margin water proof and covers the tear film on the cornea thus, delay its evaporation.

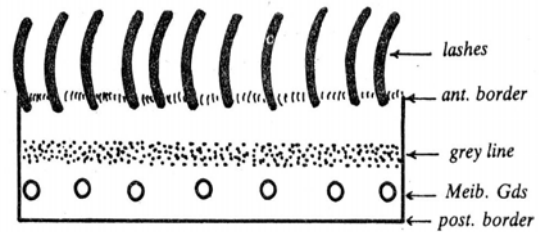
B) The lacrimal portion (medial to the puncti): Rounded with no borders, free from cilia and tarsal glands, and contains the lacrimal canaliculus.

Grey line

Is a line between the two borders just behind eyelashes and opposite the submuscular layer of the lid.

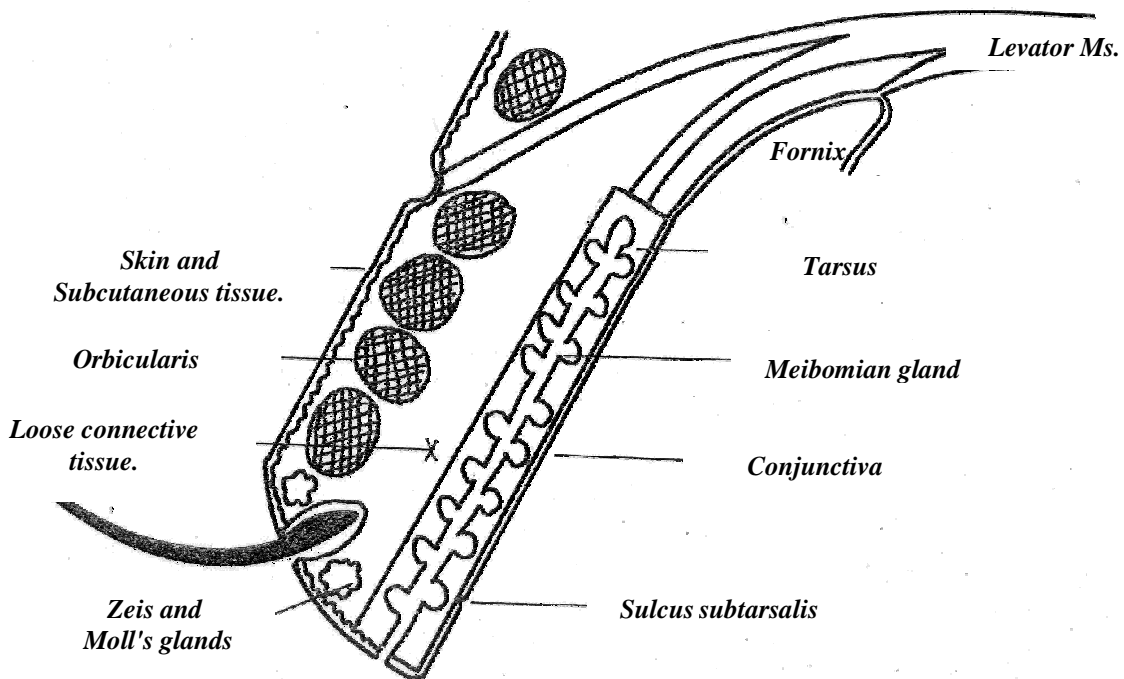


Upper & lower tarsus



The intermarginal strip

Lid Margin



Longitudinal Section in Upper Eyelid

Histology:

Vertical section in the lid shows the following layers from before backwards.

1- Skin: Thin, loosely attached, very elastic and distensible, with no much sebaceous glands.

2- Subcutaneous areolar tissue:

It contains hair follicles, sweat and sebaceous glands, pigment cells, some blood vessels, nerves and lymphatics, but no fat.

3- Muscle layer contains:

- a- The orbicularis oculi muscle (palpebral part).
- b- The insertion of levator palpebrae superioris muscle.
- c- Muller's muscle.

4- Submuscular areolar tissue:

Formed of loose connective tissue, contains the main blood vessels, lymphatics and nerves of the lids, traversed by levator fibers and is connected to the dangerous area of the scalp. Local infiltration anesthesia is given here.

5- Tarsus:

(30 X 10 mm. in upper lid) and (30 X 5 mm. in lower lid), being formed of condensed fibrous tissue, traversed by the Meibomian glands, (30 in upper lid and 20 in lower lid). Its extremities are connected to the orbital margin (medial & lateral) by medial & lateral palpebral ligaments, while superiorly and inferiorly to the orbital margins by septum orbitale.

6- Tarsal conjunctiva.

Muscles of the lid:

- Orbicularis oculi: Supplied by the facial nerve.
- Levator palpebrae superioris: Supplied by the oculomotor nerve.

- Muller's muscle: Involuntary muscle supplied by the sympathetic nervous system.

Diseases of Eyelids

Congenital Anomalies of Eyelids

1. **Epicanthus:** Semilunar fold of skin at the side of the nose covering the medial canthus and the caruncle leading to false convergent squint.
2. **Blepharophimosis:** Diminution of the horizontal width of the palpebral fissure, from 25-30 mm (normal) to 18-22 mm.
3. **Coloboma of the lid:** Triangular, quadrilateral, or irregular shaped defects of lid margin. Exposure keratitis may result. Surgical repair is necessary.
4. **Telecanthus:** Increased distance between the inner canthi.
5. **Epiblepharon:** Horizontal redundant medial skin of the lower eye lid, inducing vertical orientation of the cilia. Epiblepharon may coexist with entropion. Usually improves by age as the eyelid skin stretches.
6. **Ectropion and entropion:** Both conditions are rare and may be associated with other congenital anomalies.
7. **Distichiasis:** An extra row of lashes is present behind the gray line in the place of the ducts of the meibomian glands.
8. **Congenital ptosis:** Drooping of the upper eyelid below the normal position.

Ptosis

Definition:

Drooping of upper lid which is usually due to deficient development or weakness or paralysis of the levator palpebrae superioris. Normally upper lid covers the upper 1/6 of the cornea (2mm).

The degree of ptosis is measured by any of the following methods:

- (a) The distance from upper lid margin to the lower limbus at 6 o'clock when the eyes are looking straight ahead (i.e. in the primary position).
- (b) The distance from upper lid margin to the centre of the pupil with the eyes in the primary position.
- (c) The distance of the lid margin from the eyebrow.
- (d) The width of the palpebral fissure with the eyes in the primary position.

Ptosis can be classified into:

- 1. Mild: (1-2 mm of ptosis).
- 2. Moderate: (3 mm of ptosis).
- 3. Severe: (4 mm or more).

Symptoms and Signs:

- 1- The patient or parents complain of the bad cosmetic appearance of the drooping of UL.
- 2- There may be interference with vision if the pupillary area is covered and in congenital severe ptosis there may be amblyopia ex anopsia.
- 3- The superior palpebral furrow in marked ptosis is absent.
- 4- There is elevation of the eyebrows and wrinkling of the skin of the forehead as an attempt to overcome partial ptosis by contraction of the occipitofrontalis muscle.

5- When the condition is pronounced and bilateral it leads to a compensatory backward head tilt.

6- In paralytic ptosis, there may be partial or complete ophthalmoplegia.

Etiological types:

A- Congenital ptosis:

- May be simple, due to poor development or absence of levator muscle.
- May be associated with other lid deformities or congenital ophthalmoplegia.
- It dates since birth and is usually hereditary and bilateral.
- Epicanthus, telecanthus and blepharophimosis may be present, giving blepharo-phimosis syndrome.

B- Acquired ptosis:

It's usually unilateral.

1. Mechanical ptosis: Due to increased weight of the lid by multiple chalazia, syphilitic tarsitis, trachoma, severe palpebral spring catarrh, amyloid and hyaline degeneration of the tarsus and conjunctiva or tumors.

2. Traumatic ptosis: Due to:

- a. Mechanical effect of emphysema, hemorrhage or edema of eyelid.
- b. Injury of the levator or its nerve supply.
- c. Traumatic scarring of skin or conjunctiva.

3. Neurogenic ptosis: Due to:

- a. Levator paralysis caused by 3rd cranial nerve lesion.
- b. Muller's muscle paralysis due to sympathetic nerve lesion as in Horner's syndrome (ptosis, miosis, anhidrosis, enophthalmos, flushing of face, heterochromia iridis).

c. Marcus-Gunn Jaw winking ptosis: It is a rare form of associative movement in which the upper lid is elevated from the drooped position only on movement of the jaw due to congenital abnormal association between the 3rd and 5th cranial nerves.

4. Myogenic ptosis: As in myasthenia gravis and occasionally in myotonic dystrophy or chronic progressive external ophthalmoplegia.

5. Hysterical ptosis: Usually occurs in young females with some emotional trouble. It may be unilateral or bilateral. Characters;

- Trembling of the ptotic lid.
- No frowning of the forehead with eyebrow depression.
- Behavior of the patient.

6. Pseudo ptosis: Due to loss of support as in phthisis bulbi, enophthalmos and empty socket.

7. Senile (involutional) ptosis: Due to primary weakness of levator muscle, or aponeurotic defects (attenuation, dehiscence and disinsertion from the tarsus).

N.B.: *Aponeurotic ptosis may be secondary to:*

1. Post cataract and ocular surgery.
2. Blepharochalasis.
3. Local blunt trauma.
4. Following chronic lid edema.

Evaluation of a case of ptosis: The following should be noted:

(1) Visual acuity: Stimulus deprivation amblyopia in unilateral complete ptosis may be present.

(2) Degree of elevation of the lid by the levator muscle.

Levator action may be:

1. Excellent: greater than 10 mm.
 2. Good: 7 to 10mm.
 3. Fair: 4 to 6 mm.
 4. Poor: 3 mm or less.
- (3) Degree of elevation of the lid by the frontalis muscle.
- (4) Degree of elevation of the globe by the superior rectus muscle.
- (5) Ocular movements.
- (6) State of binocular vision.
- (7) Abnormal head posture (torticollis).
- (8) Corneal sensations: Corneal anesthesia of the upper part may occur in congenital ptosis.
- (9) Presence of Bell's phenomenon (upward rotation of the eye on lid closure).
- (10) Associated ocular congenital anomalies:
1. Epicanthus.
 2. Blepharophimosis.
 3. Marcus-Gunn phenomenon.

Surgical correction of ptosis:

1. Fasanella-Servat:

Indication: Mild ptosis with good levator function.

Principle: Part of Müller's muscle is excised together with the upper border of tarsus through conjunctiva.

2. Levator resection:

Indication: Moderate ptosis with good to fair levator function.

Principle: Resection and advancement of the levator muscle to strengthen the muscle.

If transcutaneous → Everbush's operation.

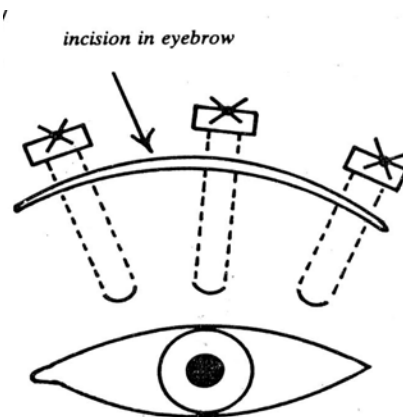
If transconjunctiva → Blascovic's operation.

3. Frontalis suspension: (Brow suspension) e.g. Hess Operation

Indication: Severe ptosis with poor levator function.

Principle: The upper lid is suspended to the occipitofrontalis muscle using endogenous materials as fascia lata or exogenous materials as prolene. It is better used in bilateral cases.

Disadvantage: Corneal exposure.



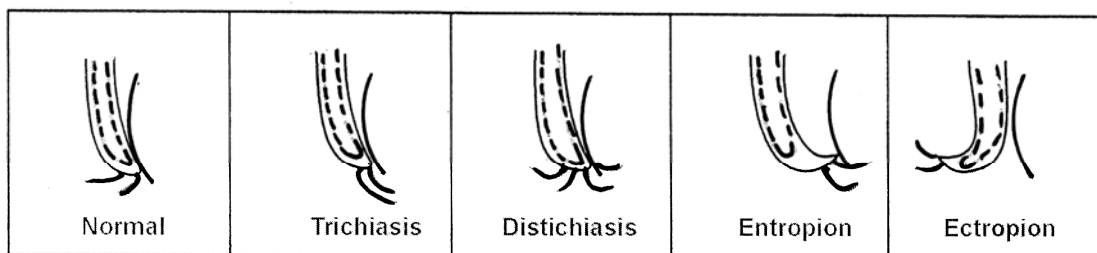
Hess' Operation

Treatment of acquired ptosis:

Acquired ptosis is treated by treating the cause:

1. Mechanical ptosis: Removal of tumor.
2. Myasthenia gravis: Prostigmine medication.
3. Paralytic ptosis: Wait for 6 months to allow regeneration then do surgical treatment.
4. Involutional ptosis: Levator apponeurosis repair or levator resection

Disorders of Eyelashes



Section of the upper eyelid showing normal and abnormal position of tarsus and eyelashes

Rubbing lashes

A term applied to the condition when 4 lashes or less are misdirected to rub against the cornea or conjunctiva.

Treatment: Is to permanently destroy the hair follicle by:

1. Thermal coagulation by diathermy:

Aim: To destroy hair follicle by coagulating its proteins through heat coagulation.

2. Electrolysis:

Aim: To destroy the hair follicle by denaturing its proteins.

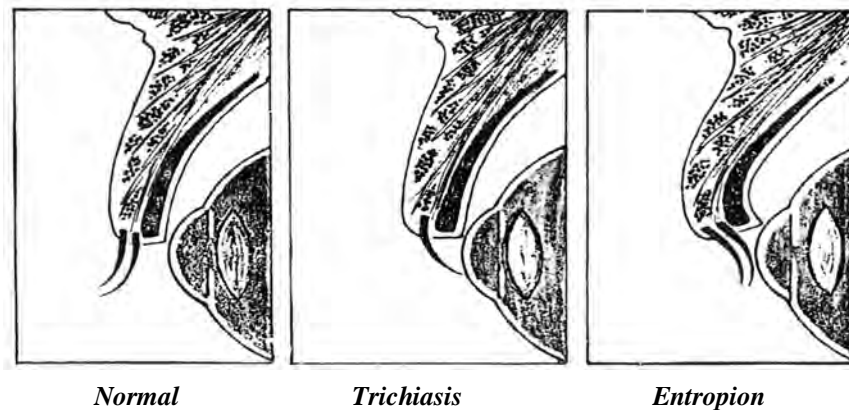
3. Cryocoagulation:

Aim: To destroy the hair follicle by freezing.

N.B: Epilation is not a permanent treatment since the lash grows again in 4-6 weeks, indicated only in:

- Before urgent intraocular operation.
- In presence of inflammation of cornea or conjunctiva.

Trichiasis



It is a condition where more than 4 lashes are rubbing against the cornea or conjunctiva.

Etiology:

1. Trachoma is the commonest cause due to fibrosis distorting the hair follicles.
2. Ulcerative blepharitis.

Symptoms:

1. Foreign body sensation.
2. Photophobia.
3. Lacrimation.
4. Blepharospasm.

Complications:**1. Conjunctival:**

- a. Chronic conjunctivitis.
- b. Conjunctival ulcer.
- c. Epithelial plaque.

2. Corneal:

- a. Recurrent ulceration leading to corneal opacities.
- b. Superficial vascularization.
- c. Epithelial plaque.

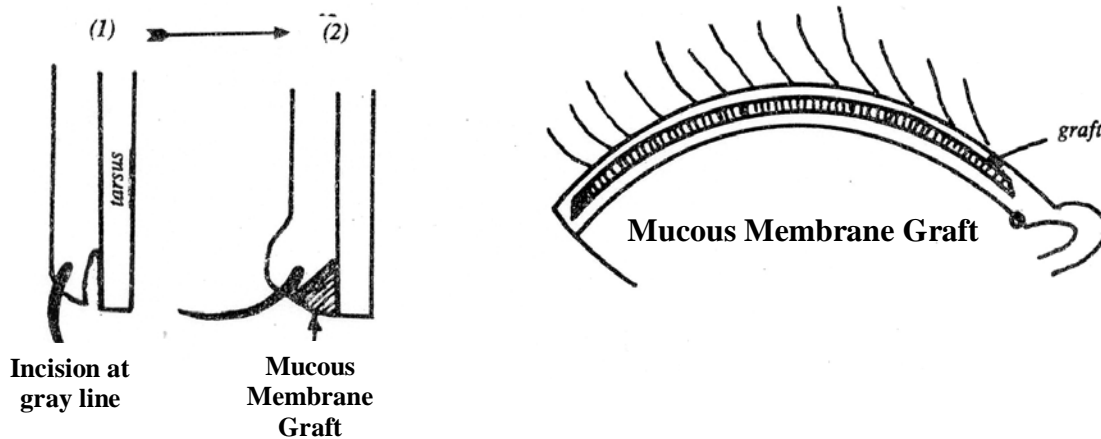
Treatment:**A) Trichiasis alone:**

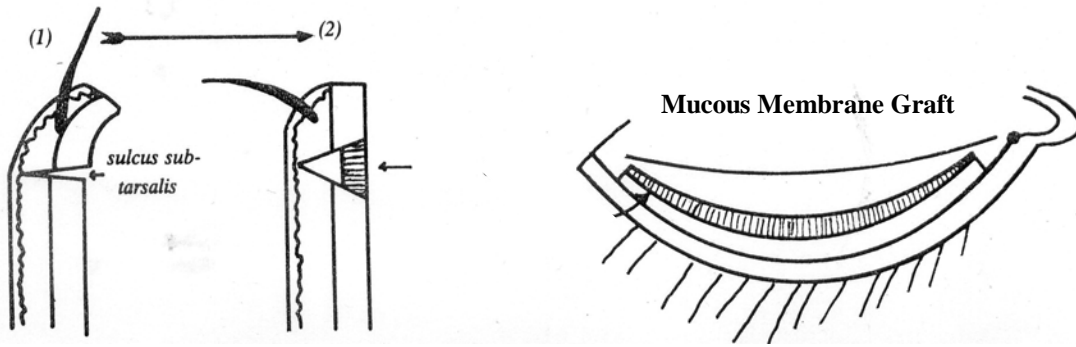
1. In the upper lid, *Van Millingen's* operation.

The principle is to displace the lashes away from the cornea by placing a buccal mucous membrane graft in the grey line.

2. In the lower lid, *Webster's* operation.

The principle is to straighten the tarsus and lengthen the palpebral conjunctiva by placing a buccal mucous membrane graft in an incision in the sulcus subtarsalis.

**Van Millingen's Operation**



Webster's Operation

B) Trichiasis with entropion:

LL trichiasis with entropion: *Webster's operation.*

UL trichiasis with entropion: *Snellen's operation.*

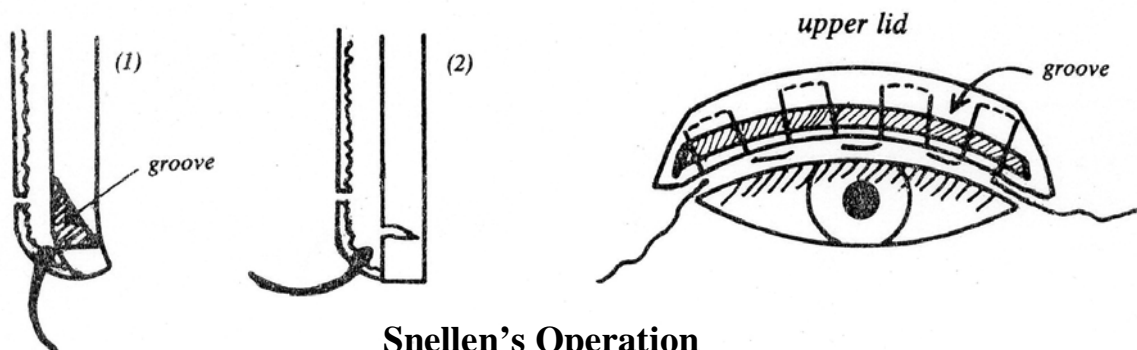
Snellen's operation:

Indications:

1. Cicatricial entropion of the UL.
2. Trichiasis with cicatricial entropion of UL

Principle:

- a) Straightening of the deformed tarsus by wedge resection of tarsus.
- b) Eversion of the lid margin.
- c) Displacement of the lashes away from the cornea.



Snellen's Operation

Distichiasis

An extra row of lashes situated in or near to the openings of the meibomian glands.

Treatment:

1. Cryotherapy.
2. Electrolysis.
3. Excision of a strip of tissue carrying the roots of the maldirected lashes.

Madarosis

Permanent absence of eye lashes due to destruction of the lash follicles. It may be partial or total.

Causes

- **Local causes:**

1. Inflammation: Stye, ulcerative blepharitis and trachoma.
2. Traumatic: Burns.
3. Surgical: Electrolysis and diathermy.

- **General causes:**

1. Alopecia.
2. Myxedema.
3. Syphilis and leprosy.

Treatment: Treatment of the cause, artificial lashes.

Poliosis

Whitening of the lashes.

Malpositions of the eyelid

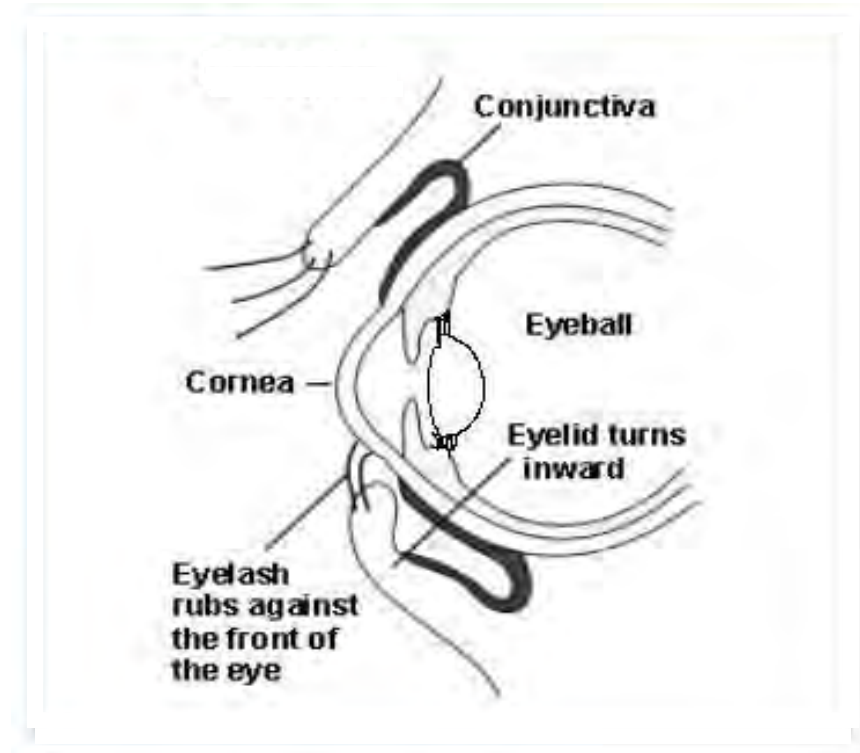
Entropion

Definition:

It is a condition in which the lid margin and the tarsal plate are turned inwards towards the eyeball.

Clinical picture:

Severe irritation, foreign body sensation and recurrent corneal ulceration which may lead to permanent corneal opacities and visual deterioration.



Entropion

Types:

1. **Cicatricial (fibrotic) entropion:** Fibrosis of the palpebral conjunctiva:

a) **Post-inflammatory:**

- 1- Trachoma.
- 2- Membranous conjunctivitis.

b) Post-traumatic:

- 1- Injuries and chemical burns.
- 2- Operations on the lids.

Treatment:

- 1) Cicatricial entropion of UL is corrected by wedge resection of the deformed tarsus (Snellen's operation).
- 2) Cicatricial entropion of the LL is corrected by lengthening of the cicatrized conjunctiva by a mucous membrane graft from the lip (Webster's Operation).

2. **Spastic entropion:** Is due to weak support of the lid in presence of blepharospasm as in:

a- Enophthalmos: Especially senile enophthalmos due to absorption of orbital fat.

b- Prolonged eye bandage.

Treatment:

- 1) Treat the cause: a- Treat blepharospasm. b- Remove eye bandage.
- 2) Correction of spastic entropion:

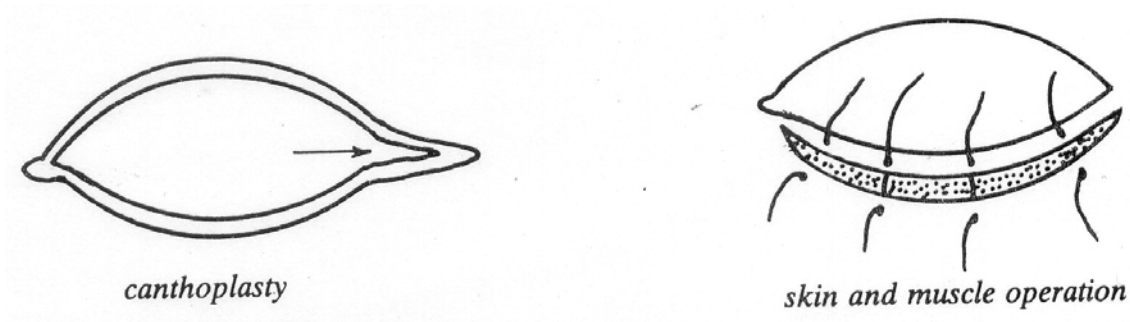
Temporary methods:

1. Painting the skin of the lid with collodion.
2. T-shaped adhesive plaster.
3. Alcohol injection: Subcutaneous injection of 1 cc of 70 % alcohol along the edge of the lid.
4. Lateral canthotomy: Division of the lateral canthus with scissors.

Permanent methods:

1. Lateral canthoplasty: Lateral canthotomy and covering the raw area with bulbar conjunctiva.

2. Skin and muscle operation: An elliptical piece of skin and spastic orbicularis muscle close to lid margin (Riolan) is removed.



3. **Involutorial (senile) entropion:** Usually occurs in the lower lid. It is caused by:

- 1- Loss of the subcutaneous elastic tissue of the lid.
- 2- A redundant loose skin of the lid.
- 3- Senile loss of orbital fat.

Any slight increase in the tone of the orbicularis palpebrum muscle or long continued bandaging of the eyes may produce entropion in an old patient.

Treatment:

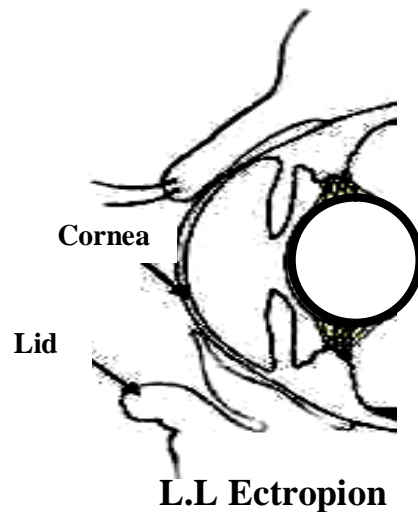
- Permanent correction may be achieved from orbicularis muscle overlap operation (Wheeler's operation).
 - The temporary measures as spastic entropion.
4. **Mechanical entropion:** Due to lack of support to the eye lid (without blepharospasm):
 - 1) Empty socket: After enucleation.
 - 2) Shrunken (atrophic) globe.
 - 3) Enophthalmos.

5. **Congenital entropion**: Usually affecting the whole lower eyelid.
6. **Infantile entropion**: In plump (fatty) infants due to increased subcutaneous fat in the cheeks and lids pushing LL margin inwards (it disappears after some time).

Ectropion

Definition:

Ectropion is rolling outwards of the eyelid from the globe. It usually affects the lower lid as it stands against gravity.



Clinical picture:

Symptoms:

Constant epiphora due to eversion of the lacrimal punctum, causing eczematous changes in the skin which tend to aggravate the ectropion.

Signs: Depending on the degree of ectropion

1. Mild: Exposure of the lower punctum.
2. Moderate: Exposure of tarsal conjunctiva.
3. Severe: Exposure of the lower fornix.

Complications:

- (1) Epiphora: Leads to eczema of the lid skin.
- (2) Eczema of the lid skin: Due to epiphora and leads to scarring of the lid skin and so to more ectropion (vicious circle).
- (3) Lagophthalmos: In severe cases.
- (4) Conjunctival complications:
 - a) Chronic conjunctival hyperemia.
 - b) Chronic exposure conjunctivitis.
 - c) Hypertrophy of the palpebral conjunctiva.
 - d) Xerosis.
- (5) Corneal complications:
 - a) Exposure keratitis.
 - b) Corneal ulceration.
 - c) Xerosis.

Types:

1. Spastic Ectropion:

Caused by spasm of the orbicularis palpebrum muscle when the lids are well supported and the overlying skin is firm e.g. in cases of proptosis or thickening of the conjunctiva from chronic conjunctivitis. It occurs typically in children and young.

Treatment:

- a) Removal of the cause of blepharospasm is necessary.
- b) As a temporary measure the eyelid may be supported, unless contra-indicated, by a well fitting bandage after manual correction of the ectropion.

2. Involutional (senile) ectropion:

Occurs only in the lower lid. It is due to redundancy of the tissues and laxity of the fibers of the orbicularis palpebrum muscle and palpebral ligaments. The condition is aggravated by conjunctivitis and epiphora.

Treatment:

- a) Conjunctivitis is treated if present.
- b) The line of treatment then depends on the degree of ectropion:

A) Mild degree:

1. Electrocautery Punctures:

The principle is to induce cicaterization at the site of electrocautery this will pull on the out-turned lid inwards.

2. Snellen's Sutures:

The idea of this procedure is the production of cicatricial bands along the tracks of the sutures which will pull on the conjunctiva and correct ectropion.

B) Advanced Degree:

This may be corrected by horizontal shortening of the lower lid by a wedge resection of tarsus and skin. The *Dimmer's modification of Kuhnt Szymanowski's* operation is the surgical procedure of choice.

Principle:

- 1- Removal of the redundant skin.
- 2- Decrease the weight of the lid by removal of a triangle of the tarsus.

3. Cicatricial (fibrotic) ectropion:

Due to scarring and contracture of the skin of the lower lids by burns, trauma or tumor.

Treatment: V to Y plasty or Z plasty in small scars, or free skin graft in large scars.

Free skin graft is taken from non-hairy area with color as that of the face as from:

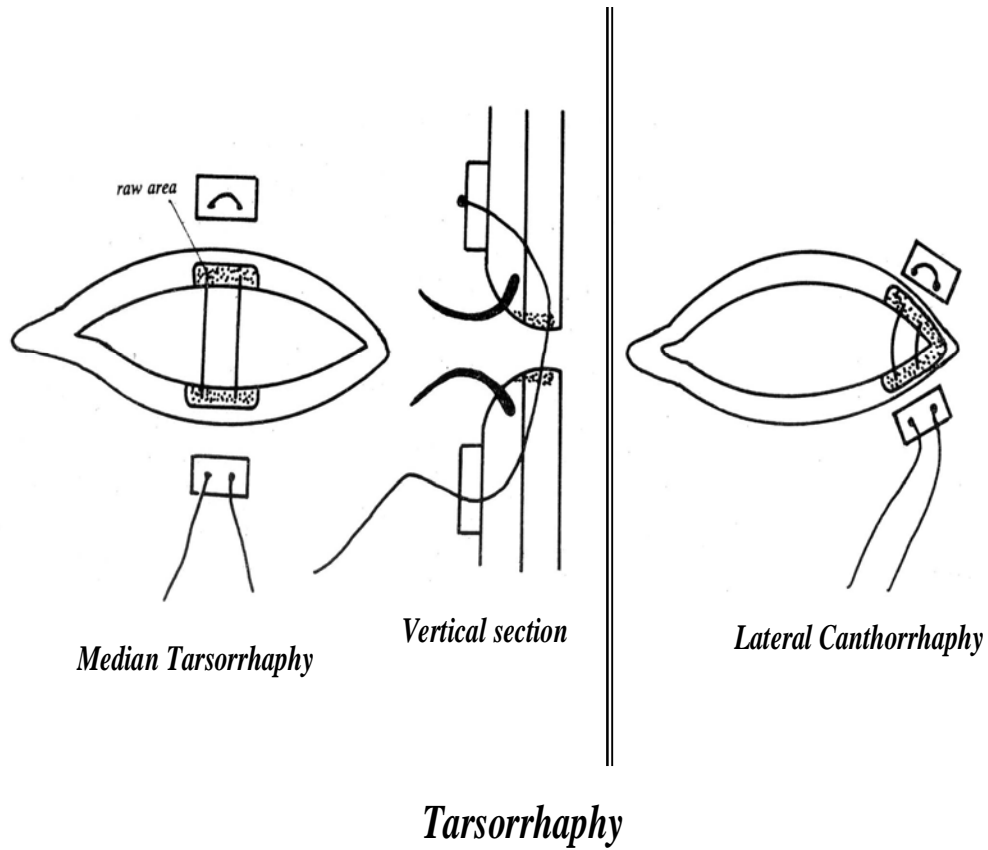
- Skin of the other eyelid.
- Skin behind the ear.
- Skin of the inner side of the arm.

4. Paralytic ectropion:

- a) Paralysis of the orbicularis oculi muscle due to a lower motor neuron lesion of the facial nerve, e.g. Bell's palsy.
- b) Trauma to orbicularis oculi muscle.

Treatment:

- a) Protection of the cornea: By drops during the day and ointment during sleep.
- b) Medical treatment: To help nerve regeneration by steroids, and facial massage.
- c) Lateral tarsorrhaphy: Either temporary or permanent to narrow the palpebral fissure.
- d) Fascia lata sling and silicone sling operation: In severe and recurrent cases.



5. Mechanical ectropion: Due to increased weight of lower lid by e.g. multiple chalazia.

Treatment: Treat the cause e.g. curette or excision.

6. Congenital ectropion: Rare.

Blepharitis

It is a chronic inflammation of the lid margin; it is one of the most common external eye disorders in clinical practice.

Types:

1. Squamous blepharitis.
2. Ulcerative blepharitis.
3. Parasitic blepharitis.
4. Angular blepharoconjunctivitis.

Etiology:

A. Predisposing Factors that cause hyperemia of the lid margin:

1. External irritants, such as dust, wind, heat and smoke.
2. Eye strain, e.g. refractive errors, muscular imbalance, over-work of fine nature, particularly in conditions of poor illumination and loss of sleep.
3. Constitutional factors, such as allergic reactivity of the lid margin, metabolic disturbances, e.g. excess carbohydrate in diet, dyspepsia, hepatic insufficiency, endocrine dysfunction and DM.

B. Exciting Factors that act on the predisposed lid-margin leading to blepharitis.

1. Seborrhoea, dandruff of the scalp and rosacea are often seen in squamous blepharitis.
2. Blepharitis is commonly caused by staphylococcus aureus.

Clinical Picture of Blepharitis:

Symptoms:

1. Itching.
2. Burning.
3. Lacrimation.
4. Photophobia.

Signs depend on the type of blepharitis:

1. Squamous blepharitis:

- a) Zeis glands secrete excessive amount of neutral lipids which are splitted by corynebacterium acne into irritating free fatty acids producing small, white scales (dried scales) between the lashes.
- b) Removal of the scales reveals a hyperemic lid margin without ulceration.

2. Ulcerative Blepharitis:

- a) Yellow crusts at the base of lashes gluing them together.
- b) Minute ulcers of the lid margin which bleed easily when crusts are removed.
- c) Differential Diagnosis: Dried discharge in conjunctivitis which when removed, leave an intact lid margin.

Sequelae:

1. Chronic conjunctivitis.
2. Madarosis due to destruction of the hair follicles.
3. Trichiasis due to healing of the ulcers by fibrosis.
4. Tylosis: Thickening and hypertrophy of the lid margin.
5. Epiphora due to destruction of the sharp posterior lid margin initiating the vicious circle of epiphora → eczema → ectropion → epiphora.

6. Ectropion.
7. Punctate keratitis affecting the lower one third of the cornea.
8. Marginal corneal ulcer.

3. Parasitic Blepharitis:

It is due to infestation with *Phthirus pubis* (the pubic lice). The lashes are covered with nits.

4. Angular blepharoconjunctivitis:

Etiology:

Morax Axenfeld diplobacilli, infection usually starts at the lateral angle due to relative tear deficiency with absence of lysozymes; the organism produces a strong proteolytic enzyme (which is inhibited by the lysozyme of tears).

Clinical picture:

- a) Red fissured and edematous lid margin localized to the angle.
- b) Macerated skin.
- c) Conjunctivitis.
- d) Discharge.

Treatment of Blepharitis:

A. General Treatment:

1. Attention to the general health.
2. Treatment of seborrhea of scalp.
3. Change of unhygienic atmosphere.
4. Correction of any refractive errors.
5. Avoidance of excess carbohydrates in the diet.

B. Local Treatment:

Treatment of Squamous blepharitis:

1. General treatment of seborrhea.
2. Remove scales with 3% sodium bicarbonate or diluted baby shampoo.
3. Rub antibiotic ointment into the lid margin.
4. The treatment must be prolonged 2-3 weeks.

Treatment of Ulcerative blepharitis:

1) Lid hygiene:

- a) Frequent massage to evacuate meibomian secretions.
- b) Meticulous removal of scales by scrubbing the lid margins with baby shampoo or 3% Sodium bicarbonate lotion.

2) Elimination of infection:

- a) The organisms are hidden in the hair follicles and meibomian glands, so treatment must be prolonged.
- b) Rub Gentamycin ointment into the lid margin after careful removal of scales and crusts.

Treatment of Angular blepharoconjunctivitis:

1. Boric acid 4% lotion.
2. Zinc preparations such as Zinc Sulphate 0.25 % drops to neutralize the proteolytic enzyme.
3. Antibiotic drops or ointment to kill the organism.

Treatment of Parasitic blepharitis:

1. Dilute Acetic acid 2% is used to loosen the nits.
2. Yellow oxide of mercury ointment 1% applied to the lid. It destroys the larvae.
3. Treatment is continued for 3 weeks.
4. Cutting the lashes may facilitate the treatment.

Inflammation of the Glands of the Lid

1. Stye: (Hordeolum externum)

Acute suppurative inflammation of Zeis gland and the lash follicle, forming a small abscess.

Etiology:

1. Infection of a Zeis gland by staphylococcus aureus.
2. Predisposing factors: Diabetes, poor general resistance, errors of refraction and ulcerative blepharitis.

Clinical picture:

Symptoms:

1. Swelling of the lid.
2. Severe pain, first dull then throbbing.

Signs:

Diffuse, red swelling which is:

1. Related to a lash.
2. Close to the lid margin.
3. Points on the skin side.

Treatment:

1. Hot fomentations.
2. Local antibiotic drops and ointment.
3. Systemic antibiotics.
4. When pointing occurs, the pus must be evacuated by:
 - a. Epilation of the related lash.
 - b. Horizontal incision to avoid gapping.
5. For recurrent cases: Correct the underlying cause.

2. Hordeolum internum:

Acute suppurative inflammation of the meibomian gland caused by staphylococcus aureus. It may be primary or it may occur on top of a chronic inflammation of the meibomian gland (chalazion).

It should be differentiated from hordeolum externum (stye).

3. Chalazion

It is a chronic non-specific inflammatory granuloma of a meibomian gland.

Etiology:

Etiology is unknown. It is a granuloma produced by the retained contents of the gland following obstruction of its duct, the duct of the gland becomes obstructed by:

1. Proliferation of epithelium (? vitamin A deficiency).
2. Dry secretions.

The retained secretion is irritant and excites a granulomatous reaction.

The granuloma contains many giant cells.

Symptoms:

1. Painless swelling of a long duration felt under the skin of the lids, it may be single or multiple.
2. Pain occurs only when it becomes infected (acute chalazion).

Fate of a chalazion:

1. Spontaneous resolution is rare.
2. Infection forming an acute chalazion.
3. Marginal chalazion: the granulation tissue forms only in the duct and projects on the lid margin as a red nodule.
4. It may open through the conjunctiva.

Treatment:

1. **Very small chalazion:** Local antibiotic and steroid preparation.
2. **Marginal chalazion:** Scraping from lid margin followed by diathermy.
3. **Moderate or large chalazion:** Vertical incision and scraping through the conjunctival side.
4. **Multiple chalazia:** Combined excision of tarsus and conjunctiva leaving the lower third of the tarsus (to avoid lid notching) with replacement by a mucous graft from the lip.
5. **Recurrent chalazion of the same gland:** Excision biopsy to exclude malignant tumor.

Lagophthalmos

Definition: Incomplete closure of palpebral fissure when the lids are closed.

Etiology:

A) Local causes:

1. Physiological: Lack of orbicularis tone during sleep.
2. Paralysis of orbicularis: e.g. facial palsy (bell's palsy)
3. Paralytic ectropion.
4. Scarring of the lid.
5. Coloboma of the lid.
6. Proptosis.

B) General causes:

Severe illness and weakness with atony of the muscles.

Clinical picture:

1. Epiphora.
2. Chronic conjunctivitis and xerosis.

3. Exposure keratopathy: Exposure of the cornea during sleep leads to dryness of its lower third. The upper part of cornea is protected by the upper lid as the eyes roll up during sleep (Bell's phenomenon).

Treatment:

1. Treatment of the cause e.g. facial palsy.
2. Protection of the cornea during the day by glasses or contact lenses.
3. Protection of the cornea during sleep by applying ointment at night.
4. Tarsorrhaphy: It may be lateral, median or paramedian; temporary or permanent.

Symblepharon

Definition:

Adhesions between bulbar and palpebral conjunctiva.

Etiology

1. Burns and caustics.
2. Post inflammatory e.g. trachoma and diphtheria.
3. Post operative e.g. pterygium operation.
4. Ocular cicatricial pemphigoid.

Types:

1. Anterior: Between lid margin and cornea.
2. Posterior: At the fornix (trachoma).
3. Total: Between the lid and globe (burns).

Clinical Picture:

1. Bad cosmetic appearance.
2. Limitation of ocular motility and diplopia.
3. Diminution of vision in cases of corneal affection.
4. Exposure keratopathy, chronic conjunctivitis and Ankyloblepharon.

Treatment:

1. Cut the adhesions.
2. Mucous membrane graft: To cover the two opposite surfaces.
3. Keratoplasty: If the cornea is opaque.
4. Contact shell is used until healing occurs.

Lid Edema

The lid is a ready site for the accumulation of edema fluid owing to the looseness of its subcutaneous areolar tissue.

Types

- 1. Traumatic edema:** Following injuries or surgery.
- 2. Inflammatory edema:** Active edema due to inflammation of lid, conjunctiva, cornea, iris, or endophthalmitis.
- 3. Non inflammatory edema:**
 - a. Allergic angioneurotic edema:**

Acute onset, without signs of inflammation. It may occur due to local medication e.g. Atropine or due to systemic vasomotor disturbances e.g. with menses.
 - b. Passive systemic edema (Puffy Eyelids):**

Due to renal and cardiac diseases.

Differential diagnosis:

- a) Emphysema.
- b) Myxedema.
- c) Dermatochalasis.

Xanthelasma

Subcutaneous deposits of cholesterol in the medial canthus region. It is seen in diabetics and in patients with hypercholesterolemia.

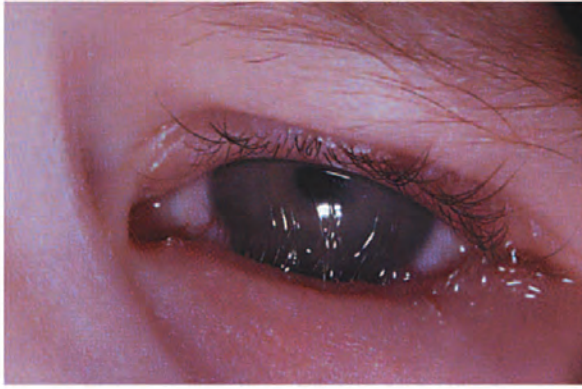
Dermatochalasis

Redundancy of upper eyelid skin in old age associated with bulging of the orbital fat.

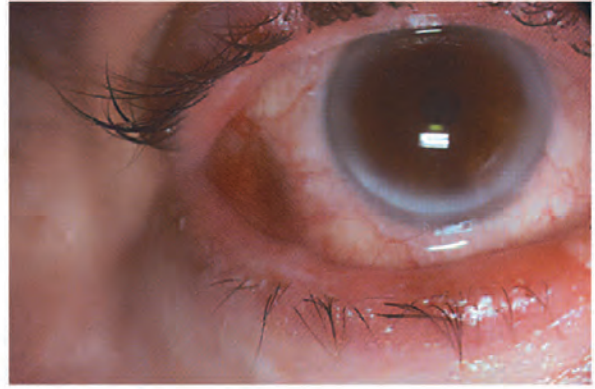
Treatment: Blepharoplasty.

Blepharochalasis

Recurrent attacks of upper lid edema, leading to redundancy of upper lid in young age.



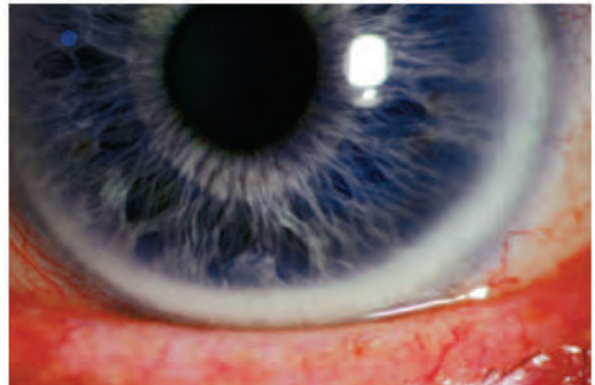
Congenital entropion



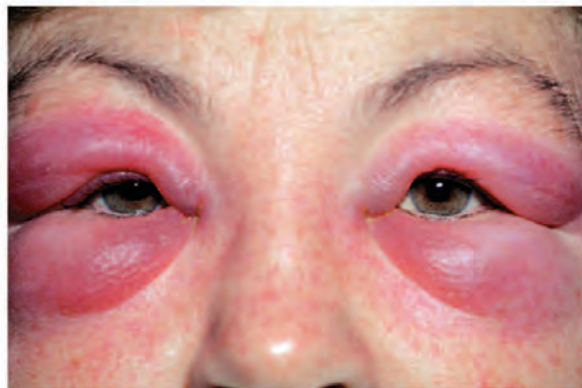
Chronic blepharitis



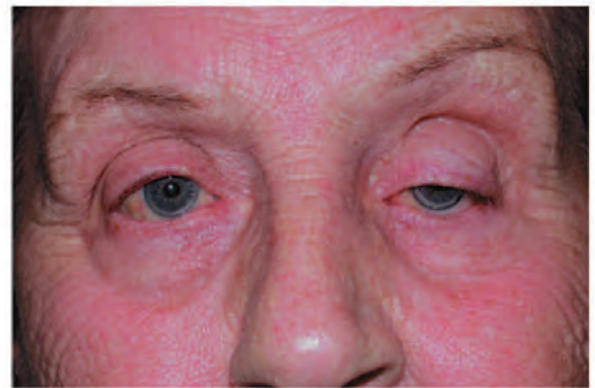
Right LL Chalazion



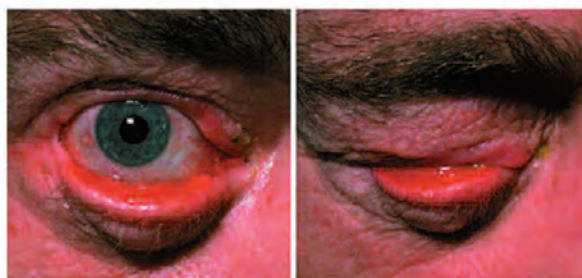
Corneal arcus



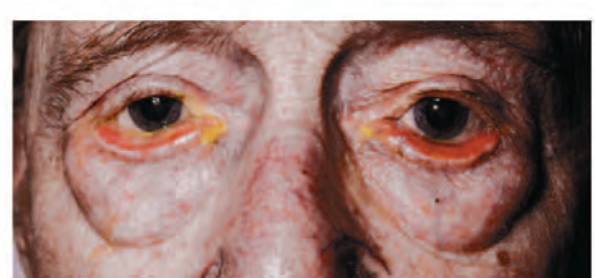Bilateral erythema and pitting lid oedema



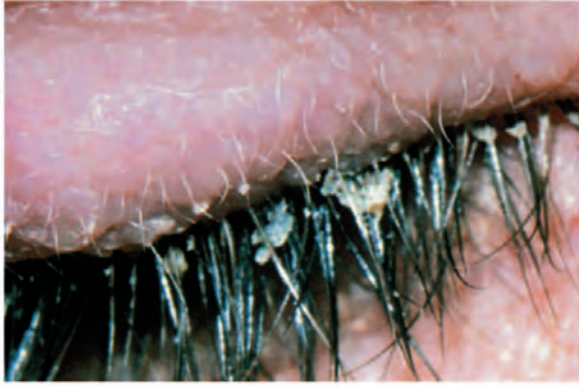Severe left involucional ptosis with absent upper lid crease and a deep upper sulcus



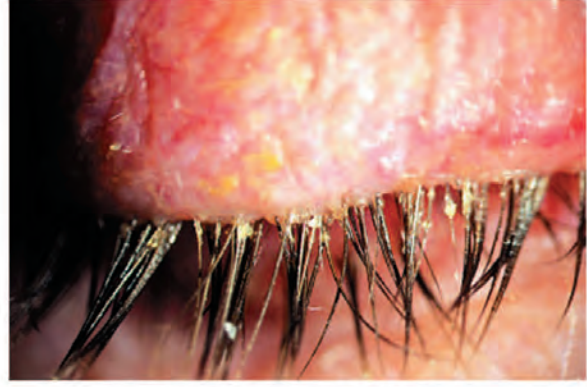Severe ectropion



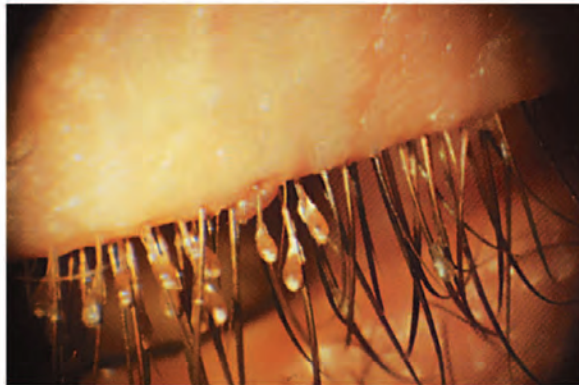
Severe bilateral ectropion and conjunctival kera-
tinisation



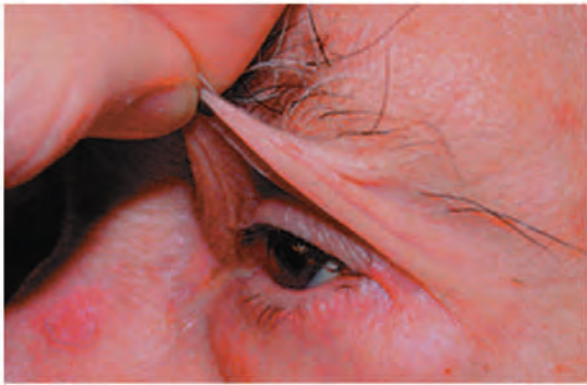
Squamous Blepharitis



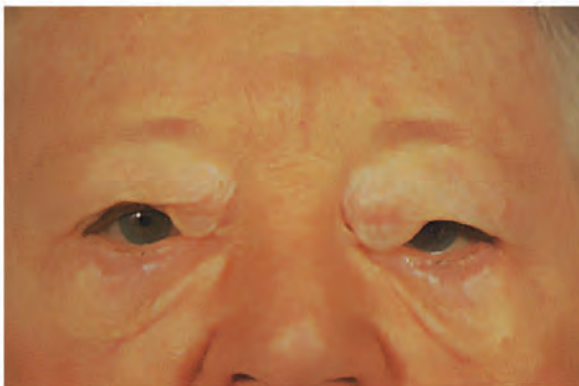Ulcerative Blepharitis



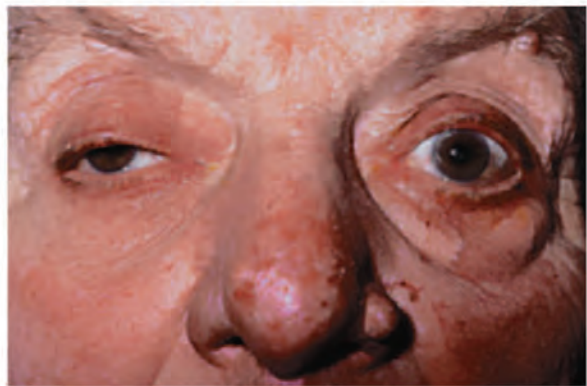Parasitic blepharitis



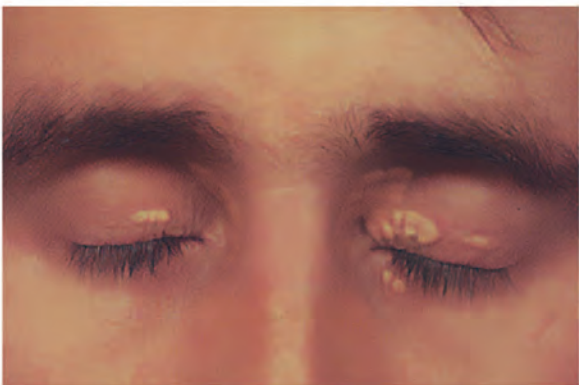Redundant upper lid skin



Dermatochalasis



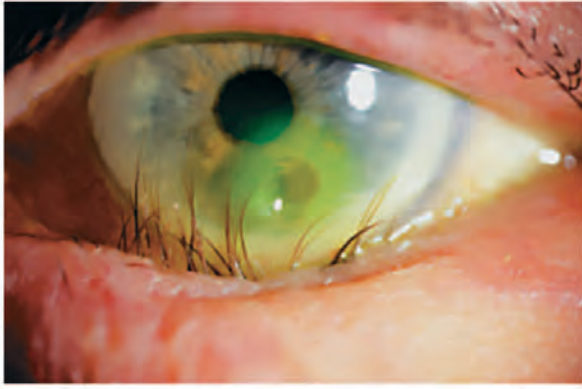
Severe right ptosis and slight divergence of the eye
(right 3rd nerve palsy)



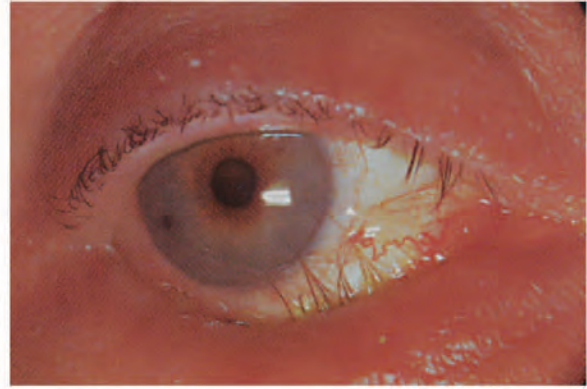
Xanthelasma



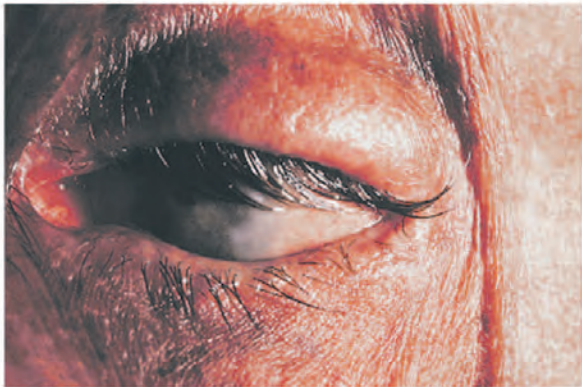Telecanthus



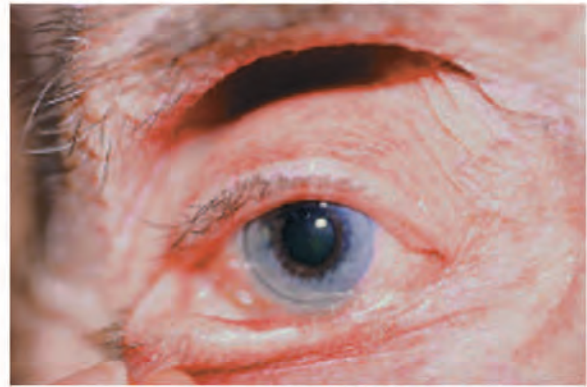
Rubbing lashes



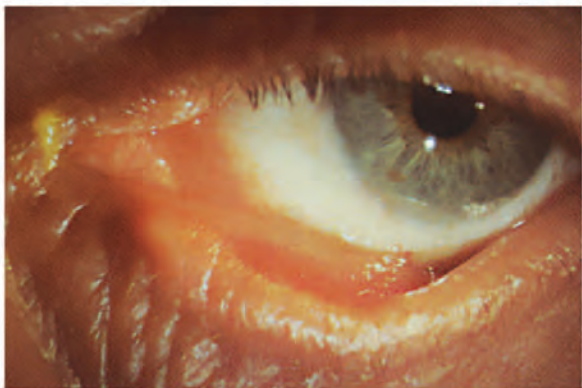Involutional (senile) entropion



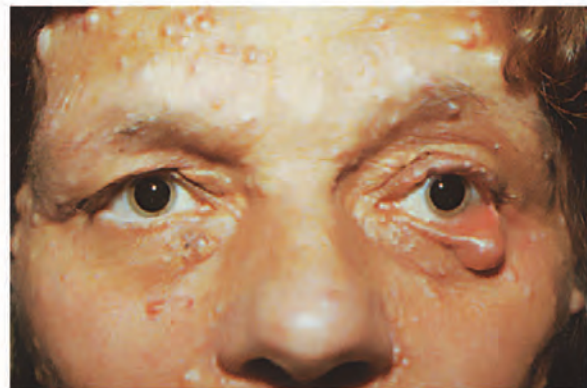Cicatricial entropion due to trachoma



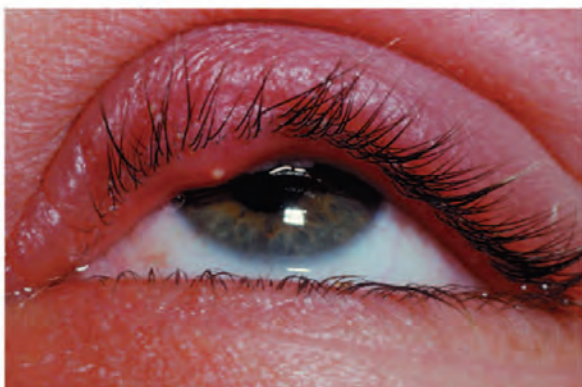Medial canthal tendon laxity



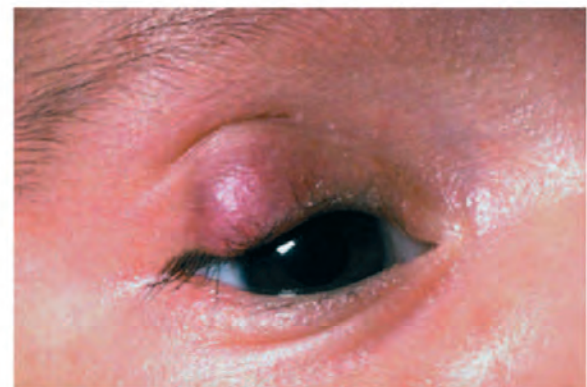
Involutional ectropion



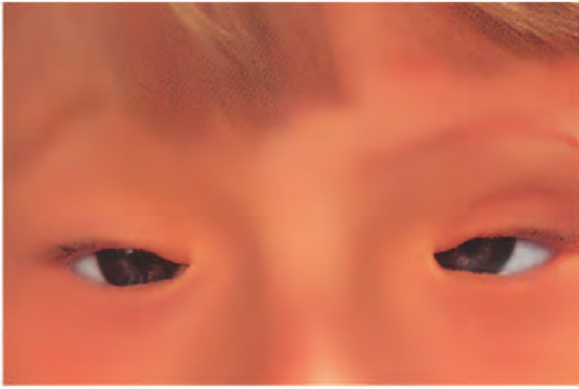
Mechanical ectropion



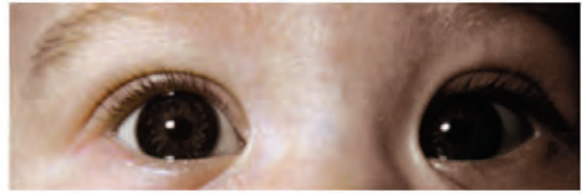Stye



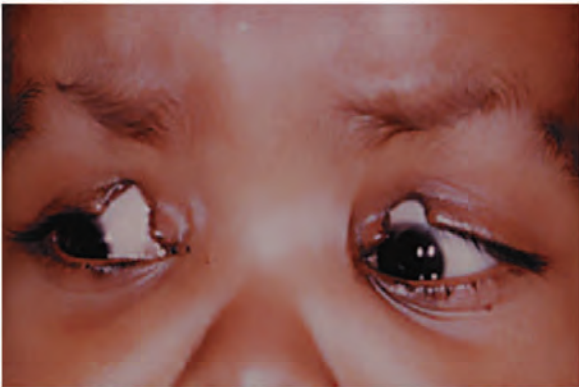Chalazion



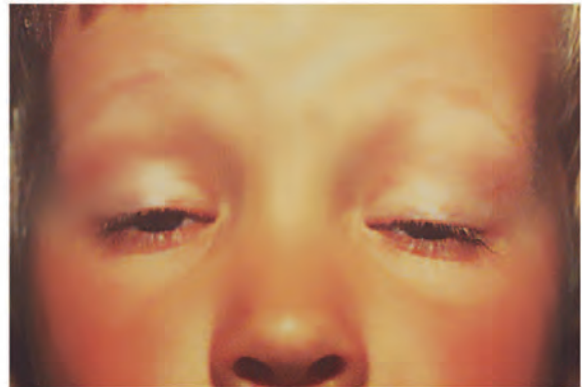Epicanthus



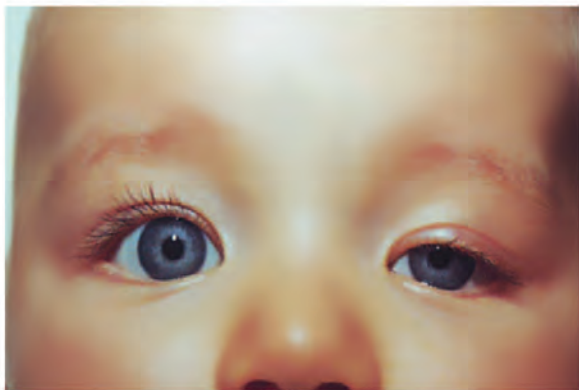Epicanthus



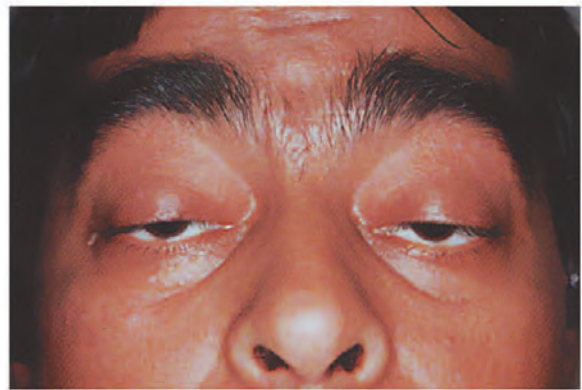Severe bilateral upper lid colobomas



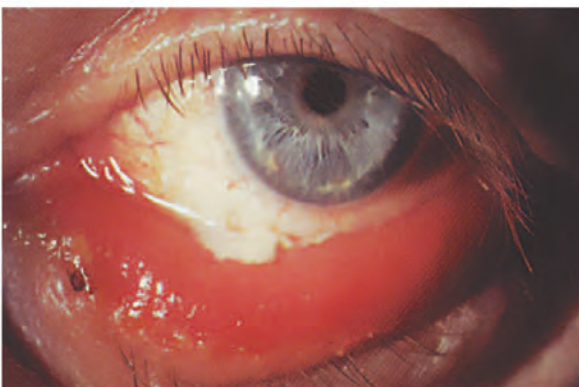
Bilateral congenital ptosis



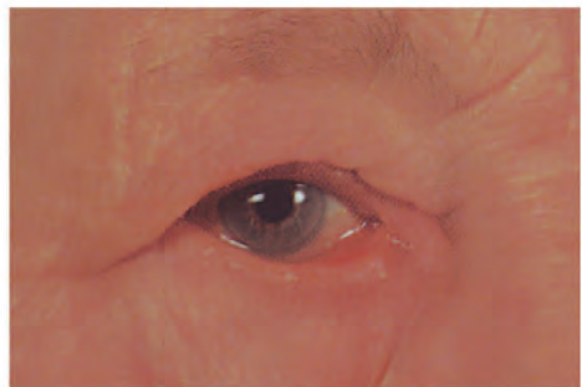Left congenital ptosis



Myogenic Ptosis
(Myasthenia gravis)



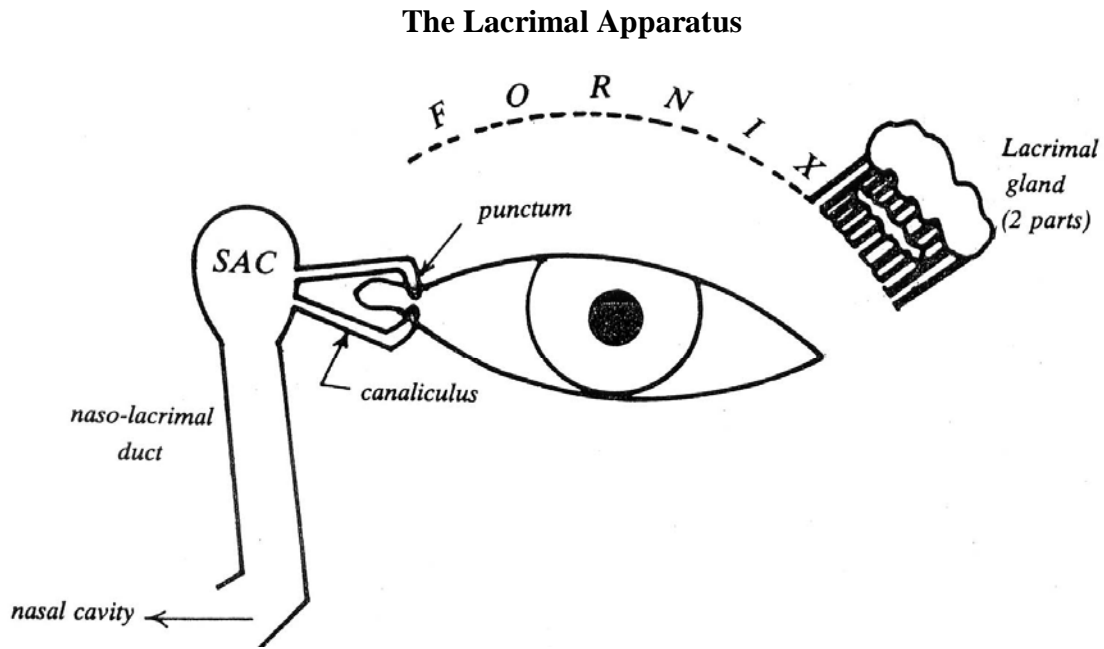
Paralytic Ectropion
(7th nerve palsy)



Medial ectropion of the right lower eyelid

Chapter 3

Lacrimal System



Anatomy of the lacrimal system:

The lacrimal system consists of:

1. Secretory part (lacrimal secretory system).
2. Excretory part (lacrimal drainage system).

The lacrimal secretory system is formed of:

1. The main lacrimal gland (orbital portion & palpebral portion).
2. The accessory lacrimal glands (the glands of Krause, glands of Wolfring).

The lacrimal drainage system is formed of:

a. Two puncti:

Located at the posterior edge of the lid margin, not seen except when the lid is everted. Each punctum lies 6 mm from the medial canthus on a slightly elevated portion called the lacrimal papilla.

b. Two canaliculi:

Are fine tubes which carry tears from the puncti to the lacrimal sac.

Each canaliculus is made of 2 portions:

- Vertical part: 2 mm.
- Horizontal part: 8 mm.

Before entering the lacrimal sac, they unite into a common canal, 1-2 mm long that opens at the junction between the upper 1/3 and lower 2/3 of the sac.

c. Lacrimal sac:

- Site: The lacrimal sac lies in the lacrimal fossa in the medial wall of the orbit.
- Size: 8×12 mm (when distended).
- The lacrimal sac is formed of:

Body: This forms the main part.

Fundus: Blind upper portion which lies above the medial palpebral ligament.

Neck: The neck is narrow and continuous with the naso-lacrimal duct.

Horner's muscle: Is a part of the orbicularis which is inserted into the lacrimal fascia which surrounds the sac. Contraction of the muscle (when the lid is closed) will pull on the sac and create vacuum in it. This mechanism will suck the tears from the conjunctival sac into the lacrimal sac.

d. Naso-lacrimal duct:

The naso-lacrimal duct is 12-24 mm long. It passes from the lower end of the sac to open in the inferior meatus of the nose; the opening into the

inferior meatus of the nose is guarded by Hasner's valve. The direction of the duct is downward, slightly backward and laterally.

Precorneal Tear Film: It is formed of 3 layers:

a) **Outer lipid layer:** Secreted by Meibomian glands.

Function:

- Prevent rapid evaporation of tears.
- Lubricates the eyelids over the globe.

b) **Middle aqueous layer:** Secreted by the lacrimal gland.

Function:

- Supplies oxygen to the corneal epithelium.
- Antibacterial as it contains lysozyme.

c) **Inner mucinous layer:** Secreted by the goblet cells.

Function: Makes the corneal epithelium hydrophilic.

Diseases of Lacrimal system

Congenital naso-lacrimal duct obstruction

(Congenital or infantile dacryocystitis)

It usually occurs due to imperforate Hasner's valve at the lower end of the naso-lacrimal duct.

Clinical picture:

1. Epiphora, usually noticed at 2-3 weeks after birth.
2. Recurrent conjunctivitis.
3. Pressure over the lacrimal sac leads to reflux of clear fluid, mucus, muco-pus or sometimes frank pus.

Treatment of congenital dacryocystitis:

- 1. Conservative:** Antibiotics with hydrostatic massage of the lacrimal sac, the mother is instructed to press on the lacrimal sac in a downward direction. This may help to remove any remnants of epithelium or to open Hasner's valve. This is tried for a long period up to 6 months.
- 2. Probing** is successful if done carefully as the lacrimal passages are still elastic.
- 3. Repeated syringing & irrigation** with saline may cure the condition.
- 4. Silicone intubation** of the lacrimal drainage system may be beneficial if probing fails to cure the obstruction, the tube should remain in situ for 6-12 months.
- 5. Dacryo-Cysto-Rhinostomy (DCR).**

Acute Dacryocystitis

Definition: Acute suppurative inflammation of the lacrimal sac.

Etiology:

- Predisposing factor: Naso-lacrimal duct obstruction.
- Causative agent: Pneumococci, Staphylococci and Streptococci.

Symptoms:

1. Severe pain.
2. Fever.

Signs:

1. Marked edema and redness of skin over the sac.
2. Regurgitation test: -ve due to congestion of the epithelium of canaliculi.
3. Tender swelling of lacrimal sac.
4. Abscess formation with fluctuation.

Complications:

1. Lacrimal fistula: The sac may burst anteriorly through the skin.
2. Pyocele: Canaliculi may become obstructed.
3. Orbital cellulitis and cavernous sinus thrombosis.
4. Chronic dacryocystitis.

Treatment:

1. During the acute phase:

- a. Antibiotics: Systemic and topical.
- b. Hot fomentations.
- c. Lotions: To clean the pus.
- d. Incision and drainage if an abscess forms.

2. **After the acute attack subsides:** Dacryocystorhinostomy with fistulectomy if needed.

Chronic Dacryocystitis

Definition:

A chronic inflammation of lacrimal sac secondary to obstruction of the naso-lacrimal duct. It is the commonest lacrimal sac disorder.

Etiology:

- Predisposing factor: Naso-lacrimal duct obstruction.
- Causative agent:
 - a) Pneumococci in 80%.
 - b) Staphylococci, Streptococcus, trachoma, and fungi.
 - c) TB and Syphilis: Rare.

Symptoms:

1. Watery eye.
2. Discharge.

Signs:

1. Swelling of lacrimal sac below the medial palpebral ligament.
2. Regurgitation test +ve: Pressure on the swelling causes regurge of mucous or pus.

Complications:

1. Chronic conjunctivitis.
2. Epiphora, eczema and ectropion (vicious circle).
3. Hypopyon ulcer.
4. Endophthalmitis following intraocular operation.
5. Mucocele and pyocele: if the canaliculi are obstructed.
6. Lacrimal fistula.

Investigations: See Epiphora.

Treatment:

1. **Treatment of the cause of obstruction:** e.g. relieve congestion, removal of a nasal polyp.
2. **Dacryocystorhinostomy:** Operation of choice.

Principle: Is to create a surgical opening between the lacrimal sac and the nasal mucosa of the middle meatus, allowing drainage of tears directly into the nose bypassing the obstructed naso-lacrimal duct.

Indications:

- a. Chronic dacryocystitis.
- b. Mucocele of the lacrimal sac.
- c. Lacrimal fistula (DCR and fistulectomy).

Contraindications:

- a) Bad lacrimal sac: Extensive adhesions and neglected cases.
- b) Bad nasal mucosa: Atrophic rhinitis and polypi.

- c) T.B and tumors of the sac.
- d) Hypopyon ulcer.

3. Dacryocystectomy:

Idea: Removal of the lacrimal sac.

Indications: Indicated in cases where DCR can't be done.

Canaliculitis

Is a rare disease which may be due to infection with pyogenic organisms, trachoma, specific organism or fungus, the commonest type is mycotic canaliculitis which is caused by *Actinomyces Israeli* and characterized clinically by:

1. Persistent epiphora not responding to ordinary treatment.
2. Chronic conjunctivitis most marked at the medial canthus.
3. Prominent and dilated (patulous) lacrimal punctum.
4. On pressure, a mucopurulent discharge which sometimes contains concretions, is seen extruded from the dilated punctum.

Treatment:

Canaliculotomy is the curative method in these cases (slit the posterior wall of the canaliculus, all the fungoid masses are curetted and irrigate with saline).

Dry Eye

Etiology:

1. Congenital absence of the lacrimal gland.
2. Inflammation of lacrimal gland e.g. sarcoidosis.
3. Tumors of lacrimal gland: e.g. mixed lacrimal gland tumor.
4. Keratoconjunctivitis sicca: Autoimmune disease leading to atrophy and fibrosis of the lacrimal gland, it occurs usually in females and may be

associated with arthritis and dry mouth (Sjogren's syndrome).

5. Conjunctival scarring: Due to trachoma, chemical burns, Stevens-Johnson syndrome and ocular cicatricial pemphigoid.

Clinical picture:

1. Irritation and foreign body sensation.
2. Deficient tear production measured by filter paper (Schirmer's test).
3. Rose Bengal staining of degenerated epithelium of conjunctiva, cornea and mucus.
4. Punctate epithelial erosion of the cornea.
5. Tear film break - up time (BUT) is diminished.

Treatment:

1. Protective glasses and contact lenses.
2. Tear substitutes (eye drops, eye gel).
3. Occlusion of the puncti to reduce tear drainage.
4. Systemic steroids (autoimmune cases).

Watery Eye

1. Lacrimation

Lacrimation is over secretion of tears.

Etiology:

- a. Emotional conditions.
- b. Reflex lacrimation from foreign body or inflammation of the lid margin, conjunctiva, cornea, iris and ciliary body, glaucoma, errors of refraction, and latent squint.

2. Epiphora:

Epiphora is overflow of tears onto the cheek due to inadequate drainage due to lacrimal pump failure or obstruction of the lacrimal passages.

Etiology:

A. Lacrimal pump failure:

- a. Lid margin: Abnormality in posterior border of the lid margin.
- b. Ectropion.
- c. Orbicularis muscle: Facial palsy.

B. Obstructive epiphora:

The obstruction may be at the level of the puncti, canaliculi, lacrimal sac naso-lacrimal duct or at the nose.

The obstruction may be:

1. Congenital e.g. punctual atresia, NLD obstruction.
2. Inflammatory e.g. trachoma, herpes, fungal.
3. Traumatic e.g. bony fractures, surgical trauma.
4. Foreign body e.g. lashes.
5. Tumors e.g. nasal polyps, maxillary tumors.

Clinical Evaluation of Epiphora

➤ Exclude causes of excessive lacrimation.

➤ *Investigations:*

1. **Regurgitation test:** Reflux of pus or tears from the puncti in case of obstruction of the naso-lacrimal duct.
2. Instill a drop of fluorescein in the conjunctival sac and a cotton pellet under the inferior turbinate of the nose (**fluorescein dye test**).
3. The lacrimal passage is **irrigated with saline**, if fluorescein is not recovered and saline does not reach the nose, there is complete block.
4. **Dacryocystography:** A radiocontrast medium is injected and X-ray is done at intervals to detect filling of the lacrimal system.
5. **Plain X-ray:** For diagnosis of tumors or fractures.

Treatment of Epiphora

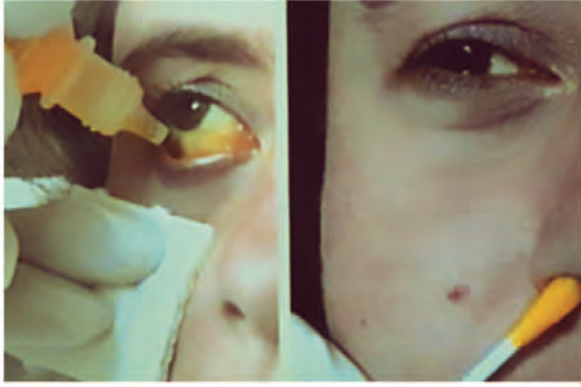1. Treatment of the cause: e.g. Ectropion and nasal causes of epiphora.
2. Stenosis of puncti and canaliculi: Dilatation and probing.
3. Obstruction of Naso-lacrimal duct:

a. Congenital obstruction:

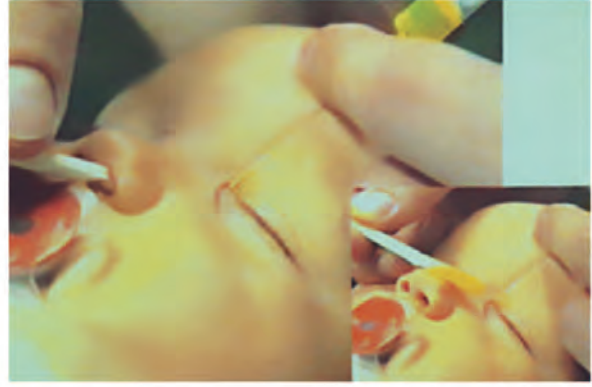1. Hydrostatic massage.
2. Dilatation and probing.
3. Dacryocystorhinostomy.

b. Acquired obstruction:

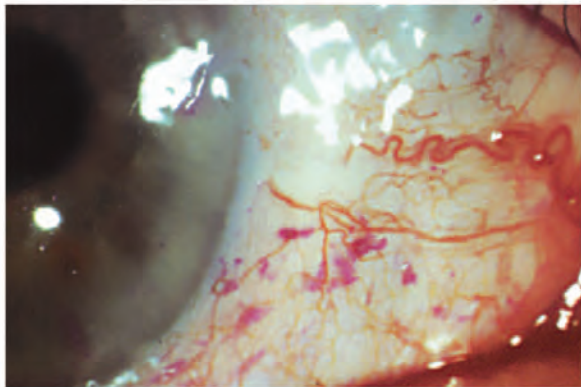
1. Dilatation and probing usually fails.
2. Dacryocystorhinostomy.
3. Dacryocystectomy.



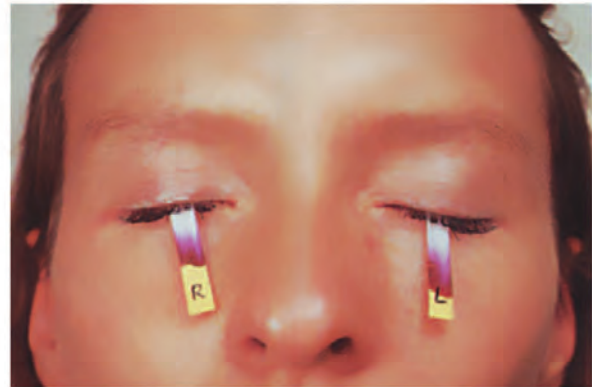Fluorescein dye test



Irrigation of the lacrimal system in an infant



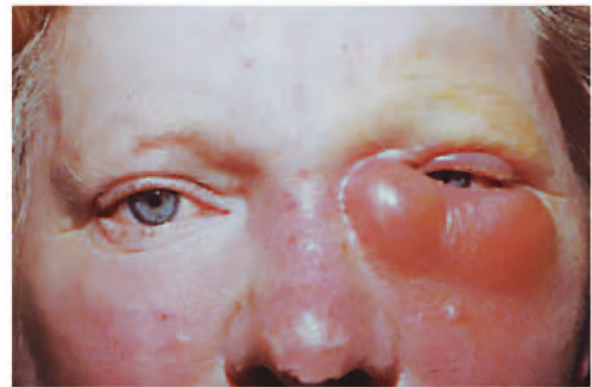Rose bengal staining



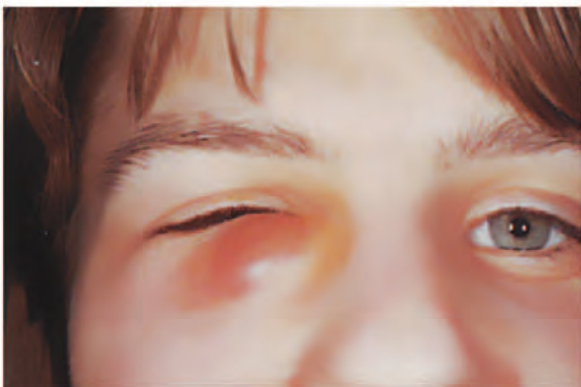Schirmer's test



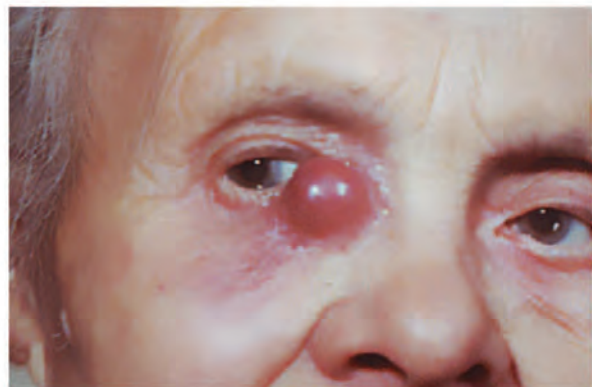Left acute dacryoadenitis
(S-shaped upper lid)



Left severe acute dacryocystitis with lid oedema



Right acute dacryocystitis



Right acute dacryocystitis

Chapter 4

Orbit

Anatomy

The orbit is a quadrilateral pyramidal cavity having a roof, floor, medial and lateral walls. The apex lies posterior at the optic foramen. The base is anterior and is open, being closed by soft tissue. The orbital volume is 30 cm³. The globe occupies only about one fourth of this volume. The lacrimal gland, optic nerve, extraocular muscles, vessels, and nerves of the orbit occupy the remaining space. The largest part is filled with fat.

The Bony Orbit is formed of:

- a. Apex → Posteriorly.
- b. Base → Anteriorly = orbital margin.
- c. Four walls

- **Seven bones share in the formation of the bony orbit:**

Maxilla, palatine, frontal, sphenoid, zygomatic, ethmoid & lacrimal.

- **Orbital apertures:**

They communicate with the brain through the optic foramen and the superior orbital fissure, and with the pterygoid fossa through the inferior orbital fissure.

Structures passing through the orbital apertures:

- Optic foramen: Optic nerve, ophthalmic artery & sympathetic twigs.
- Superior orbital fissure: Superior ophthalmic vein, lacrimal nerve, frontal nerve, trochlear nerve, superior division of oculomotor, nasociliary nerve, inferior division of oculomotor & abducent nerve.

- Inferior orbital fissure: Inferior ophthalmic vein, infraorbital and zygomatic nerve.

Cavernous sinus:

Related structures:

1. Within it: Internal carotid artery, abducent nerve.
2. In its lateral wall: Oculomotor, trochlear, ophthalmic and maxillary nerves.

Communications:

1. Ophthalmic veins.
2. Sphenoparietal sinus.
3. Other cavernous sinus.

Diseases of Orbit

Proptosis

Proptosis or exophthalmos means abnormal protrusion of the eyeball. Normally a line between the middle of the upper and lower orbital margins just touches or misses the corneal apex through the closed eyelids.

Causes:

1. Congenital:

- a) Dermoid cyst of the orbit.
- b) Meningocele.

2. Traumatic:

- a) Retrobulbar hematoma.
- b) Surgical emphysema (air).
- c) Carotid-cavernous fistula.

3. Inflammatory:

a. Acute:

1. Orbital cellulitis, orbital periostitis.
2. Panophthalmitis.
3. Cavernous sinus thrombosis.

b. Chronic:

1. Non-specific inflammation (orbital pseudotumor).
2. Specific: Tuberculosis of the orbit.

4. Tumors:

a. Benign:

1. Haemangioma (the commonest benign orbital tumor).
2. Neurofibroma, osteoma.

b. Malignant:

1. From orbital tissues: Sarcomas.
2. From orbital organs: Malignant lacrimal gland tumors.
3. Intraocular tumors spreading in the orbit e.g. retinoblastoma malignant melanoma.
4. From the surroundings: Tumors of nose and sinuses.
5. Intracranial tumors: Sphenoidal ridge meningioma.
6. Metastatic and blood borne:
 - a) Breast and prostatic carcinoma.
 - b) Neuroblastoma of suprarenal in children.
 - c) Leukemias especially in children.

5. Endocrine:

Dysthyroid eye disease is the commonest cause of proptosis. It may start as unilateral proptosis.

6. Others:

- a) Orbital varix.
- b) Parasitic: Hydatid cyst.
- c) Blood cyst.
- d) Aneurysm.
- e) Bone disease as Paget's disease.

Investigation of proptosis:

History:

The mode of onset, course progress, presence of pain, diplopia ... etc. and history of trauma, systemic diseases or nearby infection.

Examination:

Before considering proptosis, the examiner should first exclude pseudoproptosis which may be due to:

1. Large globe like high myopia especially when unilateral.
2. Buphthalmos.
3. Shallow orbit as in craniofacial anomalies.
4. Contra lateral enophthalmos.

The following must be noted:

1. Signs of inflammation, edema, optic nerve affection, etc.
2. Palpation of orbital swelling for consistency, compressibility
3. Direction of proptosis (anterior, lateral, up, down).
4. Measurement of proptosis: Done by a simple ruler or better by Hertel's exophthalmometer. The distance between the lateral orbital margin and the apex of the cornea is normally between 10-20 mm. A difference of more than 2 mm between the two eyes is significant, particularly if the condition is unilateral.

5. Type of proptosis if present:

- ***Bilateral or unilateral***
- ***Intermittent or recurrent:*** Like orbital varix, inflammatory pseudo-tumor, and recurrent hemorrhage.
- ***Pulsation:***
 - i. Carotid cavernous fistula.
 - ii. Vascular sarcomas.
 - iii. Aneurysms.

Special investigations:

1. Laboratory:

- a) Blood count: To detect leukemias.
- b) Tuberculin for TB, W.R. for syphilis, tests for sarcoidosis
- c) Sedimentation Rate (ESR).
- d) Casoni test for hydatid disease.
- e) Tests for thyroid function: T3, T4, thyroid stimulating hormone (TSH) and thyroid scan.

2. Radiological:

- a) Plain X-ray: Enlarged optic foramen or orbital fissures; calcification, erosion, deviation, etc.
- b) CAT (Computed axial tomography).
- c) MRI (Magnetic resonance imaging).
- d) Ultrasound (US).
- e) Carotid Angiography.

3. Biopsy:

Fine needle aspiration or excision biopsy is usually needed in orbital tumors.

I- Traumatic Proptosis

1. Retrobulbar hemorrhage: May follow trauma, orbital fractures or retrobulbar injection.
2. Surgical emphysema: Following trauma to the ethmoid sinuses, air passes into the orbit and subcutaneous tissues of the eyelids.
It increases with blowing of the nose and gives the feeling of soft crepitations in the lid.
3. Arterio-venous fistula: Due to severe head trauma leading to rupture of the internal carotid artery as it passes in the cavernous sinus with severe rise of venous pressure.

Clinical picture:

1. Redness.
2. Chemosis.
3. Dilated retinal veins.
4. Papilloedema.
5. Ophthalmoplegia (paralysis of the extraocular muscles).
6. Proptosis which is typically pulsatile with audible bruit.

II- Inflammatory Proptosis

1. Orbital cellulitis:

Acute suppurative inflammation of the orbital soft tissues.

Etiology:

- Spread of infection from the nasal sinuses (sinusitis).
- Blood borne infections.

Causative organisms:

Usually staphylococci, streptococci, pneumococci and rarely fungi.

Clinical picture:

Symptoms:

1. Pain.
2. Headache.
3. Fever.
4. Malaise especially in children.
5. Vision decreases late if optic neuritis develops.

Signs:

1. Marked edema and redness of lids and conjunctiva.
2. Proptosis.
3. Limited ocular motility.
4. An orbital abscess may form and point in the lower fornix or into the skin near the orbital margin.

Complications:

Corneal ulceration due to exposure and hypoesthesia.

Differential Diagnosis: See table (1).

Treatment:

1. Systemic antibiotics.
2. Hot fomentation.
3. Local antibiotics (peribulbar & retrobulbar injection).
4. If an abscess forms: Incision and evacuation of pus.

2. Cavernous sinus thrombosis (C.S.T.)

Etiology: Thrombosis of the cavernous sinus may be due to spread of infection from:

1. The face because the angular vein communicates with the ophthalmic vein.

2. The orbit and globe through the ophthalmic veins.
3. The mouth, pharynx, and nasal sinuses through the pterygoid plexus.
4. The middle ear and mastoid through the petrosal sinuses.
5. Blood-borne.

Clinical Picture:

Symptoms:

- a. General: Marked fever, malaise, rigors and cerebral symptoms.
- b. Local:
 - Pain.
 - Limited ocular movement.
 - Vision is good at the beginning then it starts to drop due to optic neuritis.

Signs:

- Edema and congestion of lids and conjunctiva.
- Proptosis: At first it is unilateral then it becomes bilateral when the condition spreads to the other sinus.
- Limited eye movement.
- Tenderness and edema of the mastoid region.
- Fundus: Engorged veins, papilloedema or papillitis.
- The earliest signs of affection of the other sinus are paralysis of the lateral rectus (due to 6th nerve palsy) and mastoid edema.

Treatment: The condition is very serious and could be fatal if not well treated.

1. Prophylactic treatment of the sources of infection.
2. Massive antibiotics and anticoagulants.

3. Panophthalmitis: Refer to chapter of uveal tract.

Table 1: Differential diagnosis of inflammatory proptosis

	Endophthalmitis	Panophthalmitis	Orbital cellulitis	Cavernous sinus thrombosis
General signs and symptoms	Mild	+to++	+ to ++	++++
Laterality	Usually unilateral	unilateral	unilateral	Early: unilateral Late : Bilateral
Vision	Early PL Late no PL	No PL	Early good	Early good
Yellow reflex	+ve	+ve	-ve	-ve
Proptosis	-ve	+ve	+ve	+ve
Ocular movement	Normal	Limited	Limited	Limited
Specific features	Keratic precipitates, hypopyon, corneal abscess			Mastoid edema, dilated veins of lids and conjunctiva
Treatment	- Antibiotics - Vitrectomy in early cases - Evisceration in severe cases		Antibiotics ± drainage of orbital abscess	Anticoagulants + antibiotics + neurosurgical treatment.

+: Moderate

++: Severe

+++: Very severe

+ve: Present

-ve: Absent

Orbital periostitis

Inflammation of the orbital periosteum is most often due to injuries or extension of infection from the neighboring parts.

1- Periostitis at the orbital margin:

- a) Pain and swelling at the orbital margin.
- b) Swelling and redness of the eyelids and conjunctiva.
- c) An abscess may form at the site of the inflammation.

2- Deep periostitis:

- a) Marked general constitutional symptoms.
- b) Deep-seated pain in the orbit.
- c) Swelling and redness of the eyelids and conjunctiva.
- d) Proptosis of the eyeball which may be deviated to one side.

Complications:

1. Orbital cellulitis.
2. Superior orbital fissure syndrome.
3. Sinus formation may occur (e.g. T.B).
4. Spread of infection to the brain (meningitis, C.S. thrombosis).

Treatment:

1. Systemic antibiotic therapy.
2. If abscess forms —————> incision.
3. Exploratory orbitotomy may be necessary (deep periostitis).

III- Endocrine Exophthalmos

Dysthyroid ophthalmopathy (Thyroid eye disease)

Clinical features and complications:

1. Eyelid signs.
2. Infiltrative ophthalmopathy.
3. Exophthalmos.
4. Extraocular muscle affection.
5. Optic neuropathy.

1. Eyelid Signs:

- a. Upper lid retraction (*Darlymple' sign*), which gives a staring look.
- b. Upper lid lag (*Von Graeve' sign*). The upper lid does not follow the eyeball when looking downward.
- c. Infrequent blinking (*Stellwag' sign*).

2. Infiltrative Ophthalmopathy:

- a. Proliferation of orbital fat and connective tissue with retention of fluids, accumulation of mucopolysaccharides, and cellular infiltration by lymphocytes and plasma cells.
- b. Enlargement of the extraocular muscles due to increased mucopolysaccharides and edema with subsequent degeneration of the muscle fibers, fibrosis, weakness and restricted ocular movements.

Clinical signs:

- a. Injection, hyperemia, and chemosis of the conjunctiva.
- b. Edema of the eyelids.

3. Exophthalmos:

Dysthyroid eye disease is the commonest cause of both bilateral and unilateral proptosis. The condition may be very severe leading to exposure of the cornea with severe corneal ulceration and blindness.

4. Extraocular muscle affection:

In the form of weakness, and restricted movements in various directions (up, out, down, in).

5. Optic neuropathy:

Symptoms:

- a. Slowly progressive impairment of central vision.
- b. Defective red-green color appreciation.

Signs:

- a. Ophthalmoscopy:
 - i. Disc edema and chorioretinal folds.
 - ii. Optic atrophy in advanced cases.
- b. Visual field defects: Central or paracentral scotoma with or without nerve fiber bundle defect. This may be confused with primary open angle glaucoma.
- c. An afferent pupillary defect, an important sign of optic nerve involvement.

Management of thyroid eye disease

1. Local lubricants, dark glasses, treatment of corneal complications due to exposure.
2. Systemic steroids in early cases with painful exophthalmos.
3. Radiotherapy when steroids are contraindicated or ineffective.

4. Surgical:

- a. Orbital decompression in cases of severe proptosis (removal of one or more of the orbital walls).
- b. Extraocular muscle surgery when there is diplopia in the primary or reading position.

Table 2: Types of exophthalmos

	Thyrotoxic Exophthalmos	Thyrotropic Exophthalmos
Cause	Increased thyroxin	Increased Thyroid stimulating hormone or E.P.S
Pathogenesis	Spasm of Muller's muscles	Increased orbital contents
Age	Adults	Middle aged
Sex	Females	Males more
Basal Metabolic rate	Elevated	Normal high or low
Muscles	Normal	Ophthalmoplegia
Course	Benign	Malignant (corneal damage)
Onset	Rapid	Insidious
Systemic manifestations	Present	Absent
Exophthalmos	Mild & Reducible	Severe & irreducible

Enophthalmos

Enophthalmos is retraction of the globe into the orbit (opposite to proptosis).

Causes:

1. Senile: Absorption of orbital fat.
2. Post-traumatic.
3. Post-operative.
4. Post-inflammatory.
5. Horner's syndrome (ptosis, miosis, enophthalmos, anhydrosis).

Orbital Pseudotumor

- Non-specific inflammation involving the orbital tissues.
- There is no recognizable cause e.g. infection, FB or systemic disease.

Differential Diagnosis:

1. Orbital cellulites.
2. Ruptured dermoid cyst.
3. Lymphangioma.
4. Rhabdomyosarcoma.

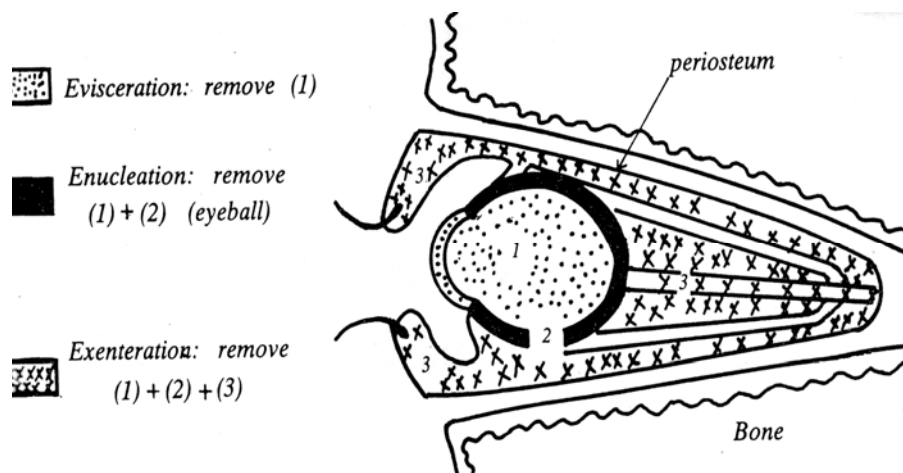
Cause:

1. Unknown.
2. It may be orbital immune reaction.

Treatment:

1. Oral corticosteroids with rapid and dramatic response within 2-3 days.
2. Radiotherapy.
3. Immunosuppressive agents in refractory cases.

Operations on the Orbit



1. Orbitotomy:

To remove orbital tumors or to induce orbital decompression in severe thyroid exophthalmos.

2. Evisceration:

Evacuation of the contents of the eyeball after taking the patient's consent. It is indicated in cases of endophthalmitis and panophthalmitis.

3. Enucleation:

Excision of the eyeball after taking the patient's consent usually followed by insertion of an artificial eye. Enucleation is contraindicated in cases of infection (panophthalmitis).

Indications:

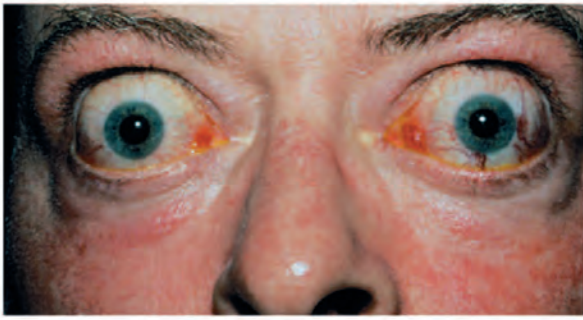- To save the patient's life: Intraocular tumors (retinoblastoma and malignant melanoma).
- To save the other eye: In severely traumatized eyes to avoid sympathetic ophthalmia.
- To stop pain or improve appearance: Severe painful eye as in absolute glaucoma or disfigured eye.

4. Orbital exenteration:

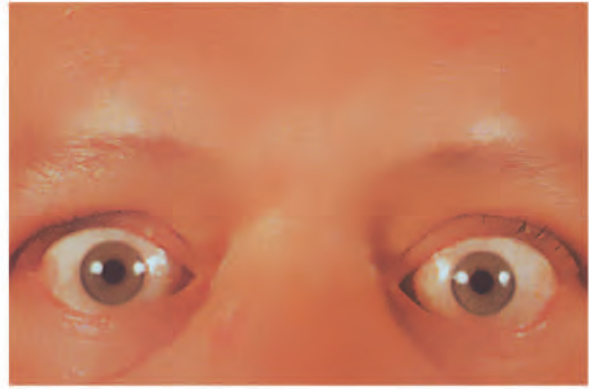
Where the orbital periosteum and all the orbital contents, lids and conjunctiva are removed.

Indications:

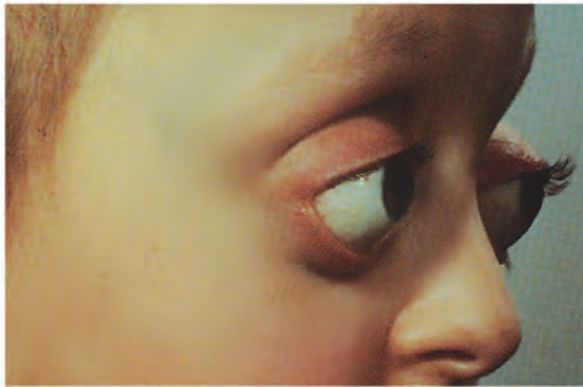- a) Malignant orbital tumors.
- b) Malignant tumors of the eye spreading into the orbit or malignancy of lids or conjunctiva.
- c) Contraindicated when there is general metastases or if the orbital periosteum is invaded by the tumor.



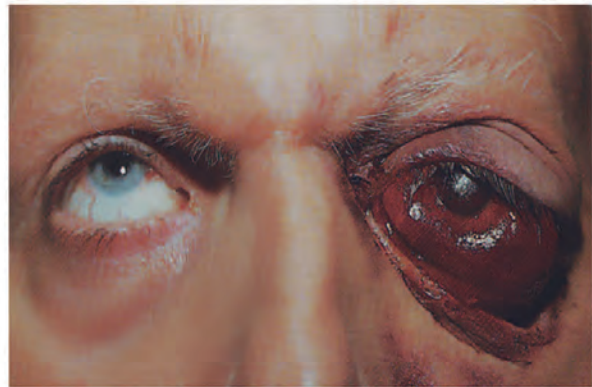Thyrotoxic exophthalmos



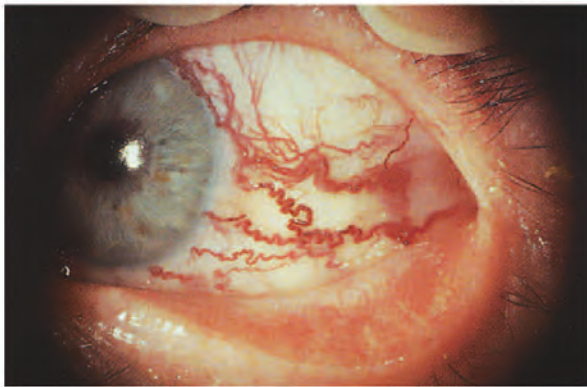
Endocrine ophthalmopathy



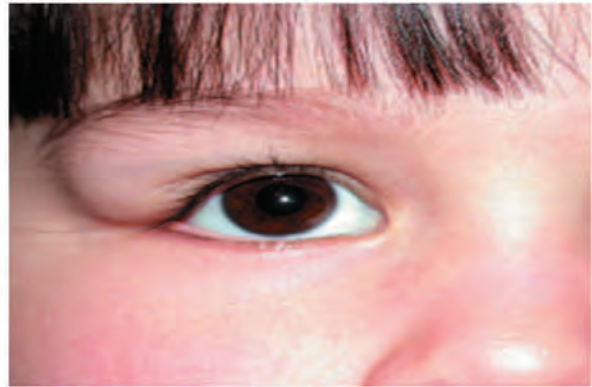Bilateral proptosis (Lateral view)



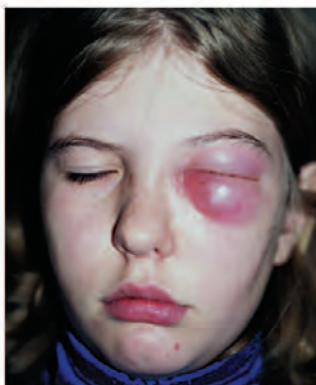Retrobulbar hematoma



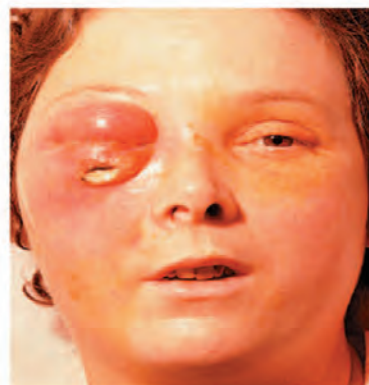Carotid-Cavernous sinus fistula



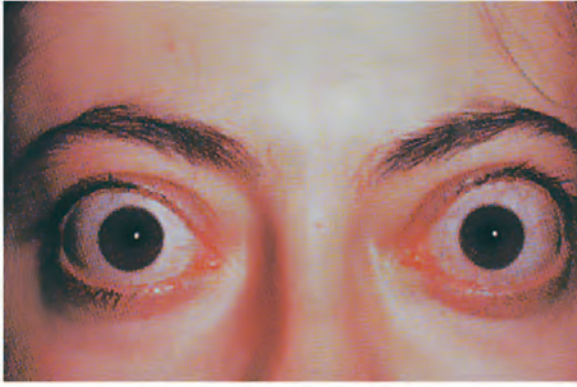Dermoid Cyst



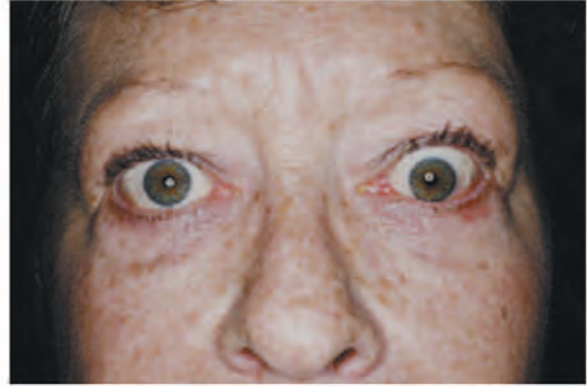Orbital cellulitis



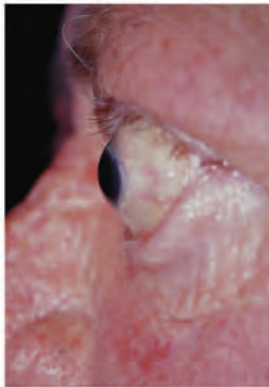
Orbital cellulitis with orbital abscess



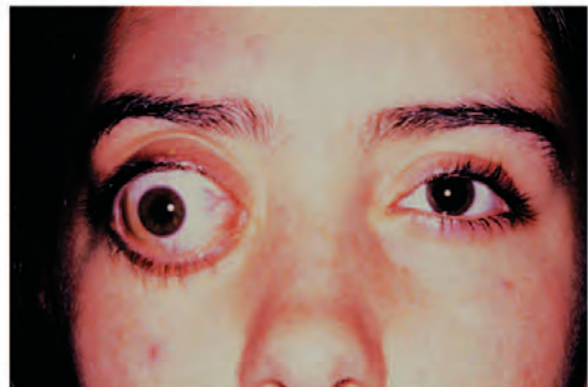
Lid retraction



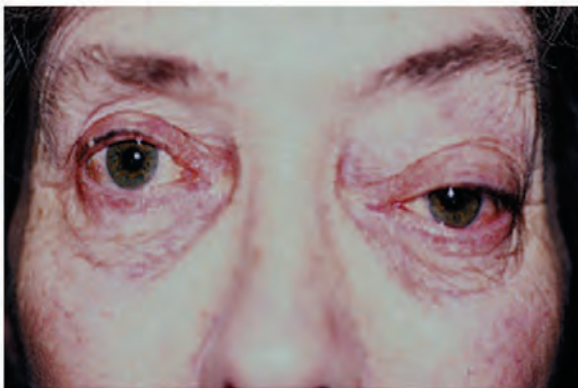
Asymmetrical lid retraction



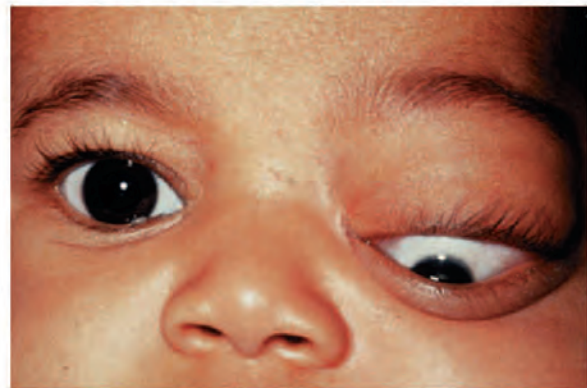Proptosis (lateral view)



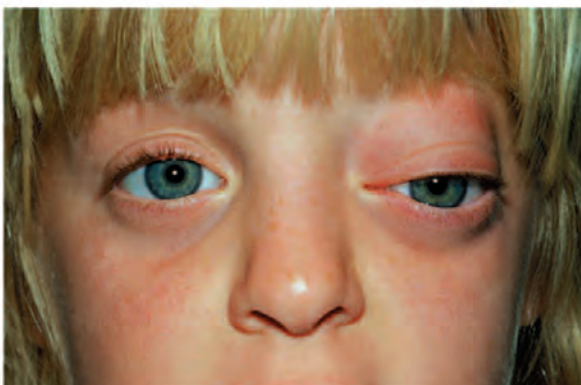Right axial proptosis



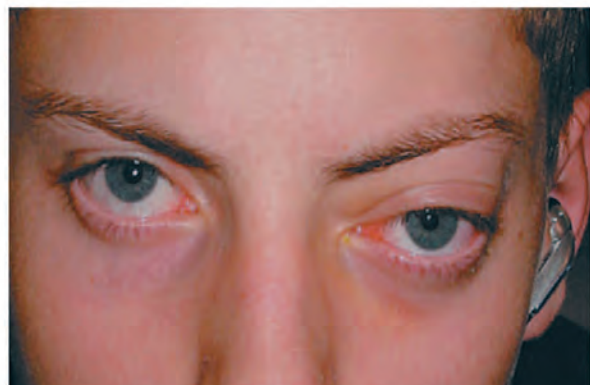Lateral displacement of the left globe
(by ethmoidal mucocele)



Down Displacement of left globe (By orbital cyst)



Superomedial orbital swelling displaces the left globe
down and out



Frontal mucocele causing a superior anterior orbital
swelling, proptosis and inferior displacement of the
left globe

Chapter 5

Conjunctiva

Anatomy of the Conjunctiva

Gross Anatomy

The conjunctiva is a thin mucous membrane lining the posterior surface of the lids, from which it is reflected on to the anterior aspect of the eyeball as far as the corneo-scleral junction. At the lid margin the conjunctiva is continuous with the skin and at the corneal margin it becomes structurally continuous with the corneal epithelium. It thus forms a potential space, called the conjunctival sac, which is open externally at the palpebral fissure and only closed when the eyes are shut.

The conjunctiva may be divided for descriptive purposes into the following regions:

1. The Palpebral Conjunctiva: This lines the under surface of the eyelids and extends from the intermarginal sulcus of the lid margin up to fornix. It may be subdivided into the following zones:

- (a) The marginal conjunctiva commences at the grey line of the lid margin and merges into the subtarsal groove.
- (b) The tarsal conjunctiva is thin, transparent and very vascular. It is closely adherent to the tarsal plate. The meibomian glands can be seen through the normal tarsal conjunctiva as yellowish streaks.
- (c) The orbital conjunctiva lies between the proximal border of the tarsal plate and the fornix. It is in relation to the palpebral muscles of Muller.

2. The Fornix Conjunctiva: It is a continuous circular cul-de-sac formed by the reflection of the palpebral conjunctiva on to the anterior

portion of the eyeball. It is only interrupted medially by the plica semilunaris and the caruncle (vide infra). The conjunctiva of the fornix is richly supplied with blood vessels and contains the accessory lacrimal glands of Krause. It forms a loose fold, thus ensuring freedom of movement to the eyeball.

3. The Bulbar Conjunctiva: This covers the anterior portion of the eyeball as far as the corneo-scleral junction. The conjunctiva is thin and transparent showing the white sclera through it. The bulbar conjunctiva is at first loosely adherent to the underlying tissues, namely, the tendons of the recti muscles covered by the Tenon's capsule, but 3 mm. from the corneal margin it becomes firmly adherent and blends with the Tenon's capsule.

4. The Plica Semilunaris: This is a semilunar fold of the conjunctiva situated at the inner canthus with its free concave border facing towards the cornea. The plica semilunaris corresponds to the third eyelid or the nictitating membrane of the lower vertebrates but in man it is only a vestigial structure.

Histology:

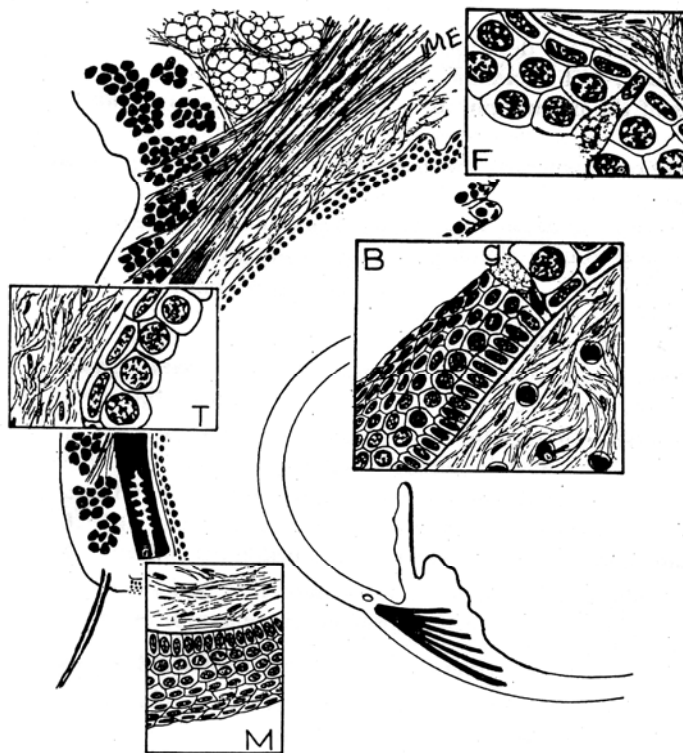
The conjunctiva consists histologically of two layers:

1. The epithelial layer.
2. The substantia propria.

1-The Epithelium: It varies in structure according to the region

- (a) The Marginal Conjunctiva: Non-keratinized stratified squamous epithelium.
- (b) The Tarsal Conjunctiva: Two layers of cells consisting of a superficial layer of cylindrical cells and a deep layer of cubical cells.
- (c) The Fornix Conjunctiva: Three layers of cells comprising superficial cylindrical, middle cubical and deep flatter cells.

- (d) The Bulbar Conjunctiva: The epithelium increases in thickness from the fornix until at the limbus it becomes non-keratinized stratified squamous epithelium.
- (e) The Plica Semilunaris: 8-10 layers of epithelial cells with cylindrical cells in the deepest layers.



—The microscopic anatomy of the conjunctiva.
B.—Bulbar conjunctiva.
F.—Fornix conjunctiva.
G.—Goblet cell.
M.—Marginal conjunctiva.
T.—Tarsal conjunctiva.

In most parts of the conjunctival epithelium, there are large translucent mucus-secreting cells, called the goblet cells. They are most numerous in the fornices and in the plica semilunaris, but are absent near the lid margin and near the limbus.

2. The Substantia Propria: It is the connective tissue underlying the surface epithelium. The stroma comprises the following layers:

- (a) The Superficial adenoid layer: This is made up of an extremely fine fibrous network, profusely infiltrated with lymphocytes among which few mast cells and histiocytes may be found.
- (b) The Deep fibrous layer: It is a thick meshwork of collagenous and elastic fibers. This layer is absent over the tarsal region.

Blood Supply of the Conjunctiva:

Arteries: The arterial supply to the conjunctiva is derived from two main sources:

1. The posterior conjunctival arteries: They arise from the perforating arteries which come from the medial and lateral palpebral branches of the ophthalmic and the lacrimal arteries respectively. They supply the whole conjunctiva except an area 4 mm wide around the limbus.
2. The anterior conjunctival arteries: They are the forward continuation of the anterior ciliary arteries. They supply an area of conjunctiva 4 mm wide around the limbus.

Veins: The greater part of the venous drainage of the conjunctiva, except the circumcorneal zone, follows their corresponding arteries to the tarsal venous plexus of the eyelids. The veins of the circumcorneal region drain into the anterior ciliary veins. Eventually, these veins empty their blood into the ophthalmic veins.

Lymphatics: The lymph vessels from the lateral half of the conjunctiva drain mainly into the pre-auricular lymph nodes, whereas those from the medial half drain mainly into the submandibular lymph glands.

Nerve Supply

The greater part of the conjunctiva is supplied by branches from the sensory nerves of the eyelids, namely:

1. The supratrochlear and the supraorbital nerves (branches of the frontal branch of the ophthalmic division of the trigeminal nerve).
2. The lacrimal nerve (a branch of the ophthalmic division of the trigeminal nerve).
3. The infraorbital nerve (a branch of the maxillary nerve).
4. The infratrochlear nerve (a branch of the naso-ciliary nerve).

The circumcorneal zone of the conjunctiva is supplied by branches from the anterior ciliary nerves (branches of the long ciliary nerves which come off the naso-ciliary nerve).

Defensive Mechanisms against Conjunctival Infection

1. **Secretory:** Micro-organisms are mechanically washed out by the flow of tears. Lysozyme, being a normal constituent of the lacrimal fluid, inhibits the multiplication of most conjunctival micro-organisms.
2. **Epithelial barrier:** The desquamation of the conjunctival epithelium and its rapid reformation is a barrier against bacteria.
3. **Lymphatic barrier:** There is a lot of lymphoid tissue in the conjunctiva.

Diseases of Conjunctiva

Pathological manifestations of conjunctival inflammations:

- 1. Irritation:** Discomfort, itching, burning and foreign body sensation.
- 2. Discharge:** Depending on the etiology and severity of inflammation, the discharge may be:
 - a. Serous (watery).
 - b. Mucoïd.
 - c. Mucopurulent.
 - d. Purulent.
- 3. Chemosis:** Edema of subepithelial connective tissue.
- 4. Hyperemia:** Conjunctival injection due to dilatation of the posterior conjunctival vessels sweeping forwards from the fornices.
- 5. Follicles:** Are focal collections of lymphocytes in the substantia propria of the conjunctiva. They are most prominent in the inferior fornix as gelatinous elevations. They are commonly caused by:
 - a) Viral infections: As adenovirus, herpes or molluscum contagiosum.
 - b) Chlamydia: Trachoma and adult inclusion conjunctivitis.
 - c) Drug reaction: Atropine, Epinephrine, and glaucoma medications.
- 6. Papillae:**

Are a non-specific response to chronic irritation leading to epithelial proliferation with a vascular core. They are seen on the superior tarsal conjunctiva as multiple red bumps each with a central core of vessels. They are commonly caused by:

 - a) Chronic infections.
 - b) Allergy.

7. Giant papillae:

The size of the papillae is usually restricted by the fibrous septa attaching the conjunctiva to the underlying tarsus. With severe and chronic inflammation, these septa rupture and the papillae coalesce to form giant papillae. They are commonly caused by:

- a) Prolonged contact lenses wear (giant papillary conjunctivitis).
- b) Vernal keratoconjunctivitis (spring catarrh).

8. Membrane:

Damage of the conjunctival vessels and epithelial surface by severe inflammation can cause exudation of fibrin, inflammatory cells, necrotic cells and serous fluid, forming a dirty grayish membrane on the surface.

Removal of a membrane produces a raw bleeding surface; they usually lead to adhesions between different parts of the conjunctiva or between the conjunctiva and the cornea. These adhesions are called symblepharon.

The most common causes are:

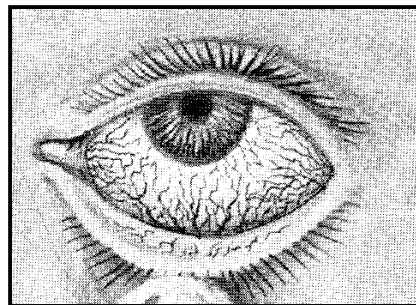
- a) Diphtheric conjunctivitis.
- b) Alkali or acid burns.
- c) Severe viral infections.

9. Pseudomembranes:

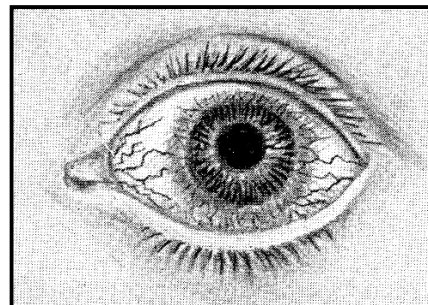
Formed by condensation of discharge and exudates over the conjunctival surface. They are easily removed leaving an intact, epithelial surface.

Table (3): Difference between conjunctival and ciliary injection

	Conjunctival injection	Ciliary injection
Blood vessels	• Bright red in color	• Pink
	• Tortuous and dilated vessels	• Fine, straight & radiate from the cornea
	• Superficial	• Deep
	• Moves freely with moving conjunctiva	• Cannot move with conjunctiva
	• More marked at the fornix	• More marked at the limbus
	• Vessels are seen (not blurred)	• Vessels are blurred
	• Vessels are constricted by adrenaline	• Not constricted by adrenaline
	• Form posterior Conjunctival vessels	• Form anterior ciliary vessels.
Causes	• Conjunctivitis	• Keratitis • Corneal ulcer • Iridocyclitis



Conjunctival Injection



Ciliary Injection

Conjunctivitis

A. Mucopurulent Conjunctivitis (MPC)

Causative Agents: The commonest organisms are

1. Haemophilus Aegypticus (Koch-Week's bacillus): Causes epidemics in April, May, September, and October.
2. Staphylococci, streptococci and pneumococci.

Clinical Picture:

1. Lid edema.
2. Hyperemia of the conjunctiva (conjunctival injection).
3. Mucopurulent discharge formed of a mixture of mucus, tears, leucocytes and serum.
4. Gluing of lashes by the discharge especially in the morning on waking up.
5. Conjunctival edema (chemosis).
6. Petechial hemorrhage in severe cases.

Complications:

Corneal ulcers, usually superficial crescentic and marginal.

Management

A. Prevention:

1. Combat flies and good personal hygiene.
2. Protect the fellow eye in unilateral cases.
3. Patients must use separate towels.

B. Treatment:

1. Frequent washing with sterile water or boric acid lotion 4% to remove discharge.
2. Hot fomentations.

3. Local antibiotic eye drops used frequently e.g. Sulfacetamide 10%, Chloramphenicol, Gentamycin, Tobramycin, Quinolones & Fucidic acid.
4. Antibiotic ointment as Terramycin or Tobramycin at night:
 - a) Long acting effect due to slow release of the antibiotic.
 - b) Prevents gluing of lashes.
 - c) Allows free exit of discharge.
5. Systemic antibiotics in severe cases.
6. Dark glasses for cases with photophobia.
7. No bandage should be used as it accumulates the discharge and allows more multiplication of the organism.

B. Purulent Conjunctivitis

Causative Agents:

1. Gonococci: 60-80% of cases.
2. Staphylococci, streptococci and mixed infections.

Clinical Forms:

I- Adult Type: The organism may reach the eyes through flies, dust, contaminated towels or through the genitals.

Clinical Picture and Stages:

1. Incubation period: Few hours to 3 days.
2. Stage of infiltration:
 - a. Lid edema and tenderness.
 - b. Marked conjunctival edema.
 - c. Marked hyperemia: Conjunctival injection, subconjunctival hemorrhage.

- d. Watery or mucoid discharge.
 - e. Enlarged tender pre-auricular lymph nodes may be detected.
3. Stage of discharge:
- a. Decreased lid edema, the lids are tense and may be painful.
 - b. Decreased edema with hyperemia and papillae formation at the palpebral conjunctiva (velvet-like).
 - c. Profuse purulent discharge.

Fate and complications:

- 1. Purulent conjunctivitis disappears spontaneously within 2 weeks or after treatment.
- 2. Chronicity: Slight swelling of lids with residual redness of lids, palpebral and bulbar conjunctiva.
- 3. Corneal ulcers:
 - a. The most important complication.
 - b. May be central, marginal or may form ring ulcers.
 - c. May perforate causing panophthalmitis, dense corneal scars or anterior staphyloma.
- 4. Iridocyclitis.

Management

A. Prevention:

- 1. Combat flies, personal hygiene, and healthy sex-habits.
- 2. Protect the fellow eye in unilateral cases, use prophylactic antibiotic eye drops.
- 3. Patients should use separate towels and bed sheets that should be changed and frequently boiled.
- 4. Careful disinfection of infected fingers.

B. Treatment:

1. Frequent washing and removal of discharge with sterile lotions as boric acid lotion 4% or warm water.
2. Local antibiotic eye drops (broad spectrum antibiotics) used frequently (every 5 minutes for an hour, then every hour for 48 hours, then 4 times a day for 10 days). The frequency depends on the severity of the infection.
3. Antibiotic eye ointment at night.
4. Systemic antibiotics: Single injection of Cefotriaxone for gonococcal cases.
5. Dark glasses for cases with photophobia.
6. Local Atropine in cases with corneal ulcer or iritis.
7. No bandage whenever there is discharge.

II- Ophthalmia neonatorum:

Definition: It is any form of conjunctivitis occurring in the first month of life. Any discharge from the eye of a newborn infant is suspicious since tears are not secreted at this early date.

The condition should be differentiated from congenital dacryocystitis, which is unilateral and pressure on the lacrimal sac yields regurge of pus.

Etiology:

Infectious: Ocular contact with contaminated maternal passages or towels.

- a) Bacterial: Gonococci, staphylococci, streptococci or pneumococci.
- b) Viral: Herpes simplex and adenoviruses.
- c) Chlamydia.

Diagnosis:

- a) Clinical picture of purulent conjunctivitis.
- b) Conjunctival smear: May show bacteria, inclusion bodies in chlamydial and herpes infections.
- c) Immunofluorescent tests for chlamydia.

Management:

Prevention:

1. Treatment of the mother before labor especially herpetic cervicitis.
2. Washing of the body of the baby from above downward.
3. Penicillin or broad spectrum antibiotic eye drops are instilled in the eyes after birth for 1 week.

Treatment:

1. Local antibiotic eye drops used frequently (Penicillin or broad spectrum antibiotics).
2. Frequent removal of discharge.
3. Antibiotic ointment at night or as frequently as required
4. Systemic antibiotics in severe cases.
5. Local Atropine ointment in cases with corneal involvement or iritis.

C. Membranous (Diphtheric) Conjunctivitis

Causative Agent: *Corynebacterium diphtheriae*. It is a rare condition since children are now effectively immunized against diphtheria. Membranous conjunctivitis affects non-immunized children.

Clinical Picture and Stages:

Incubation period: 12 hours to 3 days.

➤ **Systemic manifestations:**

1. Infection of the throat or nasopharynx.

2. Constitutional symptoms: Fever and malaise.

➤ **Ocular manifestations:**

a. Stage of infiltration: (5-10 days)

1. Lid edema, redness, tenderness and induration.
2. Conjunctival edema covered with yellowish exudation.
3. Scanty mucopurulent discharge.
4. There is a true membrane, grayish yellow in color, which may be patchy, or covers the whole palpebral conjunctiva.

b. Stage of discharge:

1. Marked hyperemia of the conjunctiva.
2. Purulent blood stained discharge containing pieces of the sloughed membrane.
3. When the membrane separates it leaves a septic granulation tissue that exudes thick yellow pus.

Fate and complications:

a. Local complications:

- Cicatrization: The raw conjunctival surfaces heal together by fibrosis resulting in the following:
- Lids: Trichiasis, entropion, and symblepharon.
- Lacrimal system: Closure of ducts and fibrosis of the accessory lacrimal glands leading to xerosis.
- Conjunctiva: Xerosis, symblepharon and pseudopterygium.
- Cornea: Ulcers, xerosis, and vascularization.

b. General complications:

Complications are mostly due to the diphtheritic exotoxin

- a) Toxic myocarditis and heart failure.
- b) Respiratory failure.

- c) Toxic nephritis with albuminuria.
- d) Neuropathy and paralytic manifestations: Paralysis of accommodation, paralytic squint, and other neurologic manifestations.

Prevention:

1. Immunization against diphtheria.
2. Isolation of the patients and notification of the health authorities.

Treatment:

1. Complete bed rest.
2. Anti- diphtheric serum 40,000-60,000 U; Can be repeated every 12 hours to neutralize the circulating toxin.
3. Systemic IM Penicillin injections.
4. Local antibiotic eye drops (Penicillin 10000 u/ml).
5. Local anti- diphtheric serum eye drops.
6. Antibiotic ointment applied between the palpebral and bulbar conjunctiva to avoid symblepharon.
7. Local Atropine ointment in cases with corneal ulcers or iritis.

D. Viral Conjunctivitis

Causative Agents:

1. Adenovirus: Causes epidemic keratoconjunctivitis (EKC). It takes an epidemic form with many cases occurring over a short period of time. It spreads by droplet infection and may be accompanied by sore throat.
2. Herpes simplex, enterovirus and newcastle disease viruses.
3. Acute viral infections: Measles, influenza and mumps may be associated with conjunctivitis.

Clinical Picture:

1. Hyperemia of the conjunctiva.
2. Discharge is usually watery, but may be purulent or mucopurulent.
3. Photophobia.
4. Conjunctival edema.
5. Sudden onset of subconjunctival hemorrhage is characteristic of acute hemorrhagic conjunctivitis.
6. Follicular conjunctivitis.
7. Preauricular lymph nodes are enlarged and tender.
8. Punctate epithelial keratitis in (epidemic keratoconjunctivitis).
9. Lid vesicles in herpetic cases.

Fate:

1. Self-limited, resolving in 7-14 days.
2. Affection of the fellow eye a few days after the first eye.

Prevention:

1. Protect the fellow eye in unilateral cases.
2. Patient should use separate towels and bed sheets that should be boiled.

Treatment:

1. Topical Acyclovir (Zovirax) eye ointment.
2. Local Atropine in cases with corneal involvement.

Chronic Conjunctivitis

1. Chronic Catarrhal Conjunctivitis:

Etiology:

- a) Sequelae of acute conjunctivitis.
- b) General irritations with dust, smoke, wind or heat.
- c) Local irritation with rubbing lashes.
- d) Errors of refraction.

Clinical picture:

1. Irritation: Discomfort, itching, burning and foreign body sensation.
2. Little discharge.
3. Hyperemia of the fornices.

Treatment:

1. Remove the cause.
2. Astringent and vasoconstrictor eye drops (zinc sulphate).

2. Angular Conjunctivitis:

Etiology:

Morax Axenfeld diplo-bacillus, which secretes a proteolytic enzyme that macerates the epithelium.

Clinical picture:

- a. Irritation: Discomfort, itching, burning and foreign body sensation.
- b. Little white foamy discharge especially at the angles.
- c. The inner and outer canthi and nearby conjunctiva are affected due to deficiency of tear lysozyme in these areas.
- d. Hyperemia (conjunctival injection).
- e. Excoriation of the skin, which is painful and fissured.

Complications:

Corneal ulcer:

- a. Marginal ulcer
- b. Hypopyon ulcer

Treatment:

1. Neutralize the action of the proteolytic enzyme by zinc sulfate eye drops or lotion.
2. Tetracycline eye ointment.
3. Oral Tetracycline or Erythromycin in resistant cases.
4. Sodium bicarbonate 2-3% eye lotion to remove the discharge.

3. Follicular conjunctivitis:

Conjunctivitis with follicle formation, commonly caused by:

a. Viral infections:

Adenovirus, herpes, molluscum contagiosum

1. Follicles are more in the inferior fornix.
2. Cornea is free, no scarring.

b. Chlamydia: trachoma and adult inclusion conjunctivitis

c. Drugs (conjunctivitis medicamentosa): Atropine, Epinephrine, glaucoma medications.

Diagnosis: 1. History of use of drug.

2. Itching.
3. Follicles are in the inferior fornix.
4. Rapid cure once the drug is stopped.

d. Folliculosis:

Diagnosis: 1. Affects children.

2. Associated with enlarged tonsils or adenoids.

3. Follicles are arranged in parallel rows in the inferior palpebral conjunctiva.
4. Chronic course.
5. Cornea is free.
6. No scarring.

The condition improves by treatment of the cause.

Trachoma (Granular Conjunctivitis)

It is a chronic contagious inflammation characterized by:

1. Subepithelial cellular infiltration,
2. Formation of follicles and papillae,
3. Formation of pannus and
4. Healing by cicatrization.

It is the greatest single cause of preventable blindness in the world.

Trachoma is endemic in Egypt affecting more than 80% of the population.

Etiology:

Causative agent is *Chlamydia trachomatis* with the following characters

1. Large-sized obligate intracellular organism.
2. Contains both DNA and RNA.
3. Has a cell wall.
4. Susceptible to Tetracycline, Erythromycin and Sulphonamides.
5. Produces intracellular basophilic inclusion bodies in epithelial cells.
6. No solid immunity so recurrences are common.

Mode of infection:

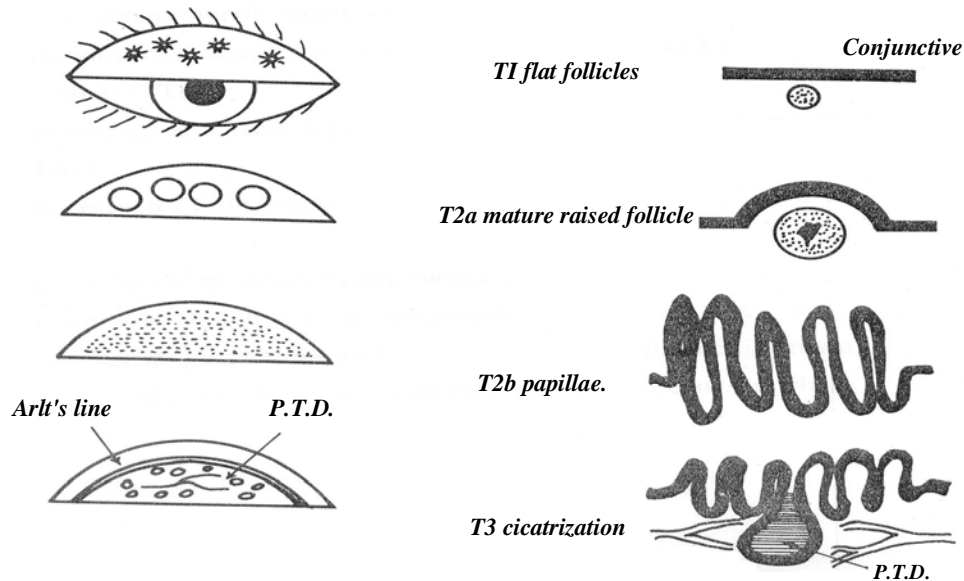
1. Through conjunctival discharge carried by fingers, towels and flies.
2. Common in low socioeconomic areas and occurs at childhood in endemic areas.

Clinical Picture:

▪ **Conjunctival Manifestations of Trachoma (simplified MacCallan's Classification):**

The disease affects mainly the upper palpebral conjunctiva

1. Cellular infiltration occurs around the invading organism, leading to the formation of subepithelial small pin point grayish follicles. These follicles are not raised above the surface, non expressible and are called immature follicles (T_I).
2. The follicles enlarge and become pinkish, raised above the surface and are expressible (T_{IIa}).
3. Papillae are formed (T_{IIb}) where they are soft, vascular and pinkish in color.
4. Healing occurs by cicatrization (T_{III}), which may take the form of lines, patches, or a dense white line at the sulcus subtarsalis called Arlt's line.
Post trachomatous degenerations (PTDs) may occur in the conjunctival crypts between adjacent papillae. Calcification may occur in these degenerate areas leading to sandy white calcified spots called post trachomatous concretions (PTCs).
5. Complete healing is the end point where cicatrization is complete with no follicles or papillae and absence of inclusion bodies in conjunctival scraping.



Stages Conjunctival Trachoma

▪ Corneal Manifestations of Trachoma:

a. Superficial keratitis:

- Numerous epithelial erosions involving the upper part of the cornea which shows positive staining with fluorescein.

b. Corneal follicles:

1. Small rounded grayish areas in the upper cornea.
2. Subepithelial lymphoid infiltrations (Herbert's rosettes).
3. On healing they leave depressed pits (Herbert's pits) giving a serrated appearance to the lower edge of the pannus.

c. Trachomatous pannus:

1. Superficial vascularization and lymphoid infiltration of the upper cornea.
2. The vessels run subepithelially between the limbal follicles.
3. The patient may complain of pain, lacrimation, photophobia and blepharospasm.

Course:

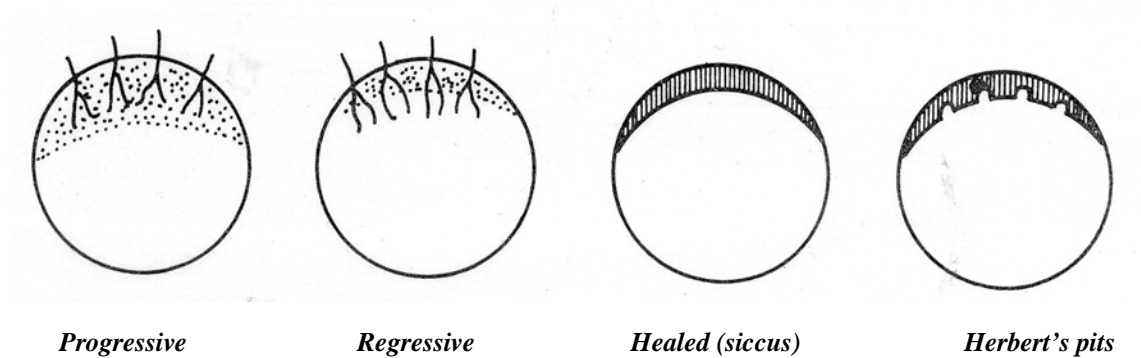
1. Progressive pannus:

Vessels are parallel and directed vertically downward extending to a level forming a horizontal line. Infiltration precedes vascularization.

2. Regressive pannus:

Infiltration regresses and vessels narrow.

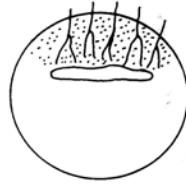
3. Healed pannus:

**Trachomatous Pannus***Fate:*

1. Complete resolution leaving a clear cornea if the basement membrane is not destroyed.
2. A permanent opacity if BM is destroyed (pannus siccus).

d. Corneal ulcers:

1. Typical trachomatous ulcer: Superficial, linear, horizontal ulcers at the lower edge of the pannus. They are chronic, spread slowly and secondary infection is not common. They heal by facet formation.
2. Marginal or central ulcers: Unrelated to the pannus.
3. Ulcers due to trachoma complications: As trichiasis and PTDs.



Trachomatous ulcer

e. Xerosis: due to:

1. Atrophy of goblet cells.
2. Obstruction of the lacrimal ducts.
3. Fibrosis of lacrimal glands.

f. Keratectasia:

Bulging forwards of the cornea weakened by trachoma

Sequelae and Complications of Trachoma:

I. Lid:

- a) Ptosis: either mechanical (heaviness due to cellular infiltration) or due to fibrosis and weakness of Muller's muscle.
- b) Trichiasis: Due to local scarring around the lid margin.
- c) Cicatricial entropion: Due to conjunctival shrinkage.
- d) Chronic Meibomianitis.

2. Conjunctiva:

- a) Posterior symblepharon: adhesions in the fornices.
- b) Xerosis.
- c) Hyaline and amyloid degeneration of upper tarsus and conjunctiva.

3. Lacrimal system:

- a) Obstruction of puncti by fibrosis.
- b) Chronic canaliculitis with epiphora.
- c) Chronic dacryocystitis.
- d) Chronic dacryoadenitis.

4. Corneal complications: According to the stage (see corneal manifestations)

Diagnosis of Trachoma

- 1. Clinical sure signs: Expressible follicles, pannus with Herbert's pits, Arlt's line, post trachomatous degenerations (PTDs).
- 2. Intracytoplasmic basophilic inclusion bodies in conjunctival scrapings stained with Giemsa stain.
- 3. Immunologic tests.

Differential diagnosis:

- 1. Follicular trachoma: From other causes of follicular conjunctivitis.
- 2. Papillary trachoma: From other causes of papillae mainly spring catarrh.
- 3. Trachomatous pannus: From other causes of pannus.

Prevention:

- 1. Combat flies.
- 2. The patient should use separate towels that must be boiled.
- 3. Careful disinfection of infected fingers.
- 4. Early diagnosis and treatment.

Treatment:

1. Medical:

- a) Local Sulfonamide or broad-spectrum antibiotic eye drops and ointment (Tetracycline, Erythromycin, Quinolones) used frequently for 6-12 weeks.
- b) Atropine if the cornea is involved.
- c) General Sulfonamide, Tetracycline & Quinolones.

2. Surgical: May be needed with medical treatment

- a) Expression of follicles.
- b) Scraping of papillae.
- c) Picking of PTDs.

Inclusion Conjunctivitis

Etiology:

Causative agent is Chlamydia trachomatis type D transmitted from the genitals by fingers or through water of swimming pools (swimming pool conjunctivitis).

Clinical picture:

- 1. Lower lid follicles.
- 2. Superficial punctate keratitis.
- 3. Urethral or vaginal discharge.
- 4. Spontaneous healing within 3-12 months.

Treatment:

- 1. Sulfacetamide or broad-spectrum antibiotic eye drops and ointment: Tetracycline, Erythromycin.
- 2. General Sulfonamide, Tetracycline or broad-spectrum antibiotics as Azithromycin.

Acute Non-infective Conjunctivitis

- 1. Mechanical injury:** General irritation with dust, smoke, wind, heat, physical, chemicals agents and self-inflicted.
- 2. Photophthalmia:** Exposure to ultraviolet rays as welding arcs and skiing.

Clinical picture: (after 4-6 hours)

- a) Irritation: Photophobia, burning sensation, pain & blepharospasm.
- b) Watery or mucoid discharge.
- c) Hyperemia.
- d) Punctate corneal erosion.

3. Acute allergic conjunctivitis:

Etiology:

Hypersensitivity to airborne plant or animal allergen especially patients with asthma, hay fever or atopy.

Clinical picture: (minutes after exposure)

1. Itching and eyelid swelling.
2. Watery or mucoid discharge.
3. Hyperemia.
4. Edema of lids and conjunctiva.

Treatment of acute non-infective conjunctivitis:

1. Remove the cause.
2. Astringent and vasoconstrictor drops (Zinc sulfate).
3. Cold compresses.
4. Artificial lubricants (Methyl cellulose).
5. Non-steroidal anti-inflammatory drugs (Diclofenac, Ketorolac).
6. Antiallergics (Naphazoline, Antazoline).
7. Topical steroids (Prednisolone, Dexamethasone).

Chronic Non-infective Conjunctivitis

1. Phlyctenular conjunctivitis:

Etiology: Hypersensitivity to an endogenous antigen:

- a. Tuberculo-protein
- b. Intestinal parasites.
- c. Septic focus as tonsillitis.
- d. Staphylococcal blepharoconjunctivitis.

Clinical picture:

Symptoms:

- a) Irritation: Discomfort, burning and foreign body sensation.
- b) Watery or mucoid discharge.
- c) Photophobia and blepharospasm in cases with corneal affection.

Signs:

I. Phlycten:

- a) Rounded raised nodule 1-3 mm in size.
- b) Grayish or yellowish.
- c) Common at the limbus and bulbar conjunctiva.
- d) Formed of lymphocytic aggregation covered with intact epithelium, which ulcerates later with secondary infection.
- e) Surrounded by a small area of congestion.

II. Corneal manifestations:

1. A corneal phlycten may occur superficial or deep to Bowman's membrane.
2. Phlyctenular ulcers:
 - a. Limbal: Single or multiple, may fuse to form a ring ulcer.
 - b. Fascicular: Superficial ulcer that creeps in a serpiginous manner

towards the center and is supplied by a leash of blood vessels.

On healing its track leaves an opacity maximum where it stops.

3. Phlyctenular pannus: Affects any part of the limbus.
 - a. Thin and vascular with marked irritation.
 - b. Straight vessels deep to BM.
 - c. Infiltration and vascularization with a rounded edge
 - d. Eczema of the lids and face, fissures at the outer canthus may occur.

Differential diagnosis:

1. Bulbar spring catarrh.
2. Episcleritis.
3. Pinguecula.
4. Phlyctenular pannus should be differentiated from other causes of pannus.

Table (4): Differential diagnosis of phlycten

(A)	Phlycten	Pinguecula
Age	Young	Old
Shape	Round	Triangular
Color	Grey	Yellow
Site	Anywhere	Nasal side
Ulceration	Occurs	Never ulcerates

(B)	Phlycten	Episcleritis
Age	Children	Old
Level	Superficial	Deep
Color	Grey	Purple
Movement	Moves with conjunctiva	Fixed to sclera
Tenderness	Not tender	Tender
Ulceration	Ulceration occurs	Never ulcerates

(C)	Phlycten	Limbal spring catarrh
Seasonal incidence	Absent	Marked
Itching	Absent	Marked
Lesion	Nodular	Gelatinous
Ulceration	Common	Absent
Discharge	No eosinophils	Present

Treatment:

1. Treat the cause of allergy if possible.
2. Dark glasses.
3. Topical steroids.
4. Lotions and local antibiotics in cases complicated with mucopurulent conjunctivitis.
5. Local Atropine in cases with corneal involvement.
6. Fascicular ulcer needs cautery with carbolic acid and actual cautery for blood vessels at the limbus.

2. Vernal kerato-conjunctivitis (Spring Catarrh):

It is a chronic allergic condition of the conjunctiva, affecting mainly children and young adults (5-25 y) characterized by seasonal variation and may be associated with keratoconus. It is due to hypersensitivity to airborne allergens. It is common in patients with asthma, hay fever or atopy.

Clinical picture:

Symptoms:

1. Itching and lacrimation.
2. Scanty whitish ropy mucoid discharge.
3. Hyperemia.
4. Photophobia and blepharospasm.
5. Symptoms increase in spring and summer (seasonal variation).

Signs:

It may present as palpebral, bulbar or mixed types

a. Palpebral Type:

1. Large flat-topped papillae giving a cobblestone appearance on the tarsi and absent from the fornix affecting mainly the upper tarsus.

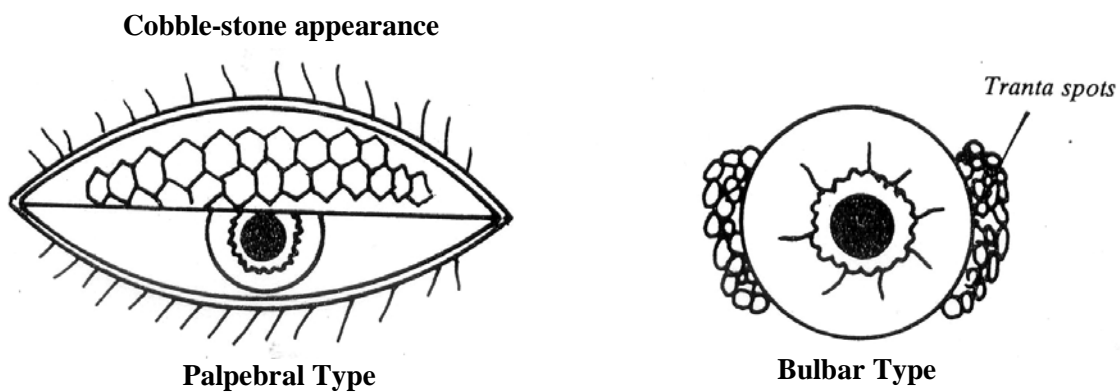
2. The papillae are bluish-white or red, formed of a central core of fibrous tissue rich in eosinophils covered by thick epithelium. The center and the edges of the papillae show tiny twigs of blood vessels.
3. If the papillae are exposed by lid eversion, they are covered by a sticky milky white film of discharge rich in eosinophils.

b. Bulbar Type: (More severe)

1. Manifests as gelatinous limbal masses formed of hypertrophied epithelium with connective tissue core and hyaline degeneration.
2. It usually starts at the upper limbus, then later all round.
3. White spot concretions of eosinophils and necrotic epithelium may be seen (Tranta spots).

c. Mixed type:

The mixed type is a mixture of the palpebral and bulbar types.



Spring Catarrh

Other corneal manifestations include:

- i. Fine punctate epithelial keratitis.
- ii. 360-degree corneal pannus may occur.
- iii. Rarely vernal corneal ulcers.

Differential diagnosis:

1. Palpebral type should be differentiated from papillary trachoma.
2. Bulbar type should be differentiated from limbal phlycten.

Treatment:

A) Symptomatic:

1. Dark glasses and cold compresses.
2. Vasoconstrictor and anti-histaminic drops.
3. Systemic antihistaminics may help.
4. Avoid exposure to allergens if known.

B) Mast cell stabilizers:

1. Disodium chromoglycate, which prevents mast cell degranulation preventing histamine release.
2. Lodoxamide.

C) Topical steroids:

1. Only in severe non-responsive cases.
2. Prolonged use may cause cataract and secondary glaucoma.

D) Resistant cases:

Beta irradiation to the conjunctiva is used.

3. Giant papillary conjunctivitis:

Etiology:

1. Associated with contact lens wear especially extended-wear contact lenses, least with hard lenses.
2. May result from irritation with ocular prosthesis or by exposed corneal sutures.

Clinical picture:

Symptoms:

1. Contact lens intolerance.
2. Irritation: Discomfort, burning and foreign body sensation.
3. Watery or mucoid discharge.
4. Blurred vision from mucous coating of the contact lens.
5. Hyperemia.

Signs:

Giant papillae affecting mainly the superior tarsal conjunctiva. They are large, flat-topped and covered with mucus.

Treatment:

1. Discontinuation of use of offending lens (symptoms resolve but the papillae will persist for several months).
2. Topical treatment as in spring catarrh (vasoconstrictors, antihistaminics, mast cell stabilizers, steroids, NSAIDs).

Degenerations of the Conjunctiva

1. Pinguecula:

It is a degenerative condition occurring in elderly due to effects of ultraviolet rays. It is due to hyaline and elastic degeneration of the subepithelial conjunctival tissue with elastoid tissue deposition.

Clinical Picture:

Triangular in shape (base towards the cornea) raised yellow nodule, usual on the nasal side of limbus and non vascular.

2. Pterygium:

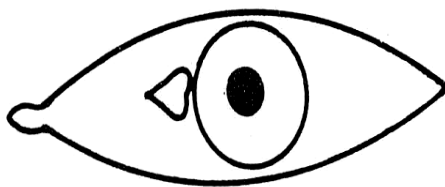
It is a degenerative condition due to chronic irritation by ultraviolet rays, dust, wind or fumes. It consists of fibrovascular tissue with elastoid degeneration, stromal collagen covered with a single layer of thick conjunctival epithelium that creeps on the cornea in a triangular shape, usually on the nasal side, but it may be on the temporal side also. It may be unilateral or bilateral.

The pterygium is formed of:

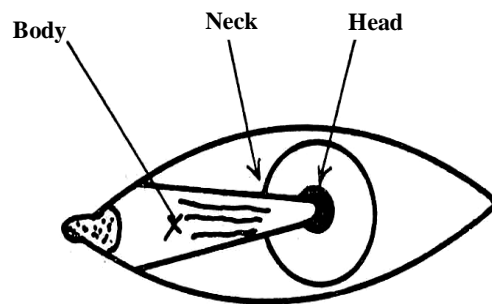
Head: Lies over the cornea and may grow to cover the pupil.

Neck: Overlying the limbus.

Body: Over the sclera being loosely adherent to it.



Pinguecula



Pterygium

Types:

1. Progressive type: Thick, vascular and fleshy. It creeps towards the center of the cornea affecting vision.
2. Regressive type: Thin, less vascular and membranous.

Differential diagnosis:

Pterygium should be differentiated from pseudo-ptyerygium,

In pseudo-ptyerygium:

1. A fold of the conjunctiva is attached to the base of a healed corneal ulcer.
2. Usually unilateral and occurs anywhere in the conjunctiva.
A metal hook can pass under pseudopterygium.

Table (5): Differential diagnosis of pterygium

	Pterygium	Pseudo-ptyerygium
Nature	Degenerative condition	A fold of conj. attached to the base of a healed corneal ulcer
Site	Bilateral on nasal side	Unilateral – anywhere
Hook	Cannot be passed under the neck	Can be passed under the neck
Course	Progressive or stationary	Always stationary

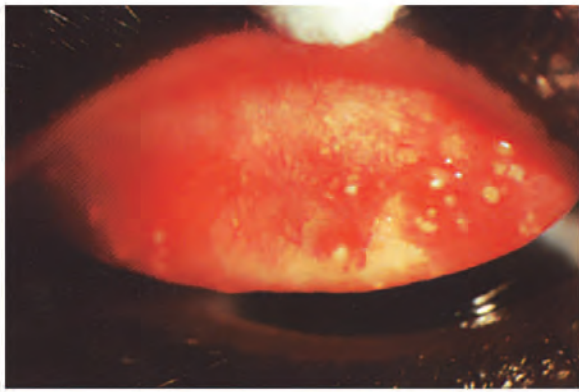
Treatment:

Excision if the pterygium is progressive, encroaches on the pupillary area or cosmetically bad.

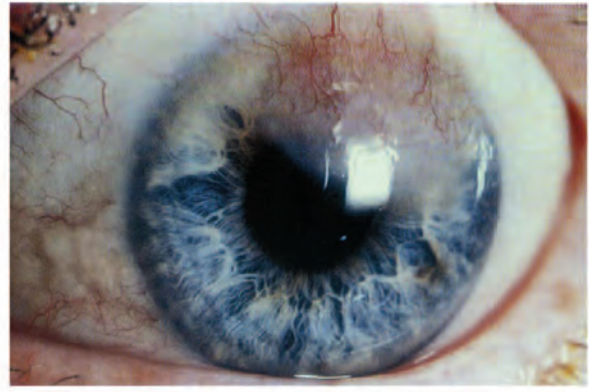
Operations:

1. Simple excision (recurrence is common).
2. Excision with bare sclera with or without beta irradiation.
3. Excision with grafting (mucous membrane or conjunctival graft, limbal stem cell graft, amniotic membrane).
4. If the cornea is affected, lamellar keratoplasty may be indicated.

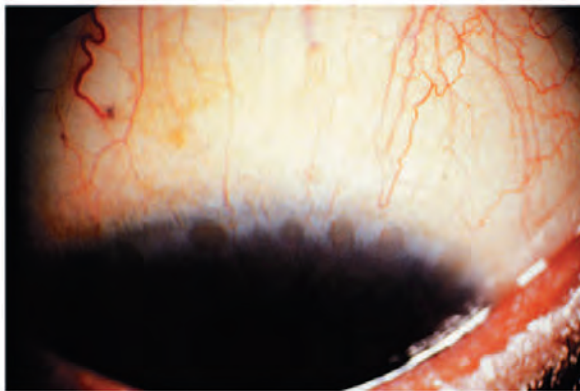
N.B. Recurrence is common, particularly on re-operation. Beta irradiation decreases the rate of recurrence.



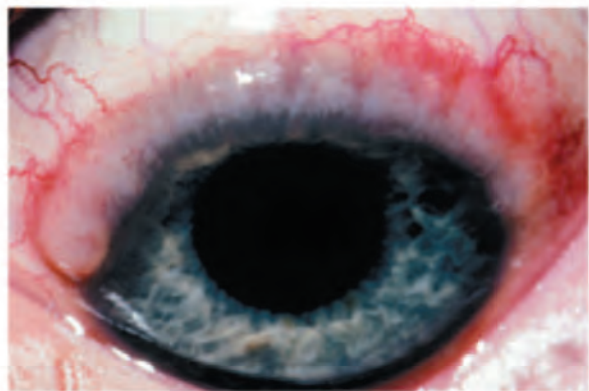
Upper lid PTDs



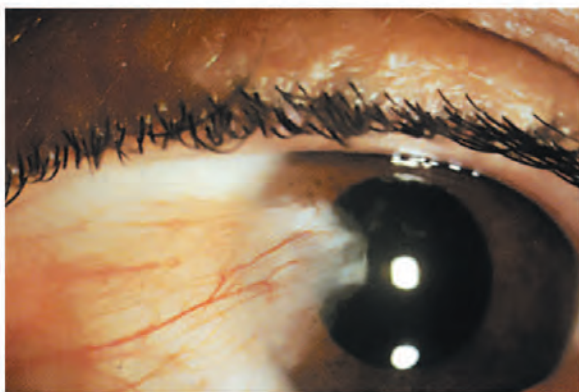Pannus



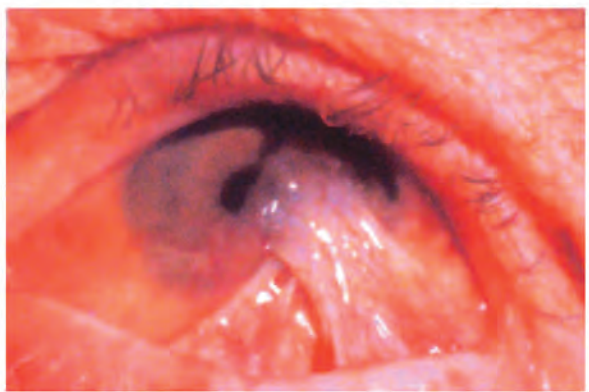
Herbert Pits



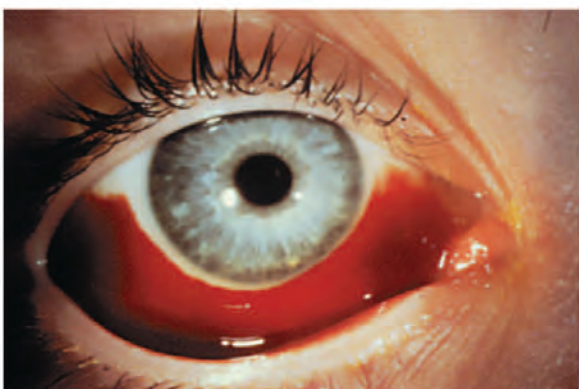
Bulbar vernal catarrh



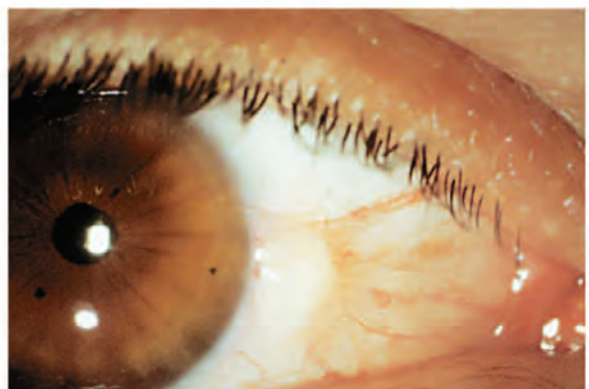
Nasal pterygium



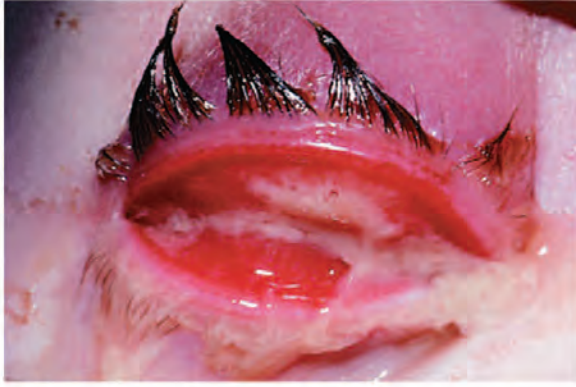Pseudopterygium



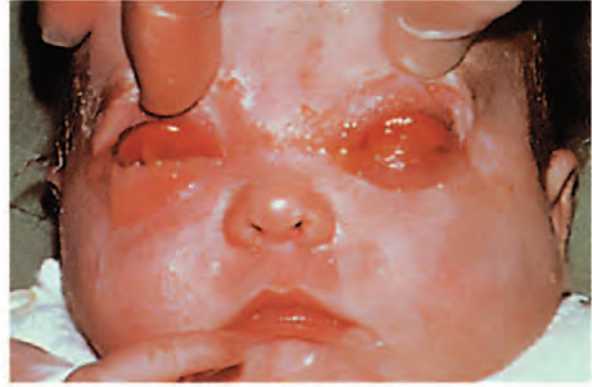Subconjunctival haemorrhage



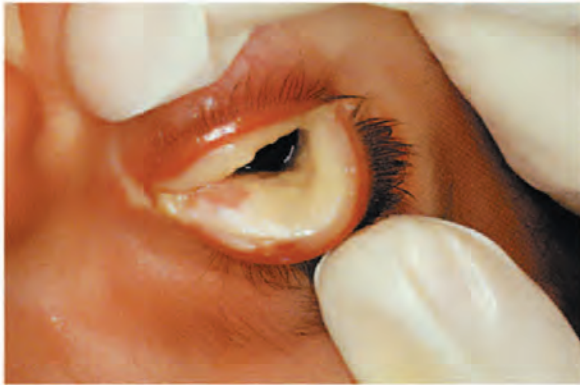Pinguecula



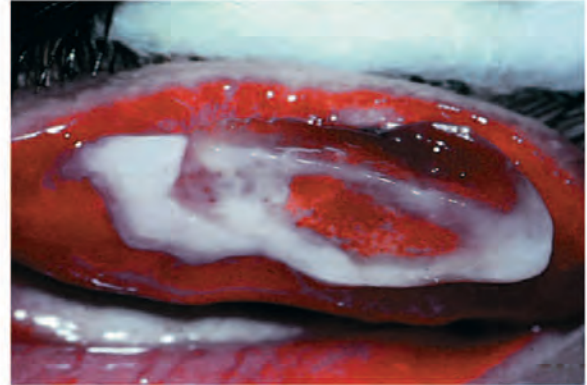
Purulent conjunctivitis



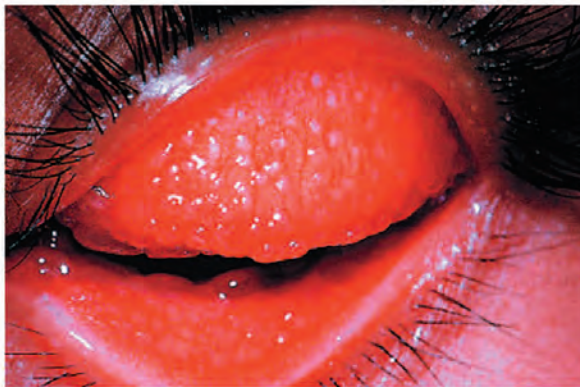Gonococcal conjunctivitis



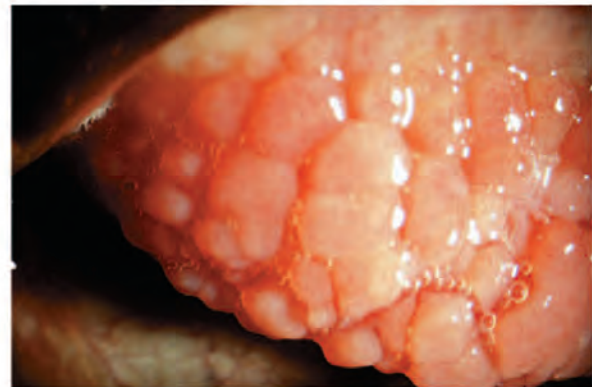
Membranous conjunctivitis



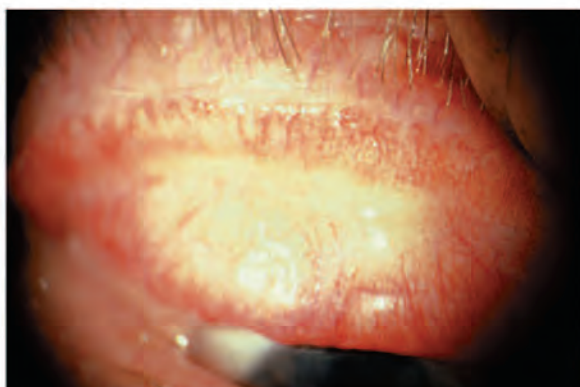
Pseudo membrane



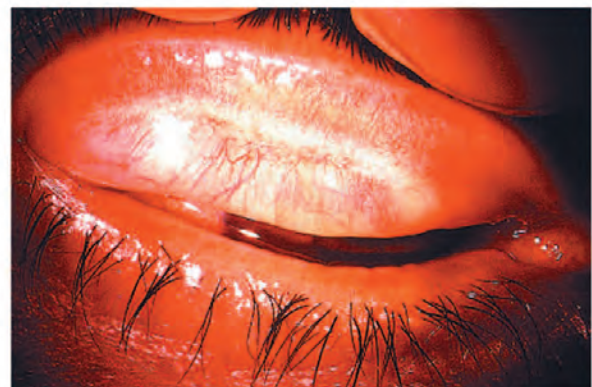Severe follicular conjunctivitis



Giant papillae



Scarring involving the entire conjunctiva

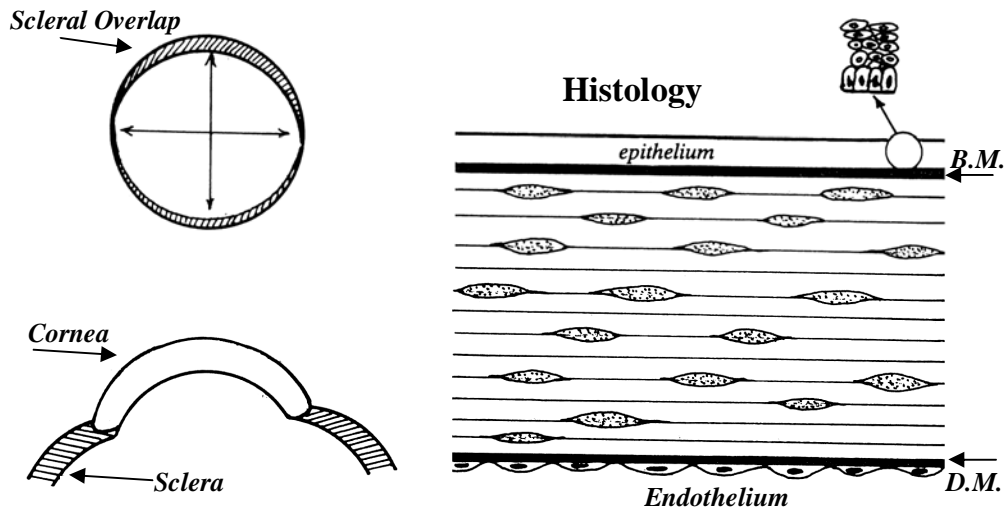


Arlt's line

Chapter 6

Cornea

Gross Anatomy:



Anatomy of the Cornea

Site: Anterior 1/6 of the outer coat of the eye.

Shape: Curved.

Transparency: Transparent, clear and brilliant (luster).

Diameter: Horizontal: 12 mm, Vertical: 11 mm.

Thickness: Central part: 0.5 mm, Peripheral part: 1mm.

Refractive power: +42 diopters.

Histology: Consists of 5 layers

1. Epithelium: Stratified squamous non keratinized epithelium. It is about 5-6 cell layers thick and quickly regenerates when the cornea is injured.
2. Bowman's membrane: Clear structurless elastic membrane lying just beneath the epithelium. If destroyed, cannot regenerate.

3. Stroma: Is the thickest layer and lies just beneath Bowman's membrane. It is composed of 100-150 transparent regular lamellae of tiny collagen fibrils that run parallel to each other giving the cornea its clarity.

4. Descemet's membrane: Elastic membrane lies between the stroma and the endothelium. It is resistant and easily regenerates.

5. Endothelium: Single layer of hexagonal flat cells that lies just underneath Descemet's membrane. This layer is important for corneal dehydration.

Nutrition:

The cornea is avascular and its nutrition is obtained by diffusion from:

- a. *Circum corneal*: Limbal capillaries.
- b. *Anterior chamber*: Aqueous humor.
- c. *Precorneal*: Tear film.

Nerve supply:

- 2 long ciliary nerves of the nasociliary nerve (a branch of the ophthalmic division of trigeminal nerve).
- Nerves of the surrounding conjunctiva.

Diseases of Cornea

Keratitis

Keratitis is an inflammation of the cornea. It may be ulcerative or non-ulcerative.

I- Ulcerative keratitis (corneal ulcer): In which there is destruction of an area of both epithelium and the underlying stroma of the cornea.

Classification of ulcerative keratitis:

(a) Primary corneal ulcer: Where the necrosis occurring primarily in the cornea without associated conjunctivitis.

They are classified into two main groups:

1- Microbial:

- a- Bacterial
- b- Viral
- c- Fungal
- d- Protozoal

2- Non-microbial:

- a- Exposure keratitis
- b- Traumatic
- c- Neuropathic keratopathy
- d- Keratomalacia
- e- Atheromatous ulcer
- f- Allergic
- g- Autoimmune

(b) Secondary corneal ulcer: Where ulcer occurs as a complication of conjunctivitis (e.g catarrhal conjunctivitis, diphtheric conjunctivitis, gonococcal conjunctivitis, phlyctenular conjunctivitis, trachomeatous conjunctivitis).

II-Non-ulcerative keratitis: In which the stroma of the cornea is only affected with intact overlying epithelium.

Classification of non-ulcerative keratitis:

(a) Superficial keratitis:

- Punctate.
- Pannus (trachomeatous, phlyctenular, leprotic).

(b) Interstitial keratitis.

(c) Deep keratitis.

I. Microbial corneal ulcers

A. Bacterial Corneal Ulcer (Hypopyon ulcer)

Corneal ulcers are ocular emergencies. Any corneal ulcer is considered infective until proved otherwise.

Predisposing factors:

1. Traumatic abrasion as in rubbing lash.
2. Contact lens wear.
3. Dry eyes.
4. Exposure.
5. Loss of sensation.
6. Chronic conjunctivitis, blepharitis and dacryocystitis.

Certain pathogenic bacteria can invade the cornea and produce infective ulcers without the help of predisposing factors. Examples of such vigorous organisms are *N. gonorrhoea*, *C. diphtheria*, *Listeria* and *H. aegypticus*.

Clinical picture:

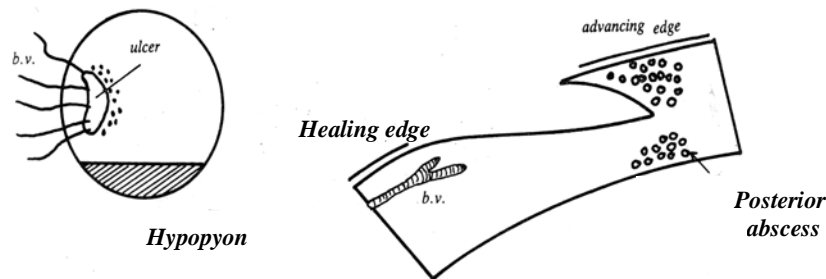
Symptoms:

1. Neuralgic pain.
2. Photophobia.
3. Lacrimation.
4. Blepharospasm.
5. Decreased vision.

Signs:

1. Edema of the lids and conjunctiva.
2. Loss of corneal luster.
3. The area of the ulcer is stained with fluorescein 1% solution, giving green color of the ulcerated area in blue light.

4. Infiltration in the bed and the edges of the epithelial defect.
5. Anterior chamber examination shows flare, cells and even hypopyon.
6. Acute serpiginous ulcer (**hypopyon ulcer**) is a central ulcer with an undermined central advancing edge and a sloping peripheral healing edge. This ulcer is caused by pneumococci and has a tendency to perforate.



Hypopyon corneal ulcer

B. Herpes Simplex Keratitis

Dendritic ulcer:

This is the classical corneal lesion in recurrent Herpes Simplex virus keratitis.

- The epithelial infiltration starts as (punctuate) then linear (striate), then (stellate) then (dendritic) branching, usually central, ending in round knobs and shows +ve Rose Bengal staining then it became (amoeboid) lastly it became (geographic).
- Shedding of the infected epithelium leads to a dendritic ulcer, the bed of the ulcer stains with fluorescein while diseased epithelialized margins stain with rose Bengal.
- The bed of the ulcer is insensitive (corneal hypoesthesia).

- If BM and stroma are not involved, the lesion may heal leaving no opacity.
- The ulcer is characteristically superficial and non-vascularized.

C. Herpes Zoster Ophthalmicus

It's due to unilateral affection of the ophthalmic division of the trigeminal nerve.

- Varicella (chicken pox) and zoster are different conditions caused by the same virus.

Clinical Picture:

❖ Prodroma

Fever, malaise, headache, neuralgia along distribution of nerves.

❖ Skin lesions

Lesions along one or more of the three branches: frontal, lacrimal and nasociliary nerves. The lesions consist of papules then pustules and crusting ulcers which heal by punched out scars.

❖ Ocular lesions

1. Mucopurulent conjunctivitis.
2. Episcleritis and scleritis.
3. Corneal lesions:
 - i. Punctate epithelial keratitis.
 - ii. Microdendrites.
 - iii. Nummular keratitis.
 - iv. Disciform keratitis.
4. Anterior uveitis.
5. Acute retinal necrosis.

❖ **Neurological**

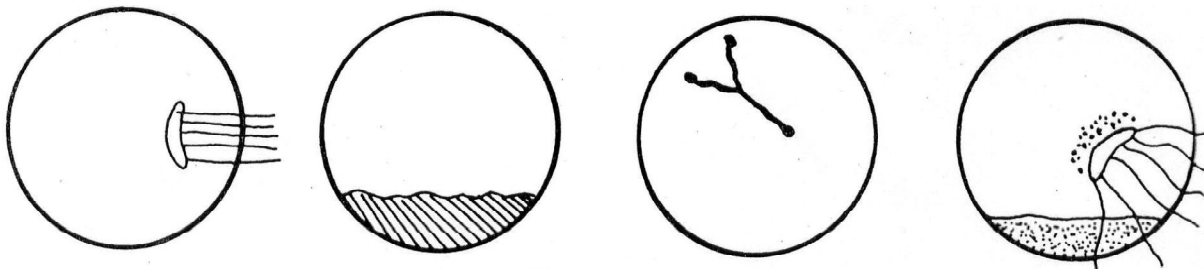
1. Cranial Nerve affection: 2,3,4,5.
2. Encephalitis.
3. Post herpetic neuralgia which may be severe and chronic.

D. Fungal ulcer

History of foreign body touch (plant origin). It is usually atypical (not easy to diagnose).

E. Protozoal ulcer (Acanthameba)

History of contact lens wears with bad hygiene. It is usually atypical; however, pain is usually severe and not parallel to clinical manifestations.



Fascicular

Ulcer with lagophthalmos

Dendritic, HS

Hypopyon

Corneal ulcers

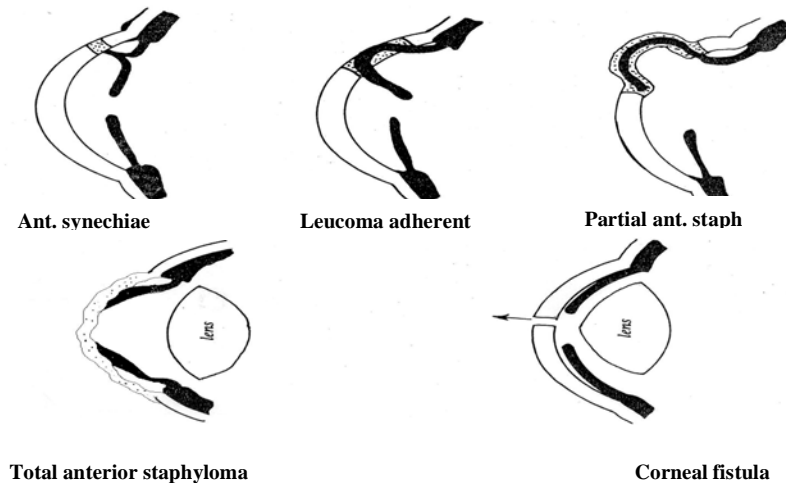
Complications of corneal ulcers

1. Anterior uveitis: It may result in hypopyon and posterior synechia.
2. Secondary glaucoma: Due to excessive protein and cellular debris in the aqueous humor. It may also develop as a result of peripheral anterior synechia obstructing the angle of the anterior chamber.
3. Corneal opacity due to destruction of BM and stroma.
4. Keratectasia: Bulging of a thin corneal cicatrix.
5. Descematocele (Protrusion of Descemet's membrane) or actual perforation.

Complications of perforation include:

1. Corneal fistula: This occurs when the corneal epithelium migrates inwards to line the ulcer forming a track.
2. Epithelialization: If the corneal fistula is not treated, the epithelium may migrate furthermore to line the back of the cornea, the anterior surface of the iris and the angle of the anterior chamber.
3. Peripheral anterior synechiae: Following perforation, the anterior chamber becomes flat and the cornea becomes adherent to the iris. At first, the adhesions are fibrinous, later; the adhesions become fibrous and permanent.
4. Secondary glaucoma: Due to peripheral anterior synechiae and /or epithelialization of the angle.
5. Leucoma adherent.
6. Anterior staphyloma: Due to weakness of the corneal scar tissue that bulges in front of the intraocular pressure.
7. Complicated cataract.

8. Intraocular hemorrhage, subluxation and dislocation of the lens due to sudden lowering of the intraocular pressure.
9. Endophthalmitis: The most serious complication of perforated ulcers.



Complications of Corneal Ulcer

Treatment of corneal ulcers

Corneal scraping is important with laboratory investigation (culture and sensitivity test) before starting specific treatment.

A. General treatment:

1. Cycloplegics:

Cycloplegics relieve associated anterior uveitis. This helps to relieve pain and prevent posterior synechia.

2. Vitamins: A, B, C (Supportive).

3. Protection: Using

- *Patching:* Protects newly growing epithelium. It also relieves photophobia and pain.
- *Bandage contact lens:* Protect the growing epithelium.
- *Dark glasses.*

4. Hot fomentation.

B. Specific treatment:

Bacterial Corneal Ulcer:

Topical broad spectrum antibiotics:

- a. Fluoroquinolones e.g. Ciprofloxacin 0.3% covers almost all organisms except some species of staph aureus and pseudomonas.
- b. Combination of “fortified” Aminoglycosides and Cephalosporines will cover almost all gram +ve and gram –ve cocci.

Herpes Simplex Keratitis:

Antiviral drugs

Topical ophthalmic antiviral preparations interfere with viral replication by altering DNA synthesis. They are used for treatment of viral eye infections as herpes simplex keratitis and viral conjunctivitis. The drug of choice is Acyclovir.

- a. Acyclovir 3% ointment used 5 times per day.
- b. Trifluorothymidine 1% drops 5 times per day.
- c. Adenosine – arabinoside ointment 3% 5 times per day.

Topical steroids are absolutely contraindicated in the presence of herpetic ulcers as they can result in an amoeboid ulcer or perforation.

Herpes Zoster Ophthalmicus:

- a. Systemic acyclovir (Zovirax): 800mg tablets (5 times daily for 7days).
- b. Skin lesions: Antiviral (Zovirax) and steroid - antibiotic cream.
- c. Ocular lesions: Topical Acyclovir.

Fungal ulcer:

Antifungal treatment (Amphotericium B) is used on basis of positive lab results.

Protozoal ulcer:

Anti-acanthamebic treatment is used on basis of positive lab results.

C. Treatment of complications:

1. Debridement to remove infected epithelium is one line of simple surgical treatment to be followed by intensive topical medications.
2. Cautery by tincture iodine 7.5% or absolute alcohol.
3. Paracentesis: Is indicated in cases of descemetocoele (indicating an impending perforation), and in cases of hypopyon with secondary glaucoma.
4. Tissue adhesive glue can be used for small perforations, where larger perforations need therapeutic corneal grafting.
5. Tarsorrhaphy and conjunctival flaps promote healing in cases of exposure and loss of corneal sensation.
6. Lamellar or penetrating keratoplasty is done to manage opacified cornea.

II- Non-Microbial Corneal Ulcers

A. Ulcer with lagophthalmos (Exposure keratopathy)

This type of ulcer is associated with facial nerve paralysis leading to orbicularis paralysis and lagophthalmos.

Lack of corneal protection from minor trauma as well as dryness of the cornea lead to necrosis and sloughing of superficial corneal layers.

Treatment:

Prophylaxis against ulceration includes:

1. Frequent lubricant drops at daytime and an ointment at bed time to cover the cornea.
2. Eye patching or closure of the lids with adhesive tape during sleep.
3. If an ulcer forms, topical antibiotics and cycloplegic must be added.
4. Lateral tarsorrhaphy if lagophthalmos is not responsive to treatment.

B. Corneal anesthesia (neuropathic keratopathy)

Several conditions lead to loss of corneal sensation. Destruction of the trigeminal ganglion may be due to:

- a. Trauma as in fracture of the skull base.
- b. Inflammation as in gummatous meningitis.
- c. Iatrogenic after treatment of trigeminal neuralgia.
- d. Post herpes zoster and post herpes simplex.

The mechanism of ulceration involves loss of corneal protection. Loss of reflex blinking and lacrimation as well as loss of trophic nerve impulses.

Management:

If recovery of sensation is expected, simple procedures are adopted as:

1. Topical lubricants.
2. Therapeutic soft contact lens.
3. Temporary tarsorrhaphy.

C. Nutritional deficiency (keratomalacia)

Acute melting of the cornea due to vitamin A deficiency.

Etiology:

Advanced starvation and marasmus in very young children.

Clinical picture:

1. Bilateral melting of the cornea.
2. Minimal inflammatory response.
3. Prolapse of the ocular contents when perforation occurs.
4. Secondary bacterial infection and panophthalmitis.
5. Blindness.

Management

1. Large doses of vitamin A.
 - Systemic daily dose 5000 IU/day
 - Local eye ointment
2. Improve general condition.

D. Photophthalmia

Definition:

Superficial keratitis caused by UV rays (usually following welding).

Clinical picture:

1. Extreme burning pain.
2. Lacrimation.
3. Photophobia.
4. Blepharospasm.
5. Swelling of the lid and conjunctiva (latent period: 4-5 hours).
6. Conjunctival hyperemia.
7. The cornea shows multiple superficial erosions.

Protection:

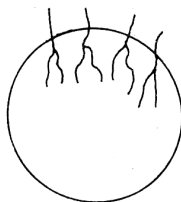
Dark glasses and special protective goggles should be worn during exposure to the hazardous rays.

Treatment:

- i. Cold compresses.
- ii. Frequent topical lubricants.
- iii. Bandage of both eyes for one day.

Table (6): Corneal vascularization

Superficial vascularization	Deep vascularization
1. Vessels derived from conjunctival vessels	From anterior ciliary vessels
2. Are seen crossing the limbus	End abruptly at the limbus
3. Bright red well defined	Dark red ill-defined
4. Branch dichotomously	Run parallel
5. The surface of the cornea is irregular (raised by Bl.v.)	Surface is smooth
6. Vessels run in the superficial stroma	Run in posterior 2/3
7. Occurs in: <ul style="list-style-type: none"> • Pannus • Corneal ulcer • Trichiasis • Pterygium • Ariboflavinosis 	Occurs in: <ul style="list-style-type: none"> • Interstitial keratitis • Deep ulcers



Keratoconus

Keratoconus is a progressive central stromal thinning leading to ectasia and apical protrusion. It may be bilateral in 85% of cases. The condition starts around puberty (10-20 years) and progresses for few years.

Keratoconus is sometimes associated with:

- Systemic diseases such as Down's syndrome, Marfan's syndrome.
- Ocular diseases as spring catarrh.

Clinical picture:

Symptoms:

Frequent changing of glasses due to rapidly progressive myopia and astigmatism.

Signs:

1. Apical protrusion forming a cone shaped deformity.
2. Corneal thinning, scarring and opacities may be seen.
3. Fleischer ring: Iron deposits at the base of the cone.
4. Munson's sign is the angulations of the lower lid on downward gaze.
5. Early diagnosis is done by corneal topography.

Treatment:

1. Spectacles can be used in early cases to correct astigmatism.
2. Rigid contact lenses may help in irregular astigmatism.
3. Surgery: Penetrating keratoplasty (PKP) is the final line of treatment.
4. New techniques are used now to improve or stabilize the condition such as Intra corneal segments and Cross linking.

Corneal Opacities

Corneal opacities are common cause for diminution of vision in Egypt.

Corneal opacity may be nebula, leucoma or macula. Also it may be present in central, paracentral or peripheral cornea. This occurs following a corneal lesion.

Management:

Treatment usually depends on the effect of corneal opacity or visual acuity:

1. If corneal opacity has no effect on vision (peripheral): No treatment.
2. If corneal opacity changes corneal curvature (being peripheral but causing some traction centrally): Glasses or contact lens.
3. Paracentral significant corneal opacity with positive mydriatic test: Topical mydriatic or visual iridectomy.
4. In central significant corneal opacity: keratoplasty.

N.B: *It is a good policy to give a short course of steroids in recently healed ulcers to diminish corneal scarring hence, less effect on visual acuity.*

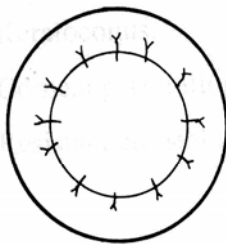
Keratoplasty

Keratoplasty means replacement of diseased corneal tissue by healthy tissue, the cornea may be obtained from the other eye of the same patient (autogenous graft), or from cadaver eyes (allograft).

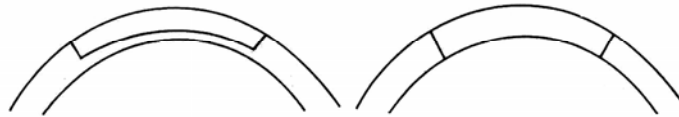Corneal grafting may be penetrating (full thickness) or lamellar (partial thickness).

Indications of keratoplasty include:

1. Corneal opacities.
2. Keratoconus.
3. Corneal perforation, fistula.
4. Resistant corneal ulcer.



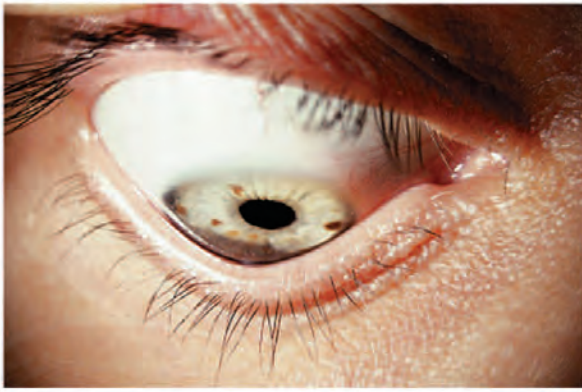Stitches in graft



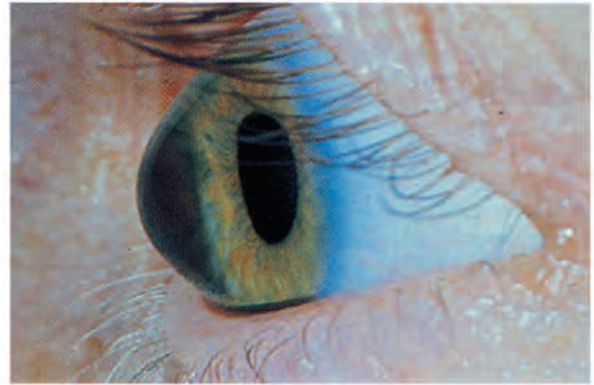
Lamellar

Penetrating

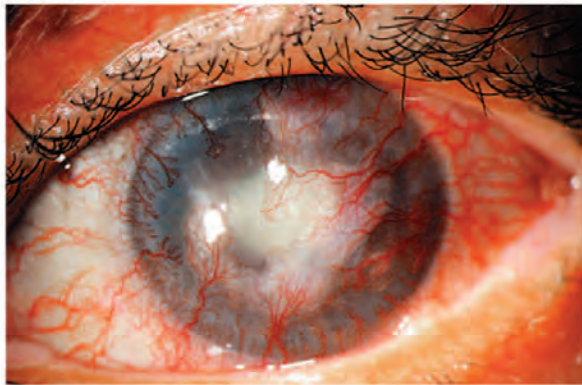Keratoplasty



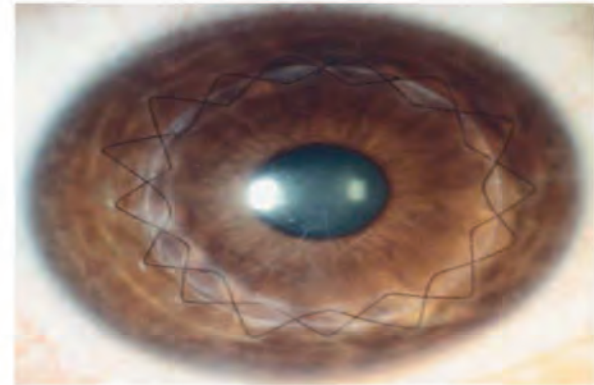
Keratoconus (Munson sign)



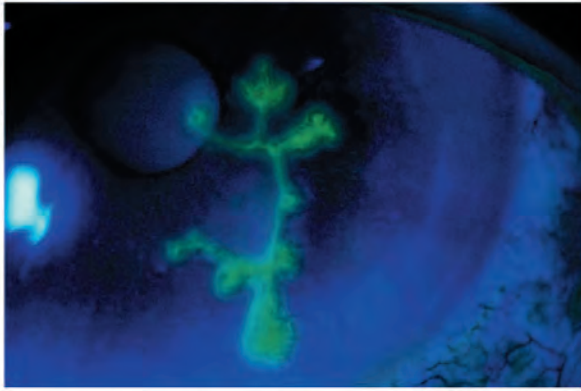
Keratoconus



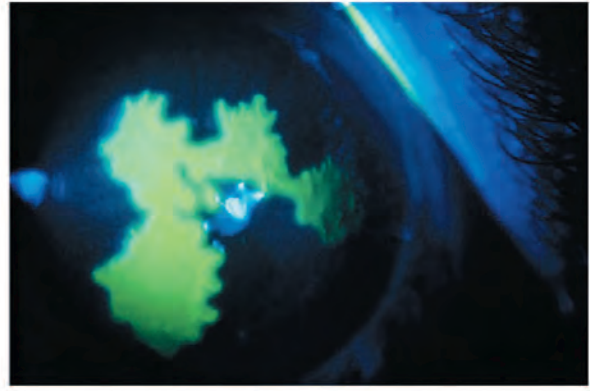
Corneal scarring and vascularisation



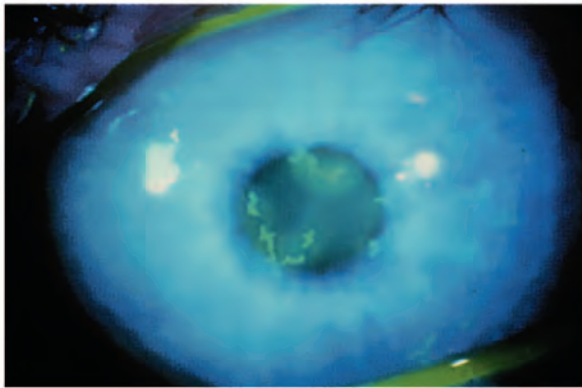
Penetrating keratoplasty



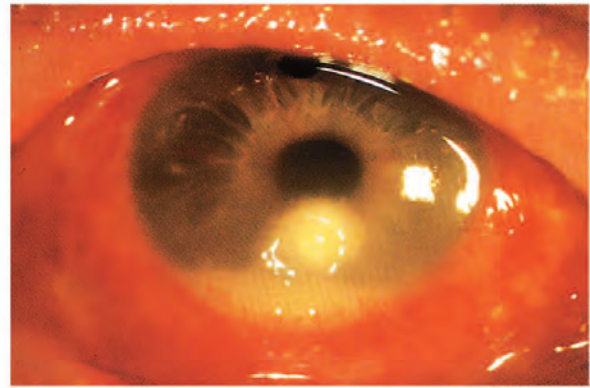Dendritic ulcer stained with fluorescein



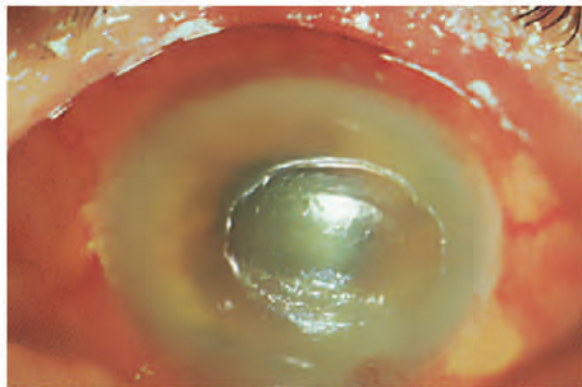
Geographic ulcer



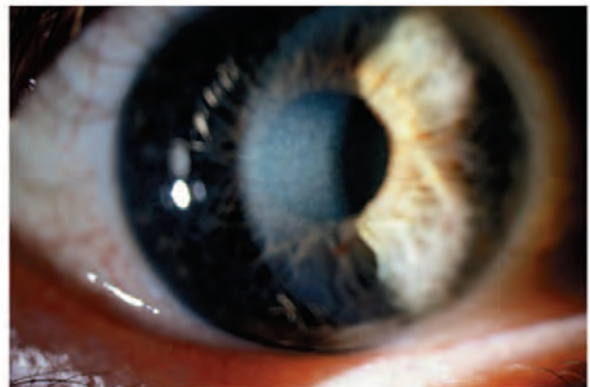Dendritic keratitis in herpes zoster



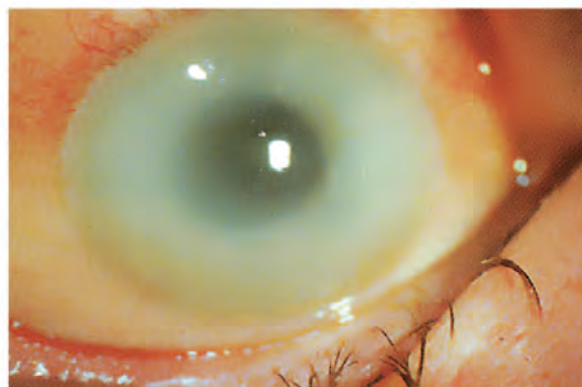
Hypopyon corneal ulcer



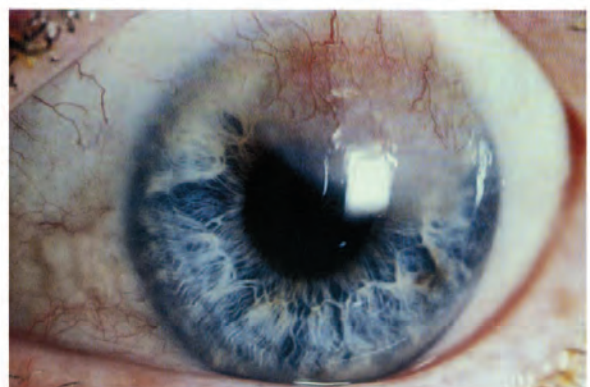
Exposure keratitis in lagophthalmos



Nebula



Diffuse corneal opacity



Pannus

Chapter 7

Sclera

Applied anatomy

It is a strong, opaque, white fibrous layer which forms 5/6 of the external tunic of the eye. It is relatively avascular therefore infections rarely affect it. If they do occur, they are chronic and sluggish. It is blue (thin) in childhood and in pathological conditions where uvea shines through it. It may be yellow in old age due to fat deposition. It is about 1 mm thick. Sclera is thinnest at the attachment of extraocular muscles.

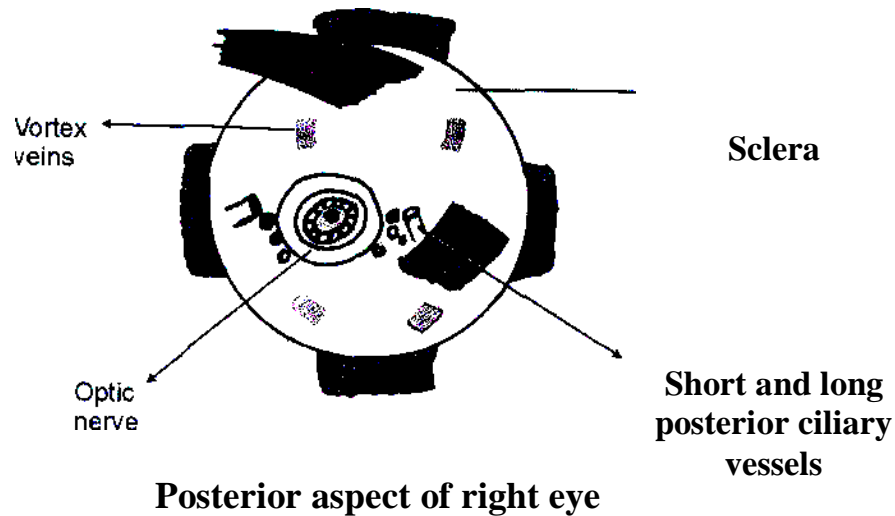
Apertures & structures passing through them:

There are 3 sets of apertures namely,

1. Anterior
 - Anterior ciliary vessels.
 - Perivascular lymphatics.
 - Nerves.
2. Middle
 - Four vena vorticiosa exit 4 mm behind the equator.
3. Posterior
 - Optic nerve exit 3 mm to the medial side and just above the posterior pole.
 - Long and short ciliary vessels and nerves.

Functions:

1. Stress and strain are overcome by the disposition of fibrous bands of the sclera.
2. Retina and choroid are maintained in the correct optical shape by the sclera.
3. It provides rigid insertion for the extraocular muscles.



Diseases of Sclera

Episcleritis

Episcleritis is inflammation of the episcleral tissue. It is more common in females.

Etiology:

1. Idiopathic: Most common.
2. Allergy to an endogenous toxin as a septic or tuberculous focus.
3. Collagen disease as in rheumatoid arthritis.

Symptoms:

1. Discomfort and lacrimation.
2. Tenderness on pressing the globe.

Signs:

1. Nodular type:

- a. Lentil size, well circumscribed.
- b. Purple in color due to dilatation of the deep vessels.
- c. It is tender and the conjunctiva moves freely over it.

2. Diffuse type:

- a. Dilated episcleral vessels.
- b. Frequently affecting only one sector.

Differential diagnosis:

Episcleritis should be differentiated from phlycten.

Treatment:

1. Topical steroids as Prednisolone & Dexamethasone.
2. NSAIDs orally (Diclofenac, Ketorolac).

Scleritis

In scleritis, the inflammation affects all layers of the sclera. It is more serious than episcleritis.

Etiology:

1. 50% of cases are associated with rheumatoid arthritis.
2. 50% of cases are idiopathic.

Symptoms:

1. Severe pain.
2. Photophobia and lacrimation.

Signs:

A. Anterior type:

1. Nodular: The nodule is deep and fixed to the sclera.
2. Diffuse.
3. Annular.
4. Necrotizing: Serious and may result in perforation of the globe.
5. Scleromalacia perforans: Melting of the sclera in a quiet eye.

B. Posterior type:

This type causes severe pain and uveitis with exudative retinal detachment.

Complications:

1. Uveitis.
2. Sclerosing keratitis: Opacity develops in the cornea near the scleral nodule.
3. Scleral staphyloma: Due to weakness of the sclera.

Treatment:

1. Topical steroids, usually ineffective.
2. Oral NSAIDs (Diclofenac, Ketorolac).
3. Large doses of oral steroids Prednisolone (1-2 mg/kg/day).
4. Immunosuppressives.

Staphyloma

Ectatic scar of the outer coat of the eye, lined by atrophic uveal tissue. It may be corneal or scleral.

a. Corneal staphyloma:

A bulge of a corneal scar with incarcerated atrophic iris tissue. It may be partial or total.

b. Scleral staphyloma:

1. Intercalary staphyloma:

2-3 mm zone with the limbus weakened by Schlemm's canal and lined by atrophic iris and peripheral anterior synechia.

2. Ciliary staphyloma:

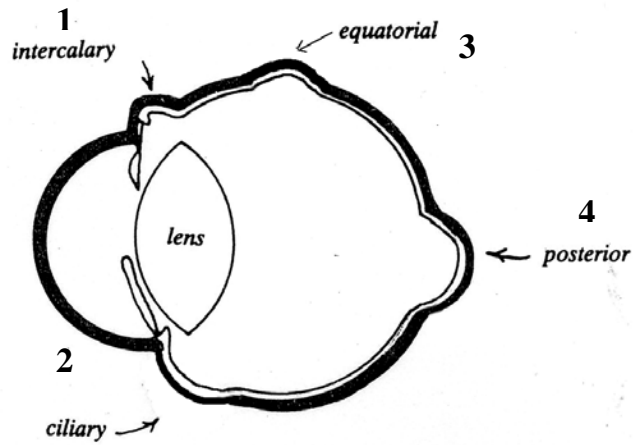
Bulged sclera is lined by ciliary body.

3. Equatorial Staphyloma:

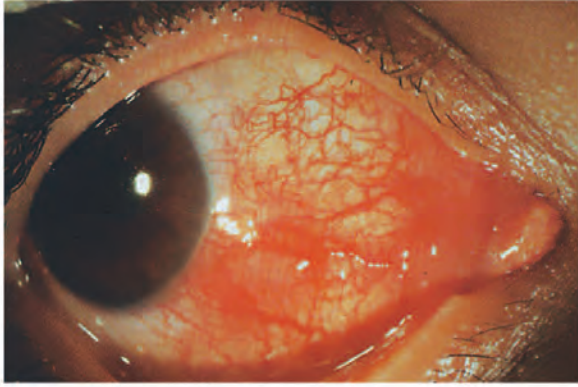Bulged sclera lined by atrophic chorio-retinal atrophic tissue.

4. Posterior Staphyloma:

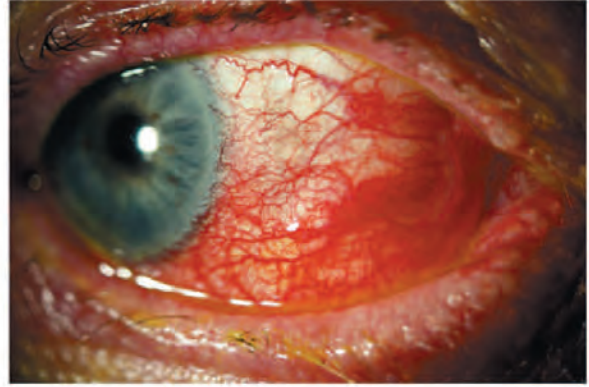
- Temporal to the optic disc.
- In high degree axial myopia.
- Seen by ophthalmoscope.



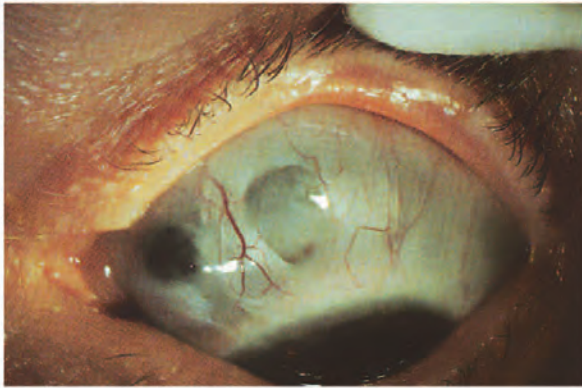
Scleral Staphylomata



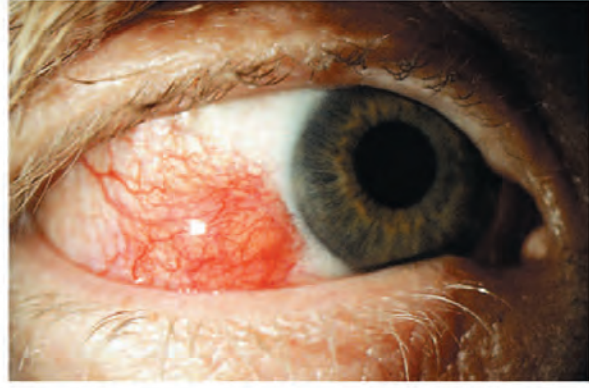
Diffuse episcleritis



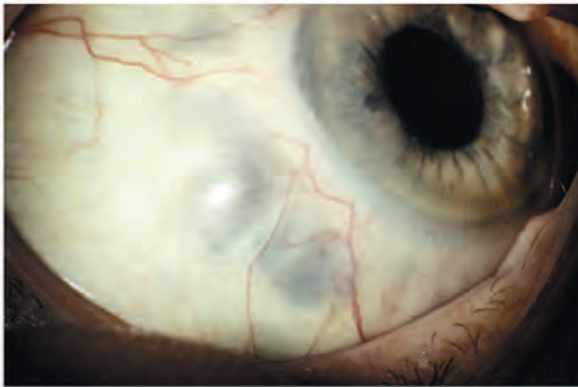
Mild diffuse scleritis



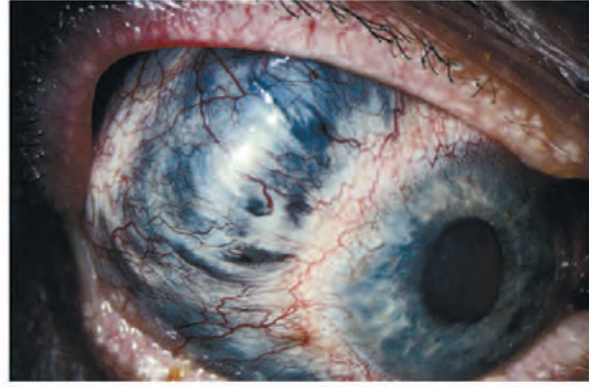
Necrotizing anterior scleritis



Nodular scleritis



Early staphyloma secondary to scleral thinning



Extensive staphyloma

Chapter 8

Uveal Tract

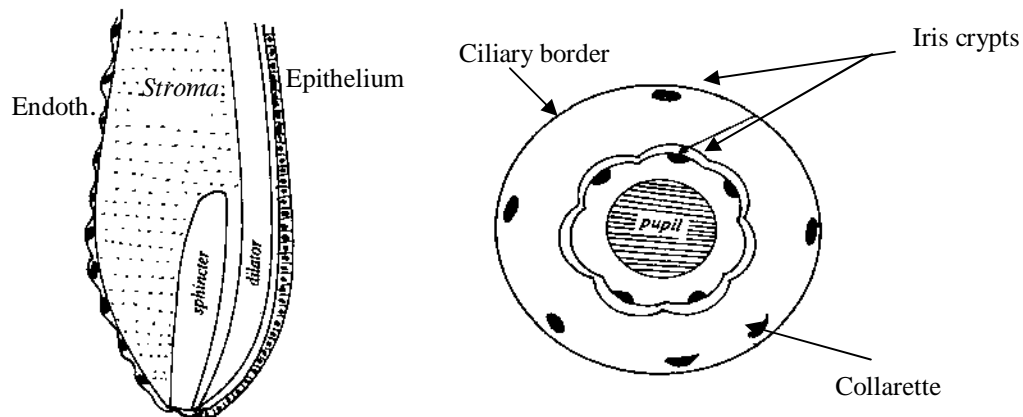
Anatomy of the uvea

The uveal tract consists of three major parts:

Iris:

It is the anterior part of the uveal tract that gives the color of the eye. Its color comes from microscopic pigment cells called melanin. Iris is thin circular disc perforated by round opening in the center called the **pupil** that controls the amount of the light entering the eye. The iris is embedded with tiny muscles that dilate and constrict the pupil.

The iris is flat and divides the anterior chamber from the posterior chamber. The color, texture and patterns of each person's iris are as unique as a fingerprint.



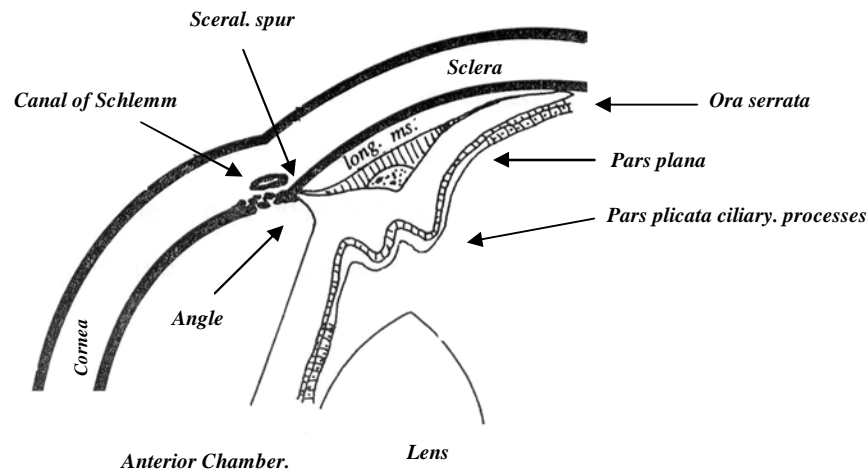
Anatomy of the Iris

Ciliary Body:

The ciliary body is the intermediate part of the uveal tract. It lies just behind the iris. It consists of 2 parts:

Anterior part (pars plicata) containing 70-80 ciliary processes and posterior part (pars plana) which is smooth and ends at ora serrata. Attached to the ciliary body are tiny fibers called zonules.

Functions of the ciliary body: Is the production of aqueous humor, the clear fluid that fills the front of the eye. It also controls accommodation by changing the shape of the crystalline lens via contraction or relaxation of the ciliary muscles.



Choroid: Anatomy of the Ciliary Body

Choroid is the posterior part of the uveal tract lying between the retina and sclera. It is composed of layers of blood vessels that nourish the back of the eye. The choroid connects with the ciliary body toward the front of the eye and is attached to edges of the optic nerve at the back of the eye.

Diseases of Uveal tract

Anterior Uveitis (Iridocyclitis)

Iridocyclitis is inflammation of the iris and the ciliary body. Both commonly occur together since they share a common blood supply. It is also called anterior uveitis. It may be acute or chronic, endogenous or exogenous, granulomatous or non-granulomatous.

Etiology: May be endogenous or exogenous.

1. Exogenous uveitis:

Exogenous uveitis is caused by either external injury to the iris or by invasion of microorganisms from outside e.g. during surgery or due to trauma. It results in suppurative inflammation known as endophthalmitis.

2. Endogenous uveitis:

a. Secondary to another disease in the eye:

- i. Keratitis.
- ii. Rupture of the lens capsule releasing lens antigens (iritis phacoanaphylactica).
- iii. Dislocation of the lens.
- iv. Longstanding retinal detachment.
- v. Intraocular tumors as retinoblastoma or malignant melanoma.

b. Associated with systemic disease:

- i. Arthritis, such as ankylosing spondylitis and collagen vascular diseases.
- ii. Granulomatous diseases such as sarcoidosis.
- iii. Chronic infection such as tuberculosis and syphilis.
- iv. Parasitic infestation such as toxoplasmosis.
- v. Viral infection such as cytomegalovirus, measles and herpes zoster.
- vi. Fungal infection such as candidiasis.

(I) Acute Iridocyclitis

Symptoms:

1. Ocular pain occurs due to irritation of the 5th nerve endings and spasm of the ciliary muscle. The pain is dull-aching (neuralgic) in character, referred to the eyebrows and more intense at night.
2. Headache in the forehead and around the eye.
3. Lacrimation.
4. Photophobia and blepharospasm.
5. Decreased visual acuity due to:
 - a. Edema of the cornea.
 - b. Turbidity of the aqueous and vitreous.
 - c. Spasm of accommodation causing myopia of 1-2 D.
 - d. Toxic maculopathy due to diffusion of prostaglandins into the posterior pole.
 - e. Keratic precipitates (KPs) on the back of the cornea and pigment deposition on the anterior lens capsule.

Signs:

1. Mild lid edema.
2. The conjunctiva shows ciliary injection.
3. Corneal edema.
4. Keratic precipitates (KPs): These are inflammatory cells deposited on the corneal endothelium, mostly in the middle and inferior zones of the cornea; they are detected by slit- lamp examination.
5. Aqueous cells: These are inflammatory cells reaching the aqueous humor, when numerous, they produce hypopyon.
6. Aqueous flare: Due to plasmoid aqueous. This is the earliest sign of iritis.

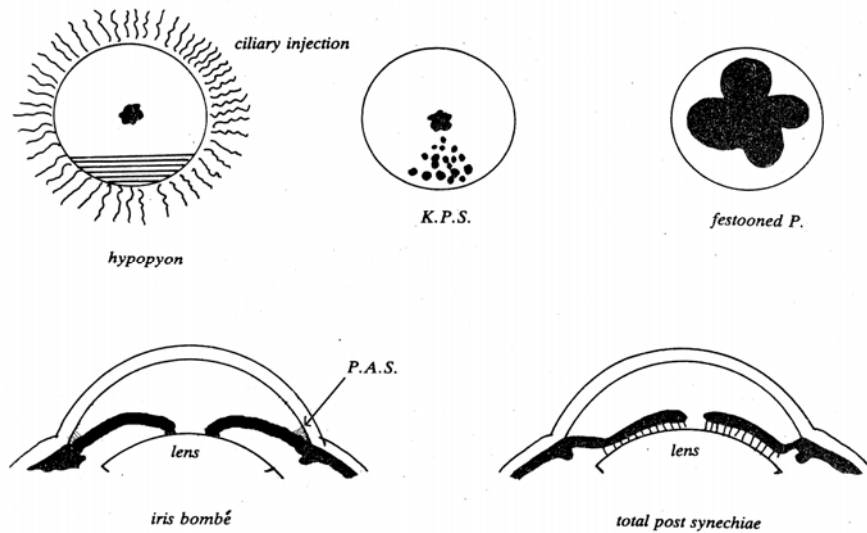
It is due to leakage of proteins through the damaged blood vessels causing turbidity of the aqueous humor. It is detected by slit-lamp examination.

7. Iris: Is muddy in color with loss of iris pattern due to accumulation of exudates on its surface.
8. Pupil: Shows miosis due to straightening of blood vessels and spasm of the sphincter muscles.
9. Hyphema: May appear with marked congestion of vessels, as in herpetic and tuberculous iridocyclitis.
10. Ciliary body: Shows tenderness detected by pressing on the eyelids.
11. Lens: Iris pigments precipitates on the anterior lens capsule.
12. Vitreous: Shows inflammatory cells, mainly in its anterior third.
13. Intraocular pressure is usually low in the acute phase, but secondary glaucoma may occur in chronic and recurrent cases. In the acute phase, rise of pressure may occur due to plasmoid aqueous.

Complications of acute iridocyclitis:

Most of the complications result from the organization of exudates, which are transformed into fibrous tissue that causes adhesions.

- 1. Posterior synechiae:** Adhesions between the iris and the lens. Mild synechiae at one or more points, manifest itself as a festooned pupil when it is dilated. Severe types include ring synechiae that occlude the pupil causing iris bombe and total posterior synechiae plastering the iris to the crystalline lens.



Sequelae and Complications of Iridocyclitis

2. **Secondary glaucoma:** Occurs due to occlusio pupillae and total posterior synechiae where the circulation of aqueous is blocked, or due to peripheral anterior synechiae in chronic cases.
3. **Complicated cataract:** Occurs in chronic cases and may be secondary to prolonged use of corticosteroids.
4. **Cystoid macular edema:** Due to the effect of inflammatory mediators on the retinal vessels.
5. **Cyclitic membrane:** May form behind the lens due to organization of exudates and vascularization from the ciliary body. Contraction of the membrane could result in ciliary body detachment with decreased aqueous secretion leading to hypotony and ending with atrophía bulbi. Tractional retinal detachment may also occur.
6. **Tractional retinal detachment.**

Diagnosis of iridocyclitis:

An etiologic diagnosis is reached by investigations and laboratory tests:

1. Careful history taking.
2. Careful ocular and systemic examination.
3. **Laboratory investigations:**
 - a. Sarcoidosis: Chest x-ray and angiotensin-converting enzyme.
 - b. Arthritis: X-ray, HLA-B27, rheumatoid factor (RF), antinuclear antibodies (ANAs).
 - c. Full blood picture (total & differential leucocytic count, ESR)
 - d. Immunological tests such as HLA testing (for ankylosing spondylitis, Behcet's disease, histoplasmosis), RF for rheumatoid arthritis and ANAs for lupus.
 - e. Syphilis: Wassermann test and VDRL.
 - f. Toxoplasmosis: Complement fixation test.
 - g. T.B: Chest X-ray and tuberculin test.
4. **Radiological examination (medical imaging):**
 1. Chest X-ray.
 2. CT scanning.
 3. Nasal Sinus X-ray films.
 4. X-ray for hands and feet (arthritic changes).
 5. Magnetic Resonance Imaging: For multiple sclerosis.
5. **Ultrasonography:** To evaluate the posterior segment.
6. **Ocular tissue sampling:** Conjunctival biopsy, AC aspiration for cytology, vitreous aspirate for cytology and PCR.

Treatment of iridocyclitis:

I. Local Treatment:

1. Atropine sulphate:

- It is the most important line of treatment.
- 1-2% drops in adults and 1% ointment in children. Eye drops should be avoided in children to avoid systemic toxicity. It is used 3 times daily.
- Atropine relieves pain and headache from ciliary spasm, dilates the pupil and prevents posterior synechiae, and decreases exudation from the iris vessels.

➤ **Atropine Toxicity (over dose):**

Toxicity is due to systemic absorption. Atropine ointment is thus indicated to decrease the possibility of systemic absorption.

Manifestations:

1. Fever.
2. Flushing of the face.
3. Tachycardia.
4. Fits (CNS excitement).
5. Dry mouth and Skin.

Treatment:

1. Stop Atropine,
2. Cold compresses,
3. Pilocarpine 10 mg IM (anti-dote).

➤ **Atropine sensitivity (allergic reaction to atropine):**

This may occur at any age and may occur with drops or ointment.

Manifestations:

Allergic dermatitis and follicular conjunctivitis.

Treatment:

1. Stop Atropine and give Cyclopentolate instead.
2. Give local steroids.

- Prolonged use of atropine may lead to dry eye.

Dangers of Mydriatics:

1. Angle closure glaucoma in patients with narrow angle.
2. Prevents monitoring of the pupil in patients with concussion.
3. Prevents monitoring the pupil during anesthesia.
4. Cyclopentolate hydrochloride: Has been associated with psychotic reactions and behavioral disturbances (ataxia, hallucinations) especially in children.

2. Corticosteroids:

- Prednisolone acetate 1% or Dexamethasone phosphate 0.1% in the form of drops or ointment.
- Used frequently every 1-2 hours in the acute stage and tapered gradually.

Dangers of local steroids:

1. Steroid induced glaucoma.
2. Steroid induced cataract (posterior sub-capsular).
3. Increasing susceptibility to infections.
4. Reactivation of dormant organisms e.g. herpes virus.
5. Delaying wound healing.

3. Hot Fomentations: Decrease pain and improve the circulation.

4. Dark glasses: To decrease photophobia.

II. Systemic treatment:

1. Systemic steroids:

Indicated in severe cases and in large doses, usually 60-80 mg/day (1mg/kg/day). Tapering should be gradual to avoid relapses.

Contraindications:

A. Local:

1. Ocular infections.
2. Corneal ulcers.
3. Glaucoma.

B. Systemic:

1. Infective cases (unless given under a good cover of antibiotics).
2. Diabetic patients (corticosteroids are diabetogenic).
3. Cardiac disease.
4. Renal disease (salt and water retaining effect).
5. Pulmonary Tuberculosis.
6. Peptic ulcer.
7. Arterial hypertension.
8. Pregnancy.
9. Malignancy.

Dangers of systemic steroids (prolonged use):

1. Peptic ulceration.
2. Steroid induced diabetes.
3. Hypertension due to salt and water retention.
4. Steroid induced cataract.
5. Muscle wasting, osteoporosis.
6. Reactivation of dormant infections (T.B).

7. Cushingoid state.
8. Psychic disturbances.
9. Sudden stoppage after prolonged use may lead to acute adrenal insufficiency, so either gradual withdrawal or injection of adrenocortico-trophic hormone (ACTH) is given at the end of treatment.

2. Non-steroidal anti-inflammatory drugs (NSAIDs):

- NSAIDs (Diclofenac, Ketorolac) inhibit prostaglandin synthesis.
- They are given in combination with corticosteroids or as a substitute if steroids are contraindicated.

3. Antibiotics:

- Used in infective cases, e.g. post-operative or post-traumatic endophthalmitis, and in bacterial infections such as syphilis and tuberculosis.

4. Analgesics (Salicylate).

5. Immunosuppressive drugs:

- Examples of immunosuppressive drugs include Cyclosporine and Chlorambucil.
- They are used in steroid-resistant cases e.g. in some cases of Behcet's disease.

III. Treatment of Complications:

1. Secondary glaucoma:

- In the acute stage:
 1. Carbonic anhydrase inhibitors.
 2. Beta-blockers are given.
 3. In addition to treatment of iridocyclitis. Atropine treatment is not stopped.

- In the chronic stage:

There may be ring synechiae causing pupillary block glaucoma, which can be treated by:

- a. Peripheral iridectomy. If peripheral anterior synechiae develop,
 - b. An external fistulizing operation is required to treat the glaucoma.
- 2. Complicated cataract:** Guarded removal of the cataract after subsidence of signs of iridocyclitis for at least 6 months.
 - 3. Cyclitic membrane:** Can be removed by vitrectomy (through pars plana) if light projection is good.
 - 4. Blind painful eye:** Enucleation or retrobulbar injection of alcohol.

(II) Chronic Iridocyclitis

- ❖ It is an extremely chronic disease with marked diminution of vision.
- ❖ It is of gradual progressive course with exacerbations and remissions.
- ❖ It may be granulomatous or non-granulomatous.

Symptoms:

- Mainly gradual diminution of vision with mild pain (little symptoms).

Signs:

1. Ciliary injection.
2. Tenderness over ciliary body region.
3. Deep or funnel-shaped anterior chamber due to posterior synechiae.
4. Muddy iris with white atrophic patches.
5. Keratic precipitate may be large (mutton fat) in granulomatous uveitis or smaller in non-granulomatous uveitis.
6. Dust-like opacities in the vitreous.

7. Hypertensive iridocyclitic crisis (of Posner and Schlossman): The eye may appear normal but periodically, acute or sub acute attacks of glaucoma occur with aqueous flare and Keratic precipitate.

Complications of chronic iridocyclitis:

1. Band shaped keratopathy (horizontal strip of degeneration and calcium deposition in superficial middle corneal stroma).
2. Sclerosing kerato-uveitis (infiltrations involving the cornea, sclera and uveal tract in a triangular manner).
3. Synechiae formation (see before).
4. Rubeosis iridis and neovascular glaucoma.
5. Iris atrophy.
6. Iris nodules e.g.
 - Koeppe nodules in tuberculosis.
 - Busacca nodules in syphilis.
7. Complicated cataract.
8. Secondary glaucoma.
9. Phthisis bulbi: Small shrunken soft globe due to cessation of aqueous secretion. Ocular structures can not be differentiated.

Differential Diagnosis of phthisis bulbi:

Atrophia bulbi: In which ocular structures can be differentiated.

In both conditions the eyeball is small with no perception of light.

Posterior Uveitis (choroiditis)

Clinical Forms:

- (A) Non suppurative choroiditis.
- (B) Suppurative choroiditis.

(A) Non - suppurative choroiditis

- It may be granulomatous or non granulomatous (exudative).

Symptoms:

1. Diminution of vision (due to retinal lesions and vitreous opacities).
2. Photopsia (flashes of light) due to retinal irritation.
3. Metamorphopsia (due to retinal edema).
4. Micropsia or macropsia.
5. Scotoma.

Signs:

1. One or more yellowish areas with ill-defined edges are seen deep to retinal vessels by fundus examination.
2. Black spots are seen floating in the vitreous.
3. In the healing stage yellowish area become white with pigmentation in the margin.

(B) Suppurative choroiditis

The infection may be endogenous or exogenous and may lead to endophthalmitis or panophthalmitis.

A. Endophthalmitis:

Endophthalmitis is a purulent inflammation of the intraocular tissues in response to infection (exogenous or endogenous), trauma, immune reaction, physical or chemical changes, vasculitis or neoplasm. The inflammation is confined to the intraocular structures, but the outer coat of the eye (cornea, sclera) and Tenon's capsule are free.

Clinical picture:

1. Pain (neuralgic).
2. Ciliary injection.

3. Lid edema.
4. Diminution of vision, often with corneal edema (down to PL).
5. Anterior chamber reaction (hypopyon).
6. Vitreous reaction (inflammatory cells).

Management of bacterial endophthalmitis:

- 1) Hospitalization.
- 2) Vitreous aspiration for smears (Gram and Giemsa), culture and sensitivity test.
- 3) Anterior chamber paracentesis (aspiration of aqueous) for smears, culture and sensitivity test.
- 4) Antibiotics: Can be given by the following routes:

a. Intravitreal:

1 mg of Vancomycin (to cover gram-positive organisms), plus 2.25 mg of Ceftazidime or 0.4 mg of Amikacin (to cover gram-negative organisms).

b. Subconjunctival:

- 25 mg of Vancomycin.
- 100 mg of Ceftazidime or 20 mg of Amikacin.

c. Topical:

- Vancomycin drops 50 mg/ml.
- Ceftazidime drops 50 mg/ml or fortified Gentamycin drops 15 mg/ml.

d. Systemic:

Amikacin 14mg/Kg IV or IM every 8 hours for 5 days or Ciprofloxacin 500mg every 12 hours for 5 days.

Monitoring kidney functions from fear of nephrotoxicity of antibiotics.

- 5) Topical and /or systemic steroids may be added at least 24 hours after starting intensive antibiotic therapy.
- 6) Vitrectomy in addition to the above treatment is done in severe cases not responding to other measures.

Management of fungal endophthalmitis

1. Evaluation as in bacterial endophthalmitis.
2. Amphotericin B systemically, intravitreally and topically.

B. Panophthalmitis:

In panophthalmitis, the inflammation extends to involve all the ocular tissues including the outer coat, Tenon's capsule and the orbit.

Symptoms:

1. Severe pain.
2. Loss of vision (no PL).
3. General signs of infection (fever, malaise, rapid pulse).

Signs:

1. Proptosis.
2. Limitation of eye movement in all directions.
3. Severe edema of the lids and conjunctiva.
4. Abscess of the cornea.
5. Hypopyon in the anterior chamber.
6. Yellow reflex due to pus in the vitreous.
7. Pus bursts through the cornea.
8. Extension to the cavernous sinus is a risk.

Differential Diagnosis:

1. Endophthalmitis.
2. Panophthalmitis.
3. Orbital cellulitis.
4. Cavernous sinus thrombosis.

Treatment:

1. Extensive antibiotics both systemically and locally (Vancomycin, Gentamycin, Ceftazidime, Ciprofloxacin, Amikacin).
2. Evisceration may be needed (excision of the cornea, curettage of all structures inside the sclera).

Tumors of the uveal tract

A) Benign tumors:

1. Benign melanoma: Common in the iris.
2. Haemangioma: In the choroid mainly.
3. Neurofibroma: In the choroid mainly.

B) Malignant tumors:

1. Malignant melanoma: In the choroid mainly.
2. Epithelioma: In the ciliary body mainly.

Malignant Melanoma of the Choroid

It is the most common primary intraocular tumor in adults. The average age of patients with choroidal melanoma is 50 years. It is rare in black races.

Clinical picture:

The tumor appears as a unilateral, elevated, brown oval shaped mass. It may be mottled with dark brown or black pigments.

1. Early it may be asymptomatic (**Quiescent**) unless it arises near the macular area. Later the patient may complain of diminution of vision due to secondary retinal detachment (malignant detachment).
2. Secondary glaucoma.
3. Extra ocular extension (in late stages): It may extend outside the globe into the orbit producing proptosis.
4. Distant metastases: Liver, lungs, bone, brain.

Diagnosis is based on fundus examination. Many cases are accidentally discovered during routine ocular examination. Fundus photography is important for documentation and follow up. Ultrasonography accurately determines the size and height of the tumor and differentiates malignant melanoma from other tumors e.g. choroidal nevus and choroidal hemangioma.

Differential Diagnosis:

1. Malignant melanoma should be differentiated from a choroidal nevus which is benign.
2. Malignant detachment should be differentiated from primary rhegmatogenous retinal detachment.
3. Choroidal melanomas should be differentiated from choroidal secondaries due to metastases. Since metastases are frequently bilateral, examination of the fellow eye is extremely important.

Management:

1. Observation: Should be considered for:

- a. Eyes with small lesions since differentiation from nevus may be difficult.
- b. Single eye with slowly growing tumors.

In these cases regular fundus examinations, documented fundus photographs and ultrasonography are used to detect the tumor height, size and rate of progression.

2. Local resection for small peripheral lesions (choroidectomy).

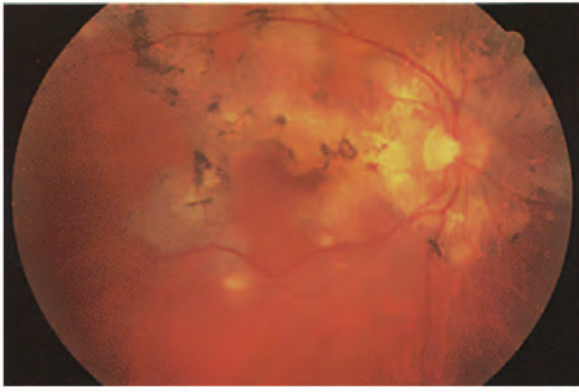
3. Radioactive plaques fixed to the globe may be suitable for small or medium sized tumors near the posterior pole (gamma irradiation).

4. Enucleation is indicated for large melanomas.

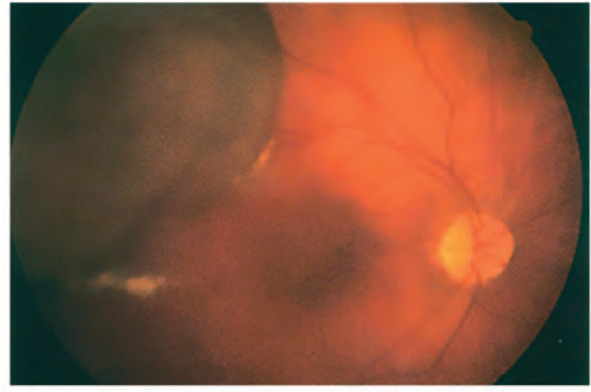
5. External beam irradiation prior to enucleation to lessen the risk of metastatic lesions.

6. Transpupillary thermotherapy (TTT): It is a recent method of treatment. The principle is to apply heat to the tumor tissue after pupillary dilatation using a diode laser. This leads to cellular destruction and inhibition of DNA synthesis by the tumor cells and subsequently decreases in the tumor size.

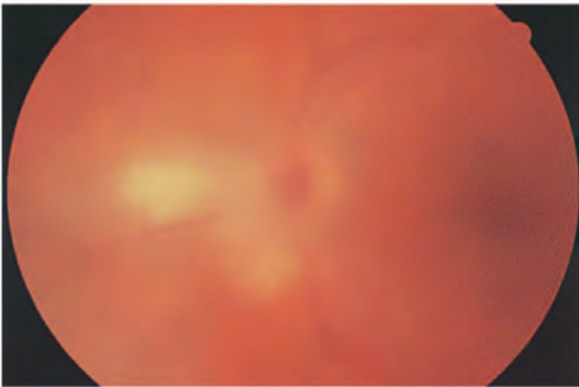
7. Palliative (symptomatic) treatment for distant metastases.



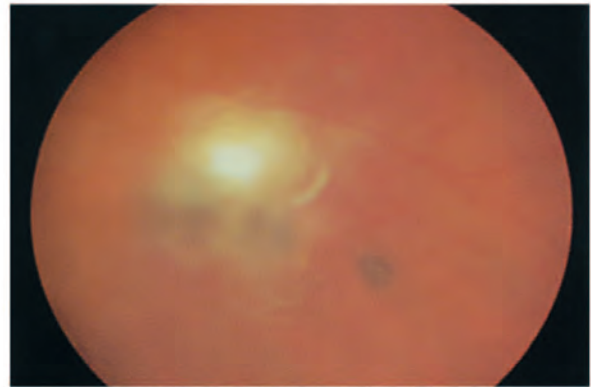
Peripapillary serpiginous choroiditis



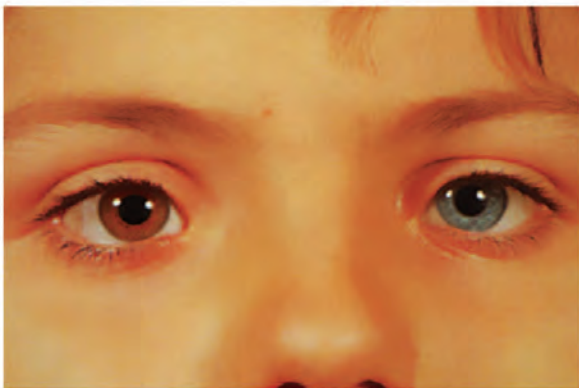
Choroidal melanoma



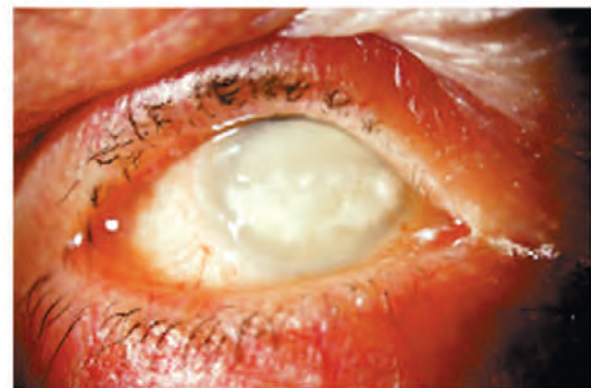
Juxtapapillary chorioretinitis



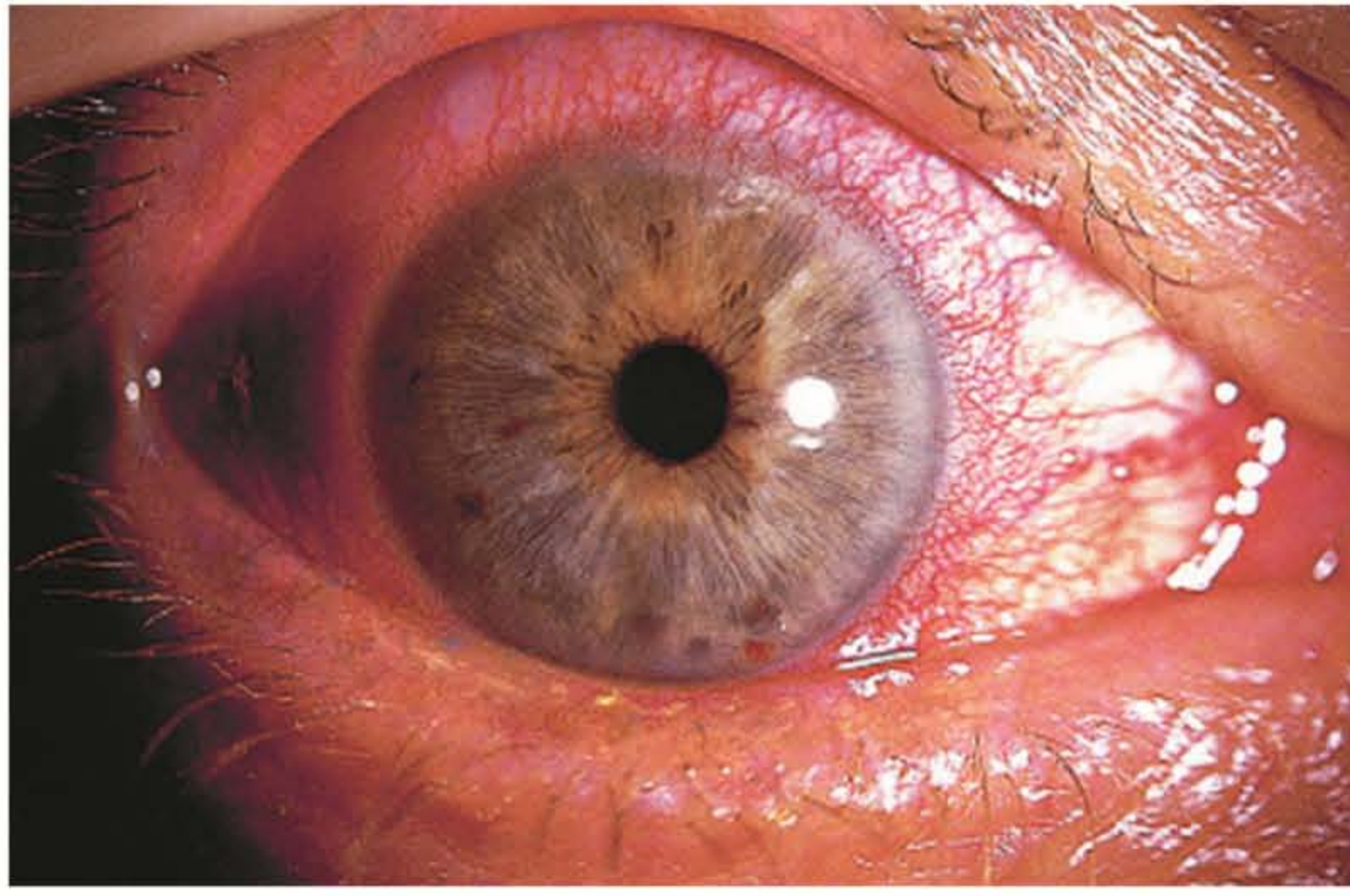
Active retino choroiditis (toxoplasma)



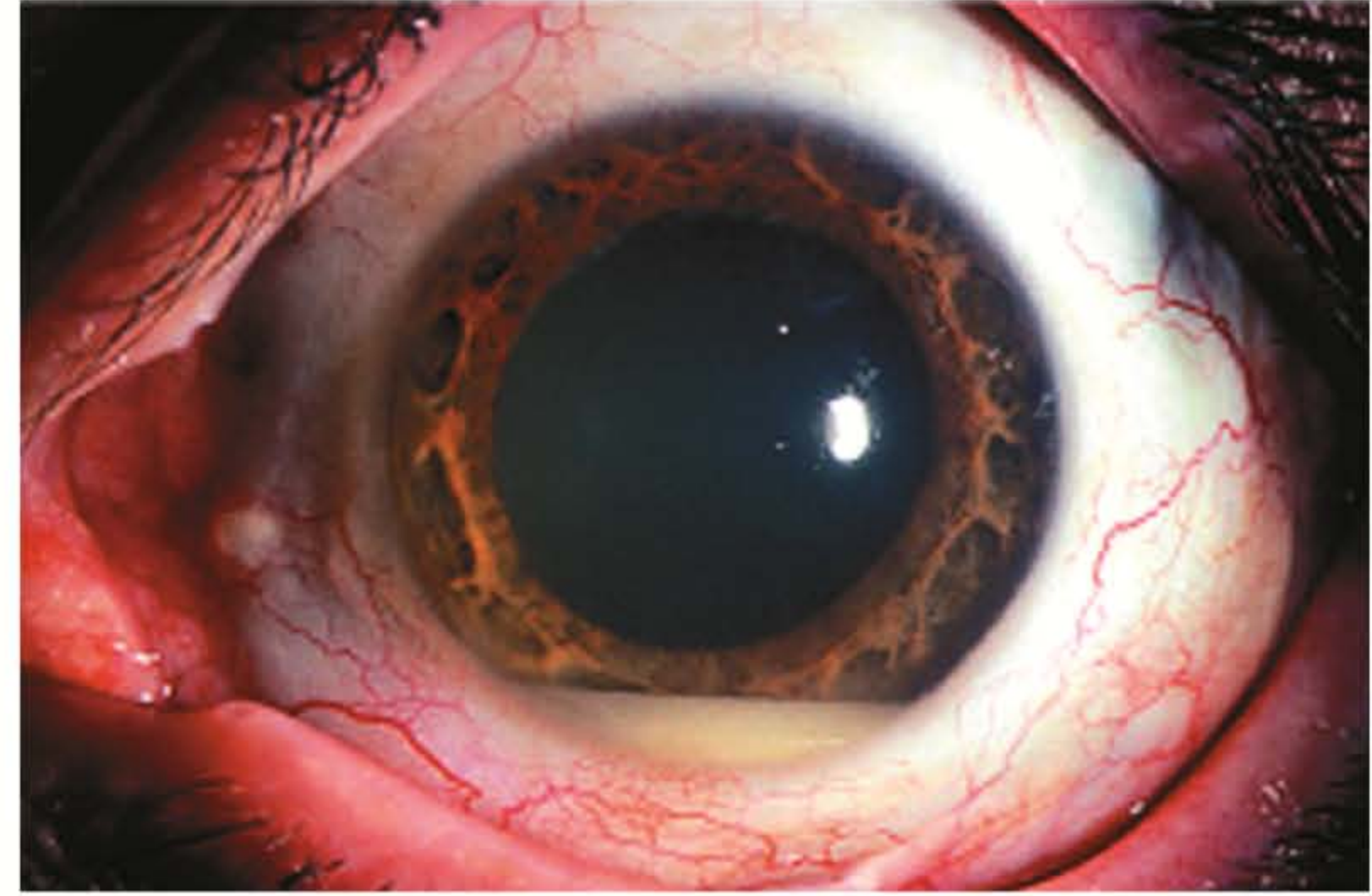
Bilateral heterochromia



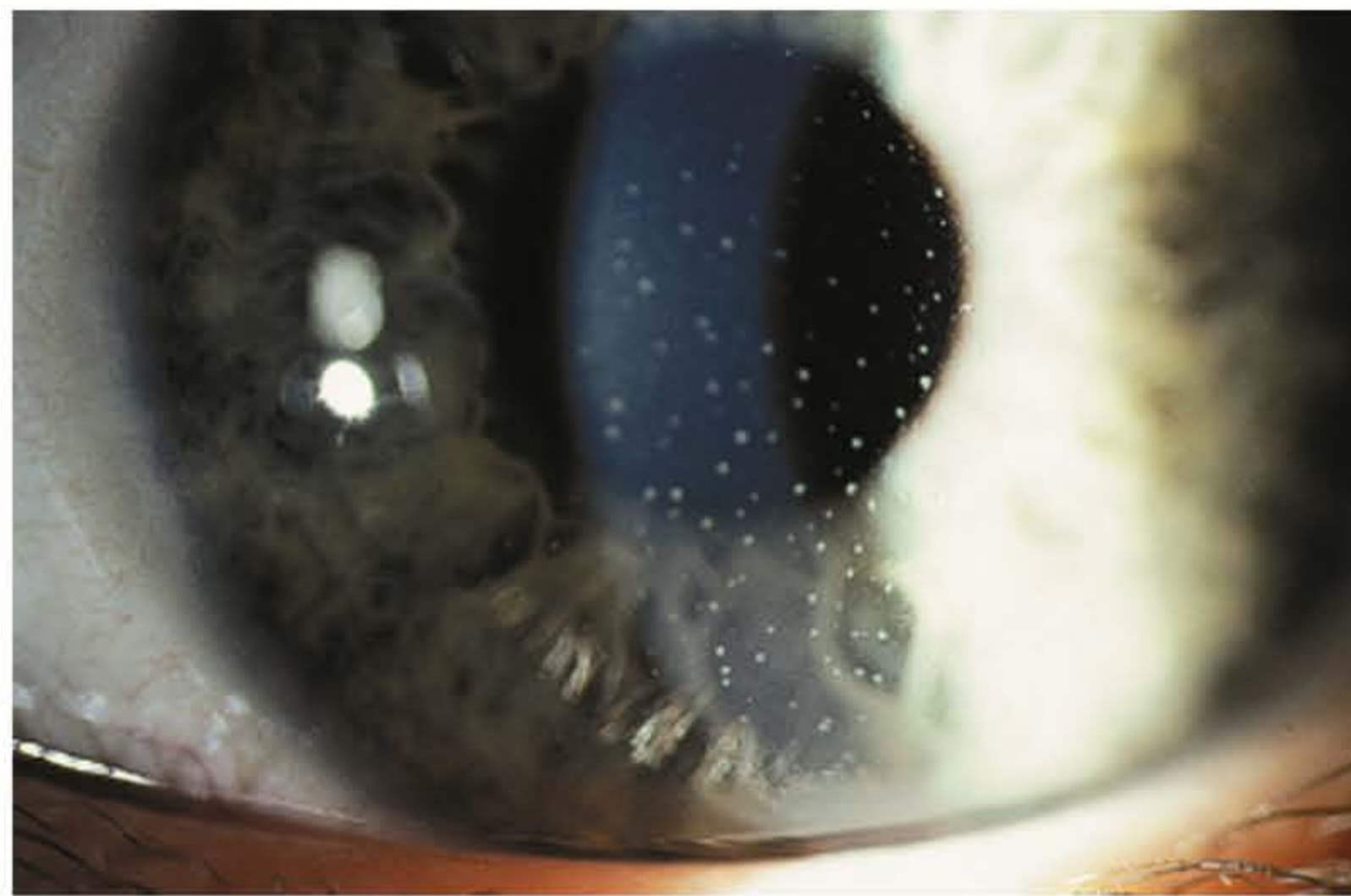
Phthisis bulbi



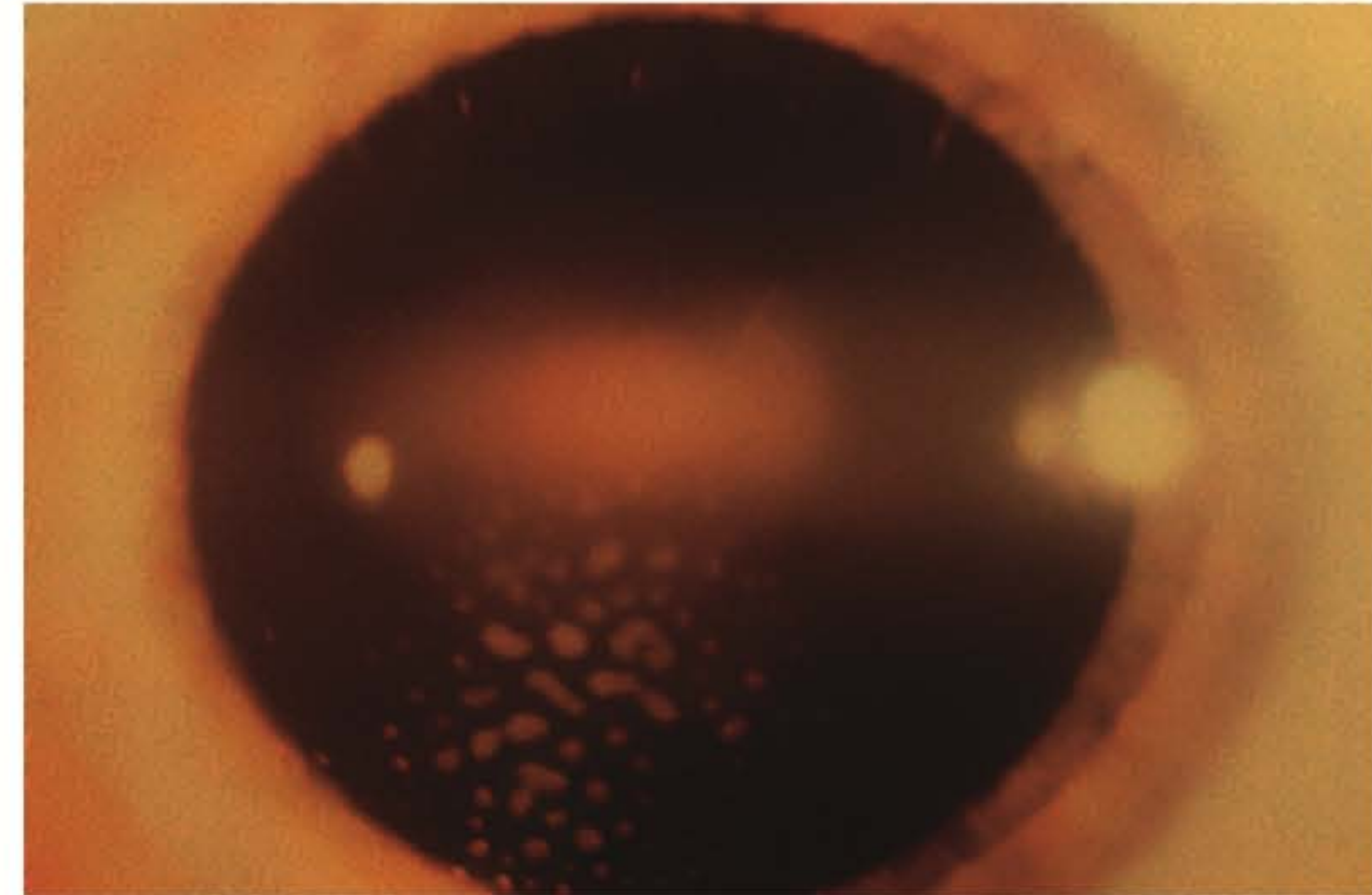
Ciliary injection



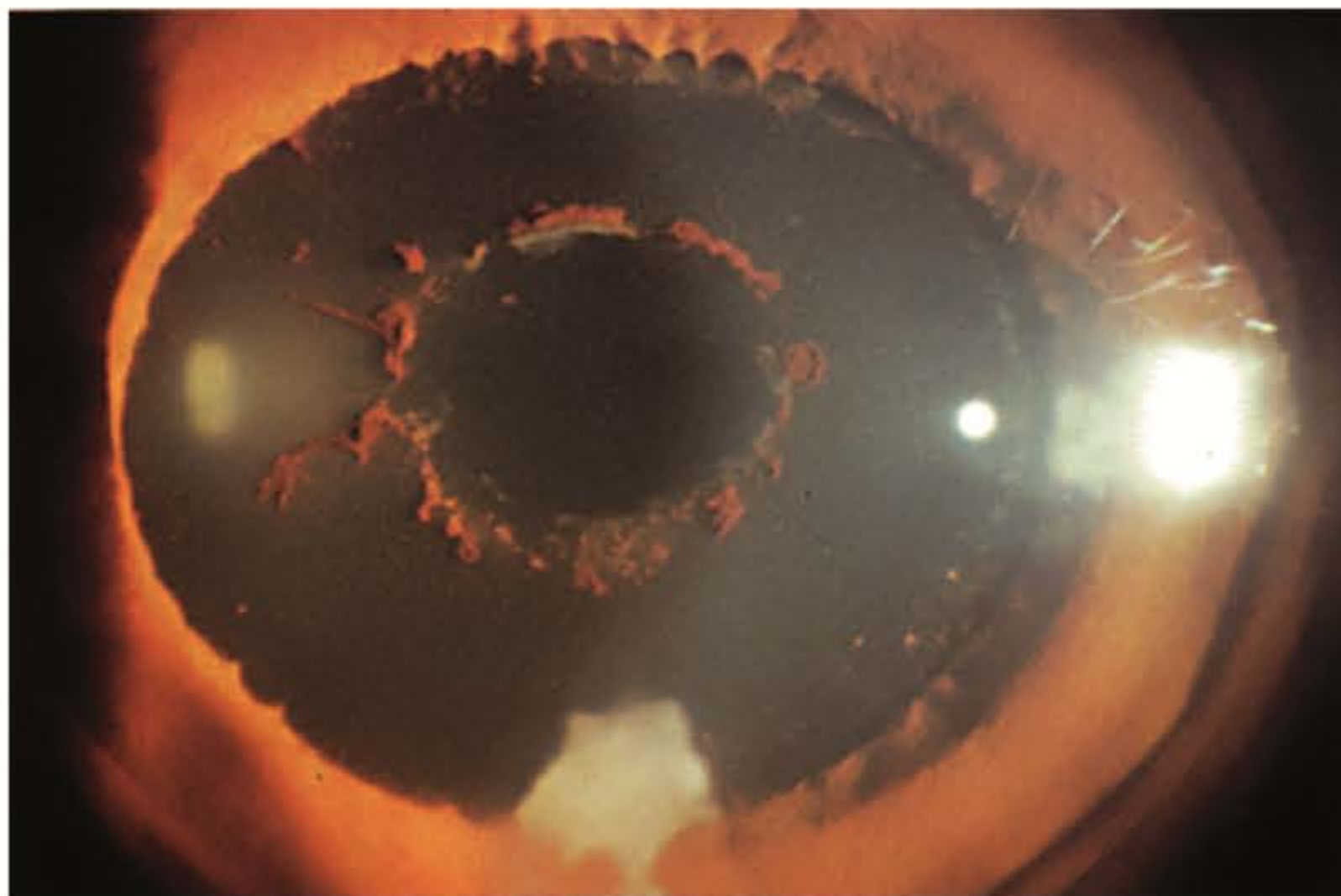
Hypopyon in severe anterior uveitis



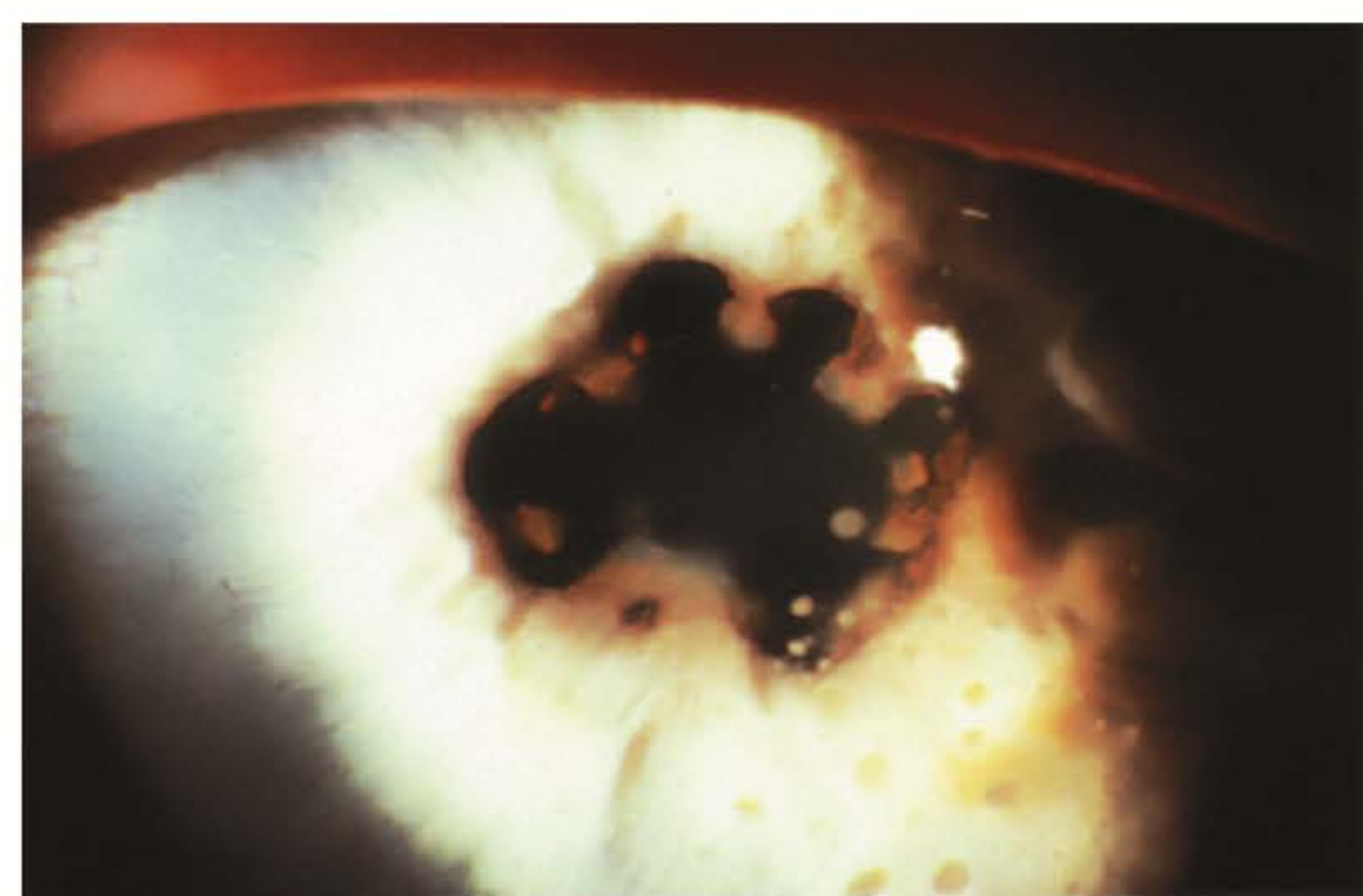
Keratic precipitates



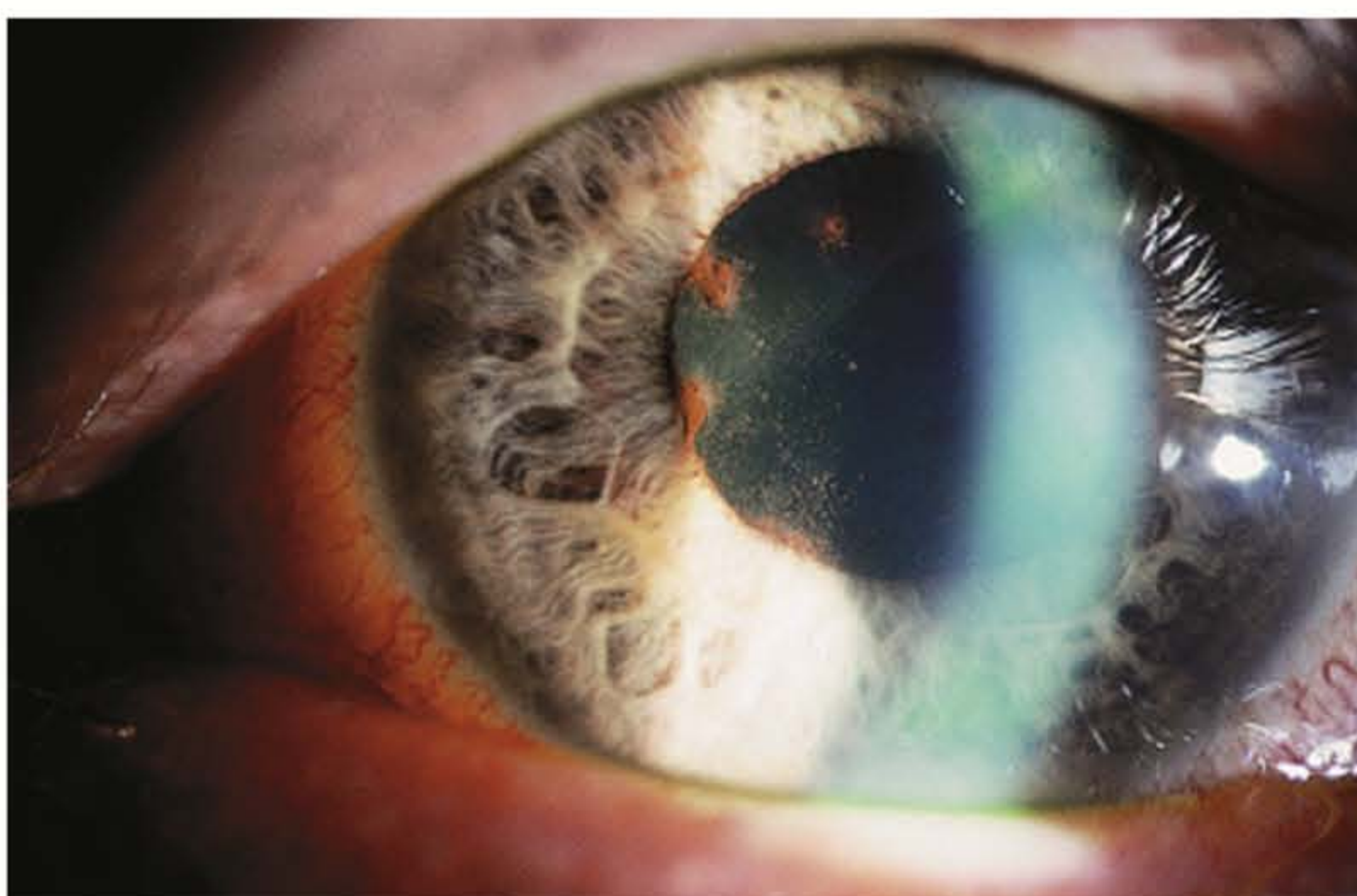Keratic precipitates (mutton fat)



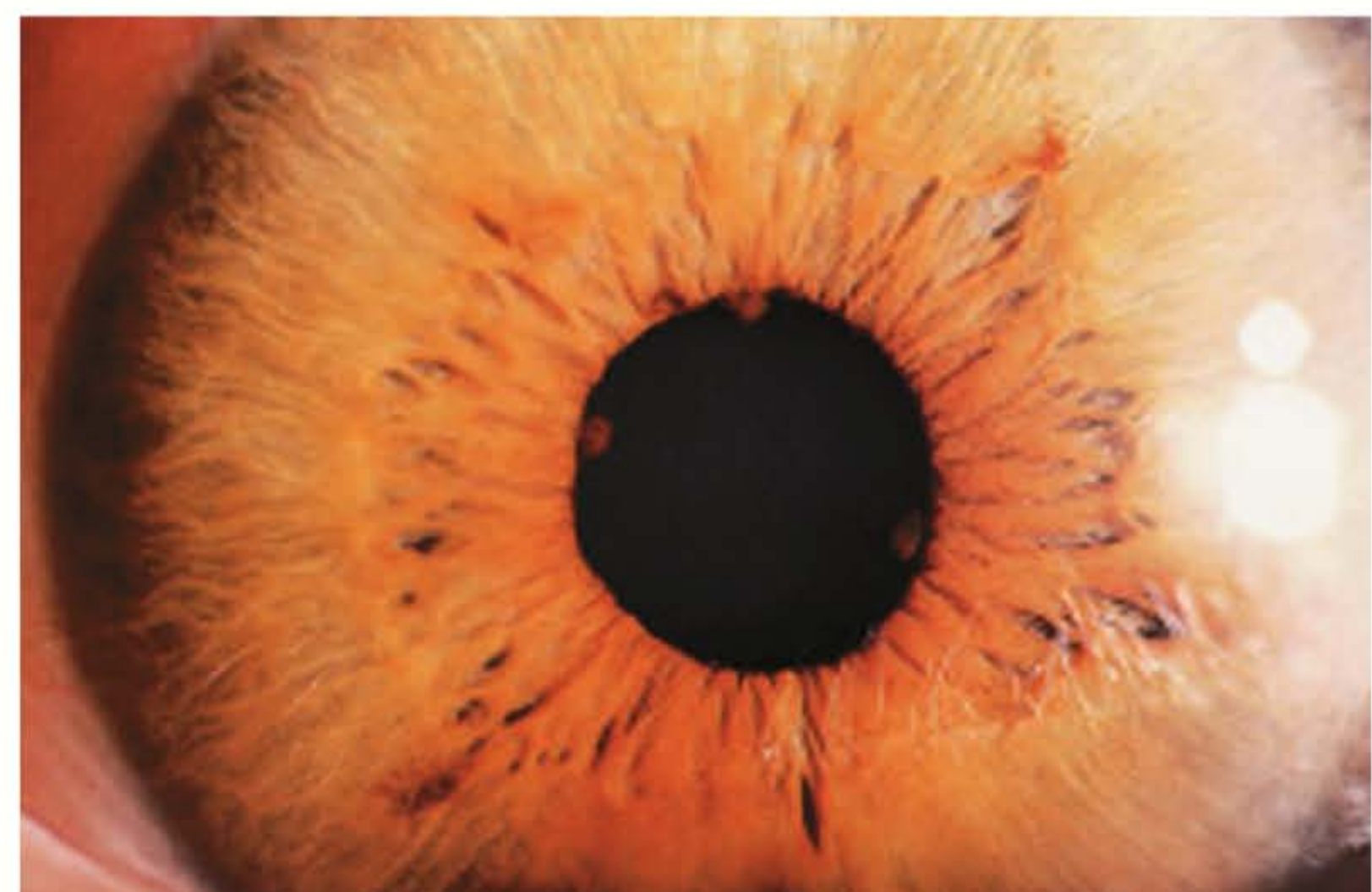Pigment deposition on the anterior lens capsule



Irregular pupil due to posterior synechiae (Festooned)



Posterior synechiae



Koepe nodules (small and situated at the pupillary border)

Chapter 9

Lens

Anatomy

Gross anatomy

1. Transparent, avascular biconvex disc.
2. Relations:
 - Anteriorly: Iris, separated from it by posterior chamber.
 - Posteriorly: Vitreous body, separated from it by retro-lental space.
 - Equatorially: Suspensory ligament (Zonules) which suspend lens in its position and is attached to the ciliary body and to the lens capsule.
3. Measurements:
 - Diameter = 9-10 mm.
 - Thickness = 3-4 mm.
 - Weight:
 - 60 mg at birth
 - 250 mg at age 70
 - Radius of curvature:
 - Anterior surface 10 mm
 - Posterior surface 6 mm
 - Refractive index:
 - Cortex 1.38
 - Nucleus 1.40
 - Refractive power:
 - + 20 D in eye
 - + 60 D in air

Minute anatomy

1. **Lens capsule:** Elastic & non-cellular surrounds the lens.
2. **Lens epithelium:** Single layer which line the anterior lens capsule.
3. **Lens fibers:** Form cortex and nucleus.

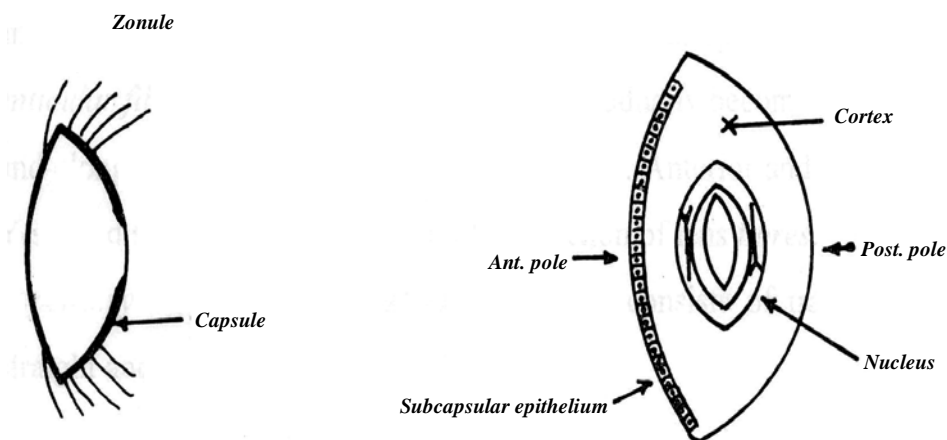
Parts:

1. **Lens capsule:** it is an elastic membrane which is thicker anteriorly.
2. **Cortex:** it lies in between the lens capsule and nucleus. It consists of lens fibers.
3. **Nucleus:** the lens has four nuclei:
 - Embryonic nucleus (1-3 months of gestation),
 - Fetal nucleus (from 3 months of gestation till birth),
 - Infantile nucleus (from birth to puberty) and
 - Adult nucleus (early adult life).

Functions:

The main functions of the lens are:

- 1- Maintain clarity and transparency.
- 2- Provide refractive power to the eye.
- 3- Provide accommodation for near vision.
- 4- Absorption of harmful ultraviolet light.



Anatomy of Crystalline Lens

Diseases of the Lens

Cataract

Definition: Cataract is opacification of the crystalline lens.

Classification:

1. Etiological:

- Developmental (congenital).
- Senile.
- Traumatic.
- Complicated:
 - Local (ocular).
 - General (systemic).

2. According to age:

1. Soft cataract: Occurs below the age of 25 years. Soft cataract may be congenital, traumatic or complicated. No hard nucleus is present below this age.
2. Hard cataract: Occurs above the age of 30 years. A hard nucleus is present.

3. According to the layer affected:

1. Sub-capsular: Anterior and posterior.
2. Cortical: Anterior and posterior.
3. Nuclear.

Developmental (congenital) Cataract

Definition:

Opacities in the lens discovered at birth or in the early years of life.

Etiology:

1. Hereditary.
2. Intrauterine infections especially rubella (German measles).
3. Metabolic e.g. galactosemia.
4. Malnutrition (Iron & calcium deficiency).

Morphologic Types:

1. Anterior Polar Cataract

It is due to delayed formation of AC in the intra-uterine life leading to long contact between the lens and the cornea. Usually it has little effect on vision.

It may be: Pyramidal – reduplicated – hour glass or collar stud.

2. Posterior polar cataract

Caused by remnants of the hyaloid artery, it appears as a small disc shaped opacity at the posterior pole. Vision is affected as the opacity is situated near the nodal point of the eye.

3. Lamellar (Zonular) Cataract

Lens opacification involving one or more layers of lens. The rest of the layers are clear, it appears as a central white disc with spokes like a steering wheel of a ship.

4. Total Cataract

Following rubella infection to the mother in the first trimester. It is usually associated with heart anomalies and other congenital anomalies.

5. Coronary Cataract

A ring of pear-shaped or oval opacities with their apices pointing peripherally seen in the cortex near the equator. It does not affect the vision.

6. Punctate or Blue-Dot Cataract

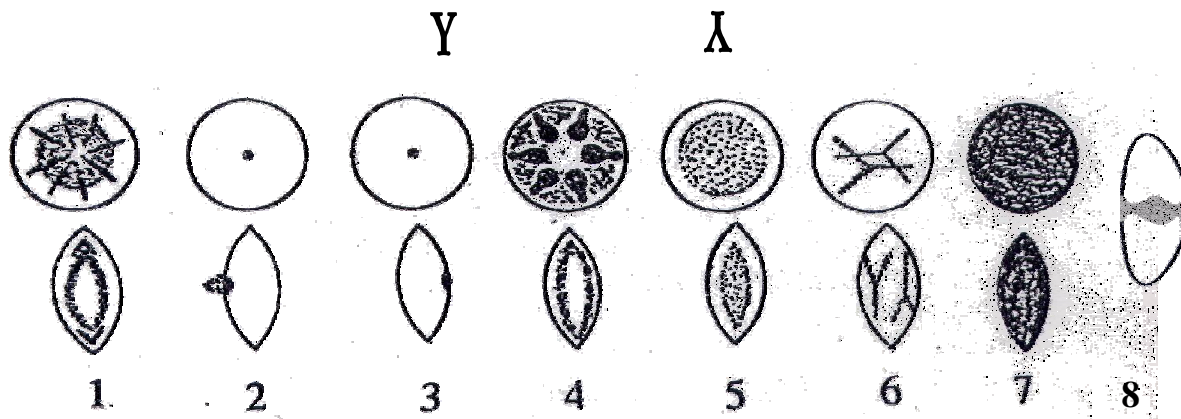
Multiple small bluish dots with no visual affection.

7. Fusiform Cataract (coralliform)

Antro-posterior spindle shaped opacity.

8. Discform Cataract

9. Sutural; either anterior or posterior



Types of congenital cataract

1. Zonular. 2. Anterior polar (and pyramidal). 3. Posterior polar. 4. Coronary.
5. Punctate (blue-dots). 6. Sutural. 7. Total. 8. Fusiform.

Clinical picture:

Symptoms: Usually given by the mother who may notice:

- A white pupil (leukocoria).
- Defective vision of her baby.

Signs:

1. Opacity of the lens may be seen.
2. Fundus should be carefully examined to exclude retinal anomalies.

Investigation:

1. Visual assessment could be done by preferential looking test or visual evoked potentials (VEP).
2. Appropriate lab tests should be ordered if a metabolic cause is suspected e.g. galactosemia.

Complications:

Bilateral dense opacities may lead to nystagmus.

Unilateral opacity may lead to amblyopia and squint.

Treatment:

Early restoration of vision in a child with cataract is very important to avoid amblyopia and nystagmus.

Factors governing surgical treatment:

1. Before 3 years: depends on the density of cataract (As seen by Ophthalmoscopy).
If you cannot see the fundus details through a dilated pupil this is an indication for surgery.
2. After 3 years: depends on visual acuity test
 - a- If vision is 6/18 or more there is no need for surgery because this amount of vision with accommodation is better than good visual acuity without accommodation.
 - b- If vision is $< 6/18$ it is better to do surgery early.

Surgical technique & visual rehabilitation:

1. Techniques:

- a- Irrigation & aspiration of lens matter through anterior segment followed by anterior vitrectomy.
- b- Lensectomy & vitrectomy through pars plana using vitrectomy probe.

2. Visual rehabilitation:

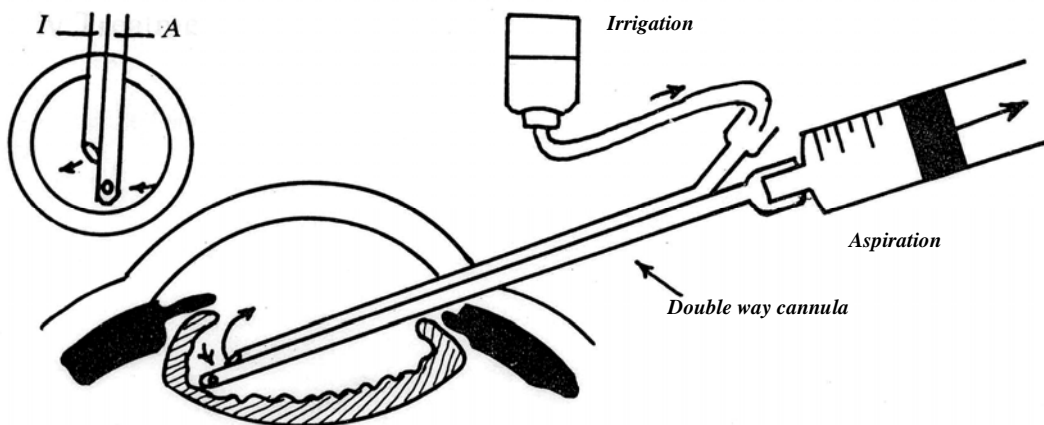
As early as possible after surgery. There are several methods depending on age:

(a) Before one year:

- Postoperatively: Contact lenses for unilateral or bilateral cases and glasses for bilateral cases only.
- Later on: Secondary implantation of intraocular lenses.

(b) After one year:

- Primary implantation of intraocular lenses.
- Treatment of amblyopia (see under strabismus).



Irrigation aspiration of Soft Cataract

Senile Cataract

Definition: It is a bilateral progressive opacification of the lens affecting old people above 50 years as an ageing process

Etiology: Unknown, however it may be due to:

1. Disturbance of permeability of the capsule.
2. Disturbed lens metabolism: There is reduction of oxygen uptake and an initial increase in water content.
3. Effect of ultraviolet rays.
4. Endocrinal disturbance due to age.

Pathogenesis: The lens undergoes:

1. Hydration: Water drops appear within the lens.
2. Coagulation of lens proteins, which leads to opacification of the lens fibers.

Symptoms of senile cataract:

1. Gradual painless progressive diminution of vision.
2. Progressive myopia (due to increased refractive index of the nucleus).
3. Fixed black spots in the visual field.
4. Impaired night vision in cortical cataract.
5. Impaired day vision in nuclear cataract.
6. Uniocular diplopia or polyopia (due to irregular refraction by scattered lens opacities).
7. Colored halos around light (due to fluid droplets inside the lens in the early stages).

Signs of Senile Cataract:**(I) Senile nuclear cataract:**

1. The lens opacity mainly affects the nucleus.
2. Normally the nucleus undergoes a process of physiologic sclerosis with age, with gradual decrease of water content and increase in refractive index resulting in index myopia.
3. In nuclear cataract, the nucleus loses its transparency and affects vision. The nucleus may acquire a yellowish and later brownish or black color due to deposition of melanin and tryptophan-derived pigments.
4. The red reflex is normal in physiologic lens sclerosis, but in senile nuclear cataract it appears as a dark central area with a clear rim of red reflex.

Table (7): Difference between senile nuclear sclerosis and nuclear cataract

	Nuclear sclerosis	Nuclear cataract
Cause:	Due to exaggerated physiological nuclear dehydration.	Due to pathological nuclear dehydration with opacification.
V.A.	Can be corrected by glasses to normal.	Can't be improved by glasses.
Oblique illumination:	Grayish appearance of the nucleus due to increased reflections.	Grayish brownish or blackish nucleus opacification.
R.R.	All red.	Black centre on a red peripheral R.R.
TTT:	Glasses.	Surgical if indicated.

(II) Cortical cataract:

The lens opacity mainly affects the cortex and can morphologically be divided into the following clinical stages:

1. Immature stage: Which mean that the lens is not totally opaque and further divided into:

a. Incipient: The lens is almost clear with the presence of some opaque fibers so the vision is good. Vision ranges between 6/6 to 6/9.

Cataract may be cuneiform (anterior cortical wedges of opacity) or cupuliform (a sheet in the posterior cortex).

b. Immature: Almost complete sheet of opaque lens with clear lens fibers under anterior capsule.

- Red reflex is seen with difficulty and iris shadow is present.

Intumescent cataract: In some cases the lens becomes swollen because it draws water from the aqueous. The lens opacifies rapidly and vision drops markedly. The AC becomes shallow. The lens capsule appears glistening and 2ry angle closure glaucoma may occur due to block of the pupil by the swollen lens (Phacomorphic glaucoma).

2. Mature Stage: The lens becomes totally opaque and vision drops to hand movement. The red reflex is absent.

3. Hypermature Stage: The lens is totally opaque and may appear in two forms:

a. Dry type: The lens loses water and shrinks. The capsule is thickened, wrinkled and calcium particles are deposited on the capsule. The AC becomes deep and the iris becomes tremulous. The escaping lens proteins in the aqueous excite a phagocytic response. The swollen macrophages may get trapped in the trabecular meshwork causing 2ry open angle glaucoma (Phacolytic glaucoma).

b. Wet type (Morgagnian cataract): In which the cortex becomes soft, liquefied and milky and the nucleus sinks to the bottom of the capsule.

Complications of hypermature cataract:

1. Phacolytic glaucoma.
2. Endophthalmitis Phaco-anaphylactica.
3. Phacotoxic uveitis.
4. Subluxation or dislocation of the lens.

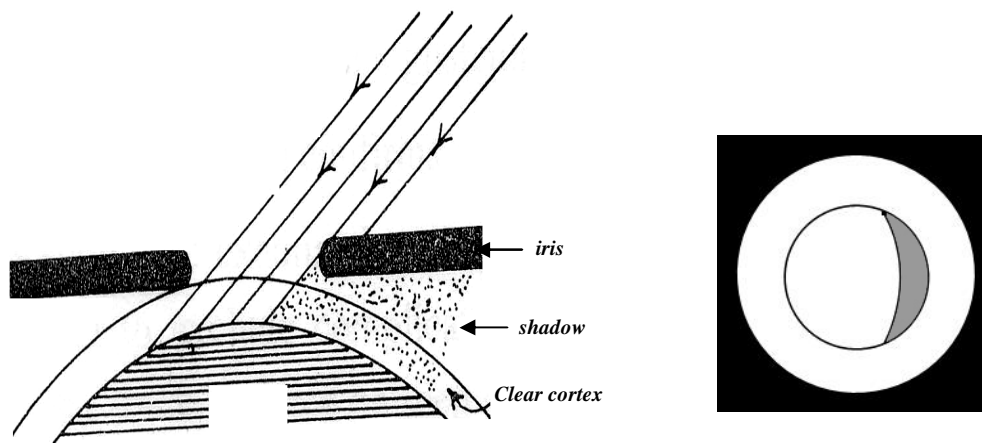
Table (8): Types of senile cortical cataract

	Immature	Mature	Hypermature
Vision	More reduced	H.M	H.M
Anterior chamber	Normal	Normal	Deep
Iris	Normal	Normal	Tremulous
Lens	Partially opaque	Almost opaque	Shrunken & completely opaque
Capsule	Normal	Normal	Thickened
Red reflex	Could be seen	Absent	Absent
IOP	Normal	Normal	Phacolytic glaucoma

Iris shadow is the shadow of the iris on the lens opacity. It is present in immature cataract and becomes smaller as the cataract approaches maturity. To see it, light is thrown obliquely (45°) onto the iris and the shadow of the latter will be seen on the opacity of the lens. (The deeper the opacity the bigger is the shadow). As the last fibers to become opaque are the sub-capsular ones, absence of the shadow indicates that the sub-capsular fibers are opaque which means that the whole lens is opaque i.e. mature stage.

Occasionally the shadow is seen in the hypermature stage because the lens shrinks and become separated from the iris by a distance. The shadow can only form if a clear interval intervenes between the iris and the opacity. In the immature stage this interval is occupied by clear lens fibers but in the hypermature stage it is occupied by aqueous.

The R.R. is a more reliable method in estimating maturity of cataract, than the iris shadow.



Iris Shadow

Examination of senile cataract:

(A) General:

1. Search for septic foci teeth, ear, nose & throat.
2. Urine analysis sugar, pus cells & albumin.
3. Examination of CVS.
4. Examination of chest.

(B) Ocular:

1. Visual acuity.
2. Lids should be examines for rubbing lashes, blepharitis, stye or chalazion.
3. Regurgitation test for assessment of lacrimal sac.
4. Conjunctival swab.
5. Slit-lamp examination to assure:
 - a- No signs of iridocyclitis.
 - b- Well reactive pupil (good test for optic nerve function.
 - c- Type of cataract.

6. Ophthalmoscopic examination:

Fundus should be examined to diagnose any retinal or optic nerve disease.

When the fundus cannot be seen as in mature cataract we resort to retinal function test.

7. Retinal function tests:

a- Light projection to test retinal periphery.

b- Color perception to test macula.


8. Ultrasonography when cataract is total.

Differential Diagnosis of senile cataract:

1. Other causes of gradual painless progressive diminution of vision e.g. open angle glaucoma, primary optic atrophy, senile macular degeneration and progressive myopia.

2. Other causes of muscae volitantes: (fixed in senile cataract).

3. Senile nuclear sclerosis: (red reflex is totally seen with no iris shadow).

**Senile Cataract****Treatment:**

When the visual acuity of the patient interferes with his normal daily activities, surgical removal of the opacified lens is the only line of treatment. This largely depends on the individual needs of the patient.

Surgical Techniques:

1. Extra-capsular cataract extraction (ECCE): This is the standard technique.

The central area of the anterior lens capsule is removed. The hard nucleus is then removed and the cortical lens matter is aspirated leaving the posterior capsule behind to support an intra-ocular lens implantation. In this case iridectomy is not indicated.

❖ Methods of hard nucleus removal:

1. Delivery through a large incision (10-12 mm) at the cornea or at the limbus.
2. Phacoemulsification: The hard nucleus is emulsified using a special ultrasound machine. The nucleus is then aspirated. The procedure is done through a 3mm corneal or limbal incision.

❖ Implantation of an intraocular lens:

Removal of the cataractous lens leaves the patient with a high error of refraction (Aphakia). To compensate for the error, an IOL is implanted and the condition is now called pseudophakia.

Sites of Implantation:

- (a) Bag supported: Best location of IOL.
- (b) Sulcus supported.
- (c) Iris supported.
- (d) Angle supported: In anterior chamber.

Materials of IOL:

- (a) Rigid IOL: Made of PMMA and implanted through large incision.
- (b) Foldable IOL: Made of silicone or acrylic and implanted through small incision.

Primary IOL implantation is usually done at the same time of the cataract surgery and secondary IOL implantation is done at a later time.

Indication of IOLs:

- (a) In cataract surgery: To replace the cataractous lens
- (b) In refractive surgery (phakic IOLs): To correct high refractive errors that cannot be corrected by other methods.

IOL power determination:

Appropriate IOL power to achieve emmetropia can be calculated using mathematical formulas based on measuring the keratometric readings of the cornea and the axial length of the globe (biometry).

Posterior Capsule Opacification (PCO)

Following ECCE, with or without IOL implantation, the remaining posterior capsule may opacify. The opacified capsule may be opened using YAG laser (laser capsulotomy).

2. Intra-capsular cataract extraction: The lens is removed within the capsule after zonulysis. In this case an iridectomy is performed to prevent pupillary block. Since there is no posterior capsule left to support a posterior chamber lens, an anterior chamber lens has to be implanted. Intracapsular cataract extraction (ICCE) is rarely used now because it has higher incidence of vitreous loss, retinal detachment and macular edema. Posterior chamber IOL implantation is not possible.

Aphakia

Absence of the crystalline lens in the pupillary area.

Causes:

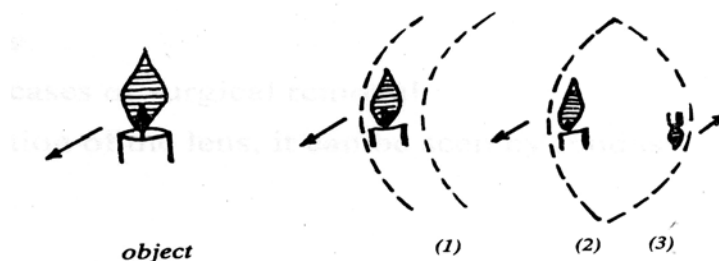
1. Congenital: Very rare.
2. Posterior dislocation (trauma or hypermaturity).
3. Surgical removal.

Signs:

1. Diminished visual acuity.
2. Black pupil.
3. Tremulous iris.
4. Deep AC.
5. One Purkinje-Sanson image is present.
6. Scar of cataract surgery in cases of surgical removal.
7. In case of posterior dislocation of the lens, it can be seen by fundus examination.

Table (9): Purkinje Sanson images

Image	Formed by	Size	Position	Movement
(1)	Cornea	Small	Erect	With
(2)	Lens (anterior capsule)	Small	Erect	With
(3)	Lens (posterior capsule)	Very small	Inverted	Against



Management:

- Bilateral aphakia: Can be corrected with glasses or contact lenses or secondary intraocular lens implantation.
- Unilateral aphakia: Correction with glasses is impossible as it causes aniseikonia (unequal retinal image size) and binocular diplopia. It can only be corrected with contact lenses or IOL implantation.

Disadvantages of spectacle lenses in aphakia:

- (1) Magnification of image size by about 25%.
- (2) Spherical aberration (e.g. Straight lines appear curved).
- (3) Poor coordination of manual movements (e.g. placing a key in a lock).
- (4) Restricted visual field.
- (5) Continual adjustment of aphakic spectacles.
- (6) Cosmetically unaccepted.
- (7) Unsuitable in unilateral cases.

Complicated Cataract

Definition: Opacification of the lens due to ocular or systemic disease.

Causes:

(A) Local:

a- Inflammation of the eye:

1. Severe keratitis.
2. Chronic Iridocyclitis.
3. Chronic chorioretinitis.

b- Degenerative disease of the eye:

1. High myopia.
2. Absolute Glaucoma.

3. Long-standing retinal detachment.
4. Retinitis pigmentosa.

c- Topical toxic medication:

1. Corticosteroids.
2. Pilocarpine.
3. Adrenaline.

The mechanism of cataract in these conditions is interference with lens metabolism. The posterior cortex is affected early, as the posterior capsule is thin and devoid of sub-capsular epithelium.

Examination:

1. Posterior cortical cataract may be rosette shaped in early stages, but later all the lens is affected.
2. Slit lamp examination shows polychromatic luster of the posterior cortex.
3. If the cataract is due to uveitis, posterior synechiae and KPs are seen on the anterior lens capsule and the back of the cornea respectively.
4. The density of cataract is disproportionate to the patient's vision e.g. HM vision with relatively clear lens.

(B) Systemic:

a- Metabolic:

1. Diabetes Mellitus: Two types may occur:
 - i. True diabetic cataract (Snow flake cataract): Occurs in young uncontrolled diabetics. The opacities appear as ill-defined flecks, the lens matures rapidly if hyperglycemia is not controlled.
 - ii. Presenile cataract: Similar to senile cataract but occurs at a younger age in diabetics.
2. Hypoparathyroidism.
3. Hypocalcaemia.

4. Galactosemia: Metabolic defect of galactose mechanism produces cataract in the first month of life and is a preventable type of cataract.

b- Skin diseases:

1. Atopic dermatitis.
2. Ectodermal dysplasia.

c- Toxic medication:

1. Systemic steroids.
2. Naphthalene and Thallium.
3. Ergot.

d- Exposure to radiant:

1. Infrared rays, microwaves and high radiation.
2. X-ray and electric shock.

Table (10): Differential diagnosis of posterior cortical cataract

	Senile cataract	Complicated cataract
Age	Above 50 years	Any age
Opacity		
• Early	Greyish sectors	Grey with polychromatic luster
• Late	Grey-white	Chalky white
Red reflex (RR)		
• Early	Dark sectors in RR.	Dark central area in RR
• Late	Absent RR	Absent RR
Ocular disease	Absent	Present
Prognosis	Usually good	Usually bad (associated ocular disease)

Management:

- ❖ Depends upon the age:
 - Soft cataracts are removed by irrigation aspiration or pars plana lensectomy.
 - Hard cataracts are managed exactly like senile cataract.

N.B: It is very important to examine the eye properly and make sure that the diminution of vision is mainly due to the cataract and nothing else, otherwise, cataract extraction will not be beneficial to the patient.

Traumatic Cataract

Etiology:

1. Blunt trauma (concussion cataract): The opacity is cortical and rosette shaped. It occurs due to rupture of the posterior capsule (the thinnest area of the lens capsule).
2. Perforating trauma leading to injury of the capsule.
3. Intra-ocular foreign body:
 - i. Iron FB causes siderotic cataract.
 - ii. Copper FB causes sunflower cataract.

Management:

1. Meticulous ocular examination:
 - The aim is to detect any other ocular complication 2ry to the trauma in addition to the cataract.
 - Intra-ocular foreign body should be removed if necessary.
 - Any wound should be sutured properly.
 - Ultrasonography if the cataract is dense to detect vitreous hemorrhage or retinal detachment following the trauma.
2. Cataract extraction and IOL implantation:
 - Irrigation aspiration in cases of soft cataract.
 - ECCE in cases of hard cataract.
3. Regular postoperative follow up:

To detect late complications of trauma that may affect the eye.

After Cataract

After cataract is remnant of lens matter in the pupillary area following cataract operation or trauma. It is formed of:

1. Lens fibers left behind during surgery.
2. Proliferation of remaining anterior subcapsular epithelium.

Treatment:

1. If vision is not affected, no interference is necessary.
2. If vision is affected, surgical removal or YAG capsulotomy is necessary.

Subluxation of the Lens

Displacement of the crystalline lens to one side due to tearing of a portion of the suspensory ligament (zonule).

Etiology:

1. Congenital e.g. Marfan's syndrome.
2. Acquired:
 - i. Traumatic.
 - ii. Degenerative e.g. hypermature cataract.
 - iii. Metabolic e.g. homocystinuria.

Symptoms:

- Decreased vision due to myopic astigmatism.
- Uniocular diplopia: If the edge of lens crosses the pupil, two images will be formed, one through the phakic portion of the pupil and the other through the aphakic portion.

Signs:

1. Anterior chamber: Irregular depth.
2. Iris: Tremulous.
3. Edge of the lens may be seen across the pupil.

Complications:

1. Secondary glaucoma.
2. Dislocation of the lens.

Treatment:

1. If no complications: Glasses to correct the error of refraction.
2. If complications occur: Extraction of the subluxated lens and IOL implantation.

Dislocation of the Lens

Displacement of the lens from its place due to total tearing or absence of the zonules.

Etiology:

- As in subluxated lens.

Types:

1. Anterior dislocation in the anterior chamber.
2. Posterior dislocation in the vitreous.

Clinical Picture:

1. Anterior dislocation:

The lens is spherical and resembles a globule of oil in AC.

Complications:

1. Secondary glaucoma: Pupillary block glaucoma or glaucoma inversus that worsens with miotics and is relieved by mydriatics.

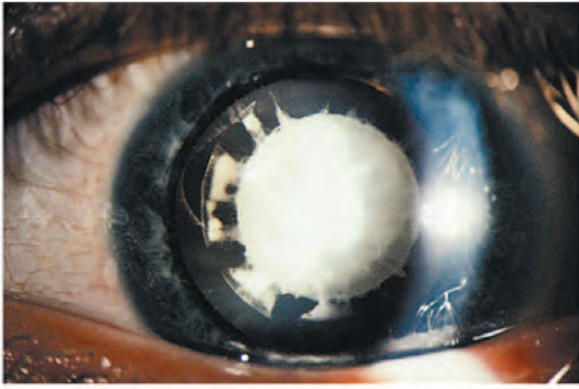
2. Iritis.
3. Corneal decompensation and edema if left for several weeks.

Treatment: Removal through a corneal incision.

2. Posterior Dislocation:

1. Signs of aphakia.
2. Lens may be seen by fundus examination.
3. Usually causes uveitis and secondary glaucoma.

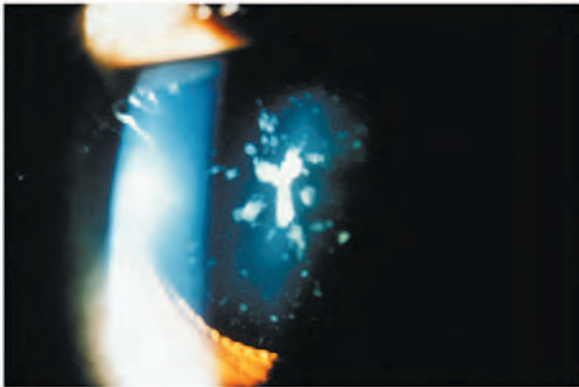
Treatment: Removal by pars plana vitrectomy.



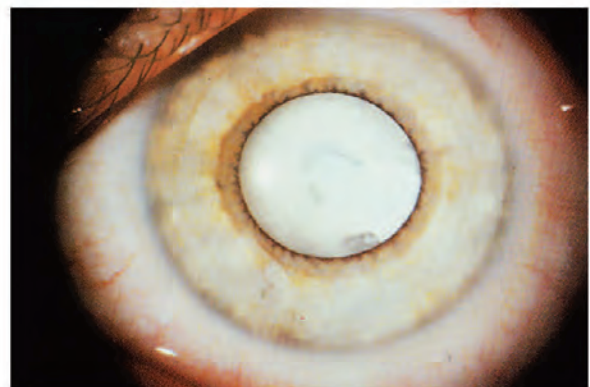Dense lamellar cataract with riders



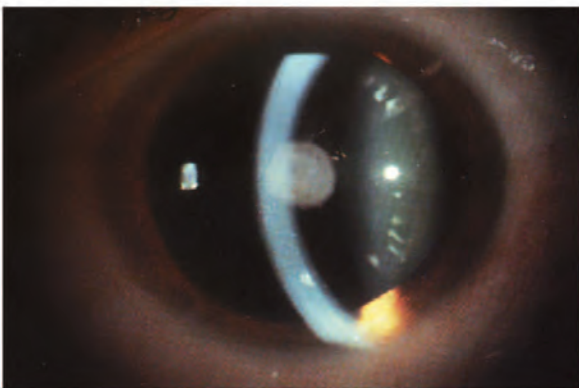
lamellar cataract



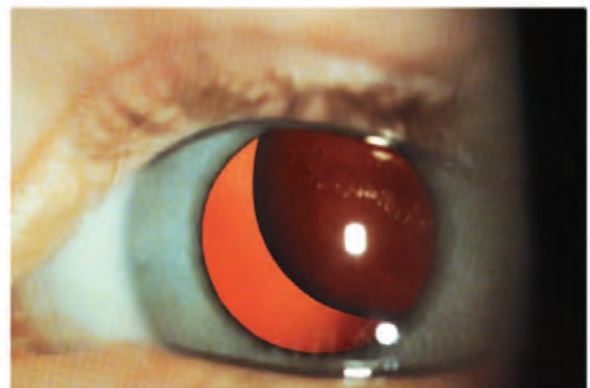
Sutural and blue dot congenital cataract



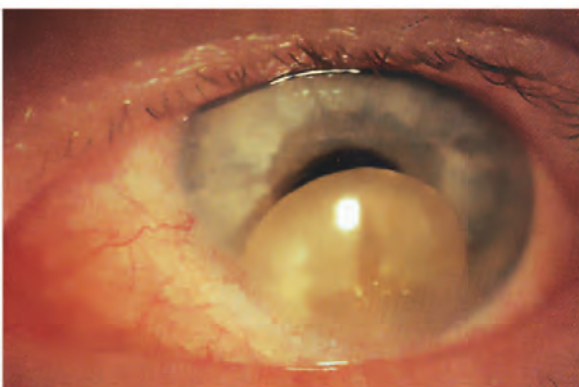Total congenital cataract



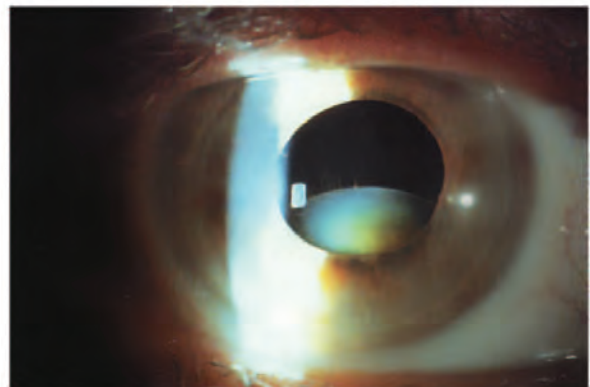
Anterior polar cataract



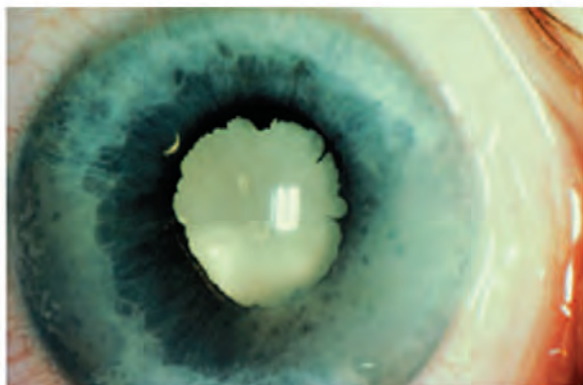
Subluxated lens (Marfan syndrome)



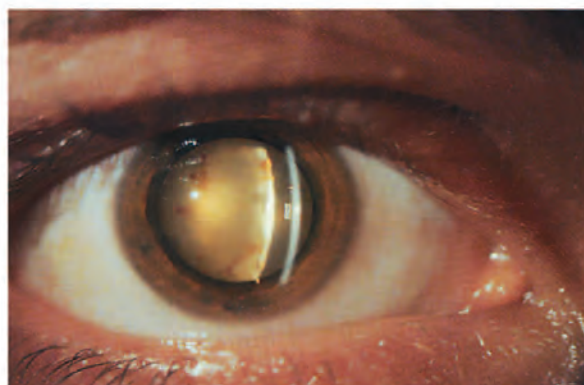
Anterior dislocation of opaque lens



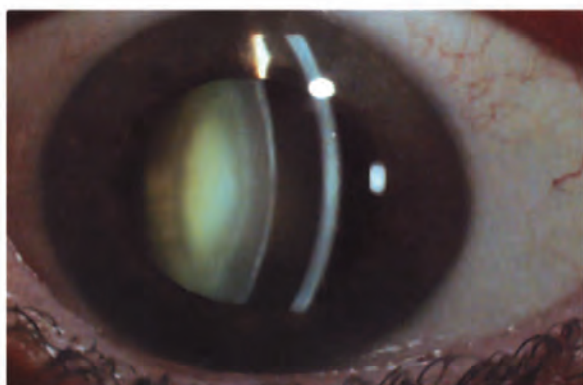
Lens subluxated inferiorly



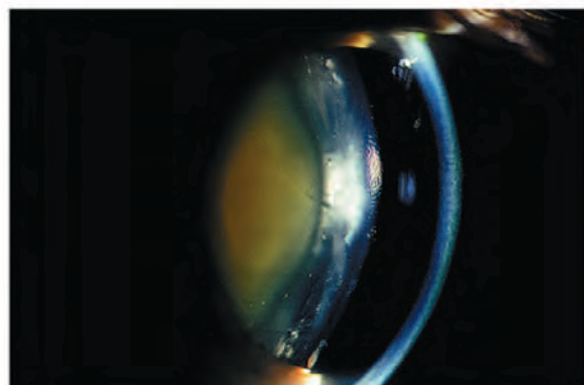
Complicated cataract (chronic anterior uveitis)



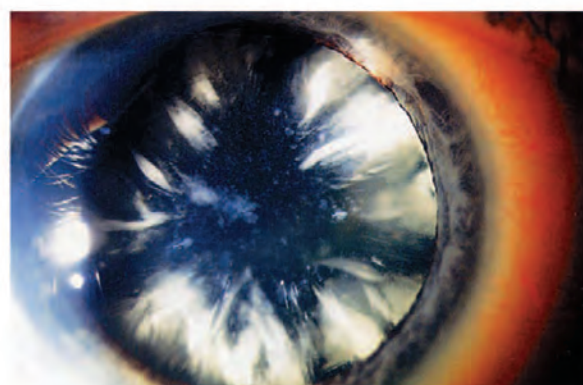
Complicated cataract (siderosis bulbi)



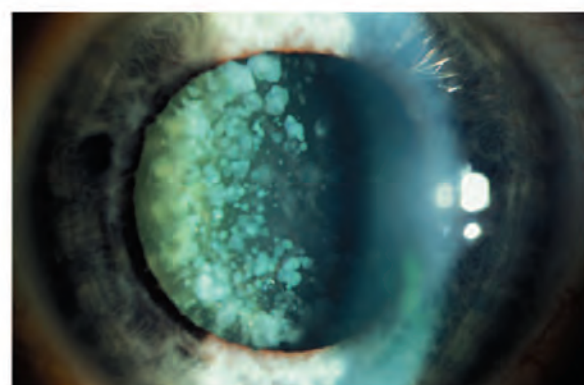
Nuclear cataract



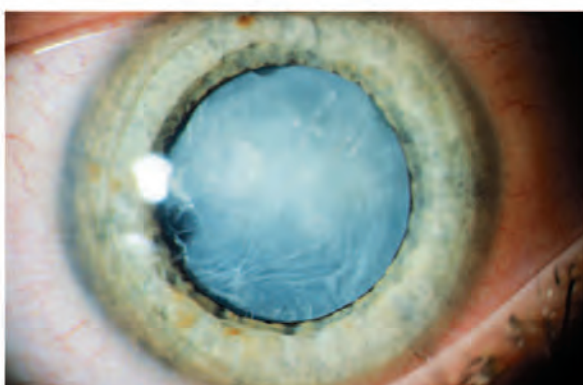
Advanced nuclear cataract



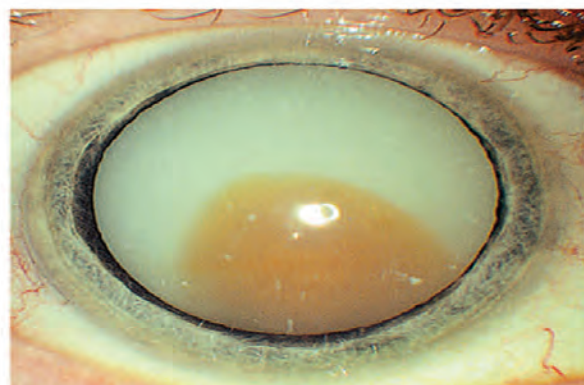
Senile Immature cataract



Dense blue dot cataract



Hypermaturation cataract



Morgagnian cataract (inferior sinking of the nucleus)

Chapter 10

Glaucoma

Glaucoma is a disease in which the pressure inside the eye is sufficiently elevated to result in optic nerve damage and visual field loss. If left untreated, it causes irreversible loss of vision. The normal intraocular pressure varies between 10 to 22 mmHg.

Anatomy of the Anterior Chamber and its angle:

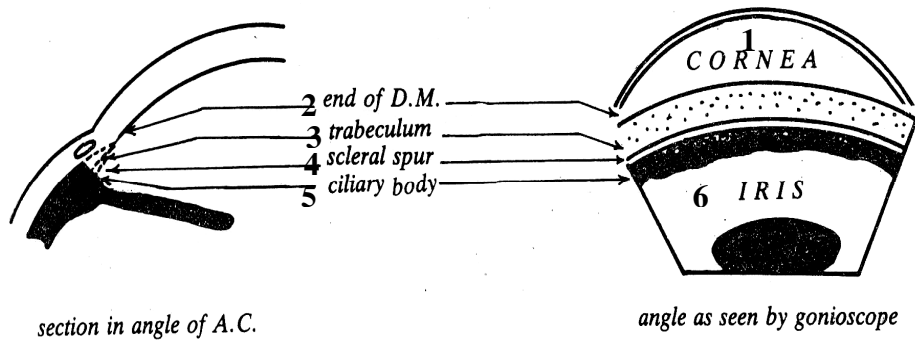
The space bounded anteriorly by the cornea and posteriorly by the iris and part of the base of ciliary body is called anterior chamber. It is filled by a clear watery fluid called aqueous humor. It is deeper in the axial part and get shallower towards the periphery. Average depth is about 2.5-3.0mm.

The angle of the anterior chamber is bounded anteriorly by the cornea. Laterally by the corneo scleral junction, Schlemm's canal, and trabecular meshwork. Posteriorly by the root of the iris and part of the base of the ciliary body. The angle may be narrow in hypermetropes or wide in myopes.

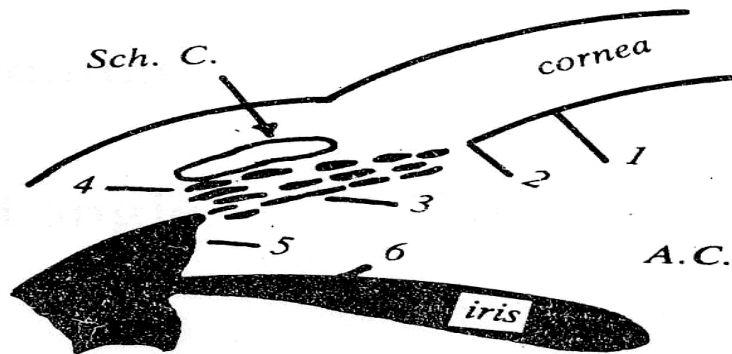
Schlemm's canal is a canal which encircles the eyeball at the limbus. It is connected to the trabecular meshwork by internal canals, to the intrascleral venous plexus and to the anterior ciliary veins on the external surface of the sclera by aqueous veins.

Aqueous secretion and circulation:

The aqueous is secreted by the ciliary processes (secretion and ultrafiltration). Its volume is about 4% of the eye = (0.150-0.300 ml) volume. It circulates from ciliary body → posterior chamber → pupil → anterior chamber → spaces of Fontana → Schlemm's canal → by pinocytosis → aqueous veins → anterior ciliary veins.



The Anterior Chamber Angle



Classification of glaucoma

1. Congenital or developmental.
2. Acquired:
 - Primary:
 - a) Open angle (chronic simple) glaucoma.
 - b) Closed angle (angle closure) glaucoma.
 - Secondary: It may be open or closed angle.

Congenital Glaucoma

Primary Congenital Glaucoma (Buphthalmos)

Definition: Rise of IOP due to developmental anomalies at the drainage angle leading to stretching of the eye coats and enlargement of the globe.

Incidence:

1. 80% within the first 6 months of life.
2. 80% in males.
3. 80% bilateral.
4. 10% autosomal recessive.

Etiology:

1. Abnormal mesodermal membrane at the anterior chamber angle.
2. Failure of separation of the iris from the cornea.
3. Abnormal insertion of ciliary muscles into trabecular meshwork.
4. Absence of Schlemm's canal.

Symptoms:

Early: Photophobia, lacrimation and blepharospasm (nerve ending irritation due to corneal edema).

Late: Large eye (ox eye) and corneal haziness.

Signs:

1. Cornea: Increase in diameter more than 12 mm, hazy & Haab's striae (fine horizontal curvilinear lines due to healed breaks in Descemet's membrane).
2. Sclera: Stretched, thin, the uvea shines through it giving blue appearance.

3. Anterior chamber: Deep due to enlargement of the globe and displacement of the lens posteriorly.
4. Tension: High.
5. Optic nerve: Late, glaucomatous cupping, atrophy.
6. Gonioscopy: Angle anomaly.

Differential diagnosis:

1. Large cornea:
 - a. Megalocornea: No corneal edema or Haab's striae, normal IOP, no optic cupping.
 - b. High myopia.
 - c. Keratoglobus: Bilateral condition with familial incidence later in life with rupture of descemet's membrane resulting in cloudy cornea.
2. Cloudy cornea at birth: Birth trauma, congenital rubella & metabolic disorders.
3. Secondary infantile glaucoma: Retinoblastoma, intraocular inflammation, trauma, aniridia, ectopia lentis, Sturge-Weber syndrome,...etc.

Treatment:

a. If corneal diameter of 13 mm or less:

1. Goniotomy: If the cornea is clear; the principle is to incise the mesodermal membrane along 1/3 circumference of the angle.
2. Trabeculotomy: If the cornea is hazy (anterior chamber angle is not well seen); the principle is to incise Schlemm's canal towards the anterior chamber angle.

b. If corneal diameter more than 13 mm:

External-fistulising operation: e.g. trabeculectomy (alone or with adjuvant Mitomycin-C), the principle is to communicate the anterior chamber with the subtenon and subconjunctival space.

Primary Open-Angle Glaucoma (POAG)

Definition:

A bilateral, genetically determined elevation of intraocular pressure incompatible with the health and function of the optic nerve fibers resulting in progressive field changes and visual loss and associated with a wide angle of the AC as seen on gonioscopy.

Risk factors: (Glaucoma suspect):

1. Strong family history of glaucoma.
2. Age: The disease is much more common above 45 years of age.
3. Dark race: Glaucoma is more common and more difficult to treat.
4. Myopia: The 2 diseases may be genetically linked.
5. Vasospastic disorders as migraine and Raynaud's phenomenon.
6. Ocular hypertension.

Symptoms:

Many cases are asymptomatic and accidentally discovered. That is why routine checking of IOP (particularly after the age of 40) is the only way to discover the disease before it "steals" vision.

Some patients may complain of defective dark adaptation described by the patient as night blindness.

Signs:

There are three cardinal signs in open angle glaucoma:

1. Elevated intraocular pressure.
2. Cupping of the optic disc.
3. Field changes.

1. Elevation of intraocular pressure (IOP):

The intraocular pressure is usually elevated except in cases of normal tension glaucoma. Any rise of IOP above 22 mmHg is suspicious but not diagnostic until it exceeds 26 mmHg.

2. Cupping of the optic disc:

The most important structure to be examined in glaucoma is the optic nerve head.

The optic nerve head (optic disc) is the channel through which the nerve fibers leave the globe to the brain. It normally appears as a pale pink slightly oval disc with a whitish central area known as the physiologic cup. The normal horizontal cup-disc (C/D) ratio is usually 0.3 and the cup is usually circular and has sloping walls.

Early changes of the optic disc in glaucoma:

1. Large cup disc ratio (0.4-0.7).
2. Asymmetry of C/D ratio between the 2 eyes.
3. Vertical elongation of the optic cup.
4. Notching of the rim of the cup at the upper and lower pole.
5. Splinter hemorrhage on the disc.
6. Increased visibility of the pores of the lamina cribrosa.
7. Retinal nerve fiber layer defects are seen with green filter.

Late changes of the optic disc in glaucoma:

1. Large cup with C/D ratio more than 0.7.
2. Deep cup with undermined edges (billiard table).
3. Nasal shift of the vessels.

3. Field changes:

Since the visual field suffers much earlier than visual acuity in glaucoma, patients should be followed up with visual field examinations every 6-12 months to detect any signs of progression of the disease.

Visual field changes in glaucoma: These are determined by the nature of distribution of the ganglion cell axons as they converge towards the optic nerve to leave the eye.

- **The most crowded fibers** at the optic nerve are the temporal fibers above and below the macula (the arcuate fibers) and this explains why the earliest glaucomatous field defects occur in this zone.
- **The least crowded** are the macular fibers and this explains the relative sparing of visual acuity until the late stages of the disease.
- No fibers from the upper half of the retina enter through the lower half of the disc and vice versa and this explains why glaucomatous field defects respect the horizontal meridian.

Paracentral scotoma is the earliest clinically significant defect is an isolated scotoma that appears in the area between 10-20° of fixation (enlargement of the blind spot). As the disease progresses, the scotoma elongates circumferentially along the distribution of the arcuate nerve fibers to connect with the blind spot forming an upper or lower arcuate scotoma (Bjerrum's scotoma).

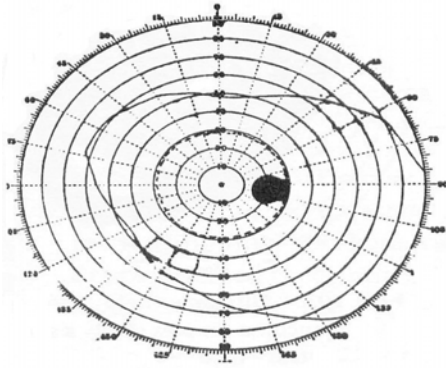
When both upper and lower arcuate scotomas are present, they form a double arcuate or central ring scotoma (10-20 degrees from fixation point whereas in retinitis pigmentosa the ring scotoma is 50 degrees from fixation point).

Nasal step (Roenné step) which results from asymmetrical shape of the upper and lower field defects as they meet at the horizontal meridian. It is quite characteristic of glaucoma. A similar defect can occur at the temporal field and is called temporal wedge but is less common.

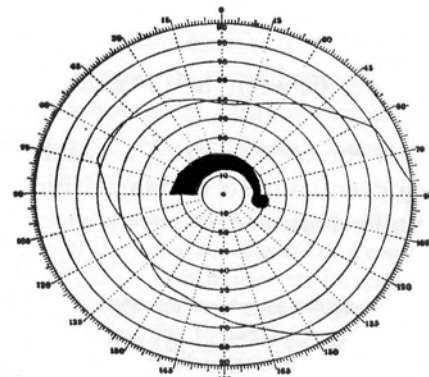
In advanced cases, peripheral concentric contraction of the field occurs and fuses with the central defects (breakthrough) until only a small island of central vision is preserved (tubular field) and an accompanying temporal area of the field called temporal island. With progression of glaucoma, the tubular field is lost and the last remaining area is the temporal island.

Patterns of visual field changes:

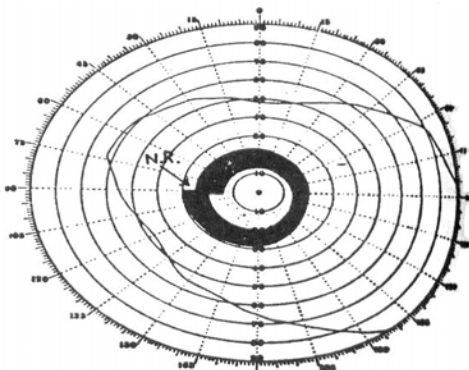
1. Paracentral scotoma
2. Bjerrum's scotoma
3. Double arcuate scotoma with Nasal step of Roenné
4. Peripheral concentric contraction
5. Tubular field



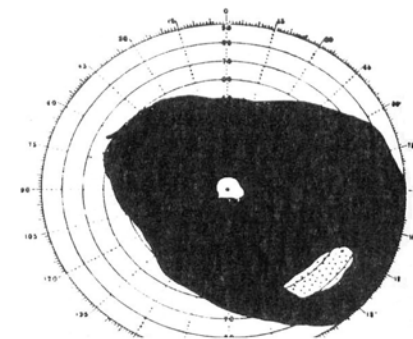
(1)



(2)



(3)



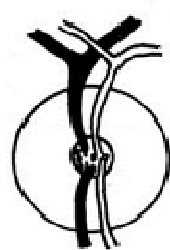
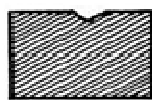(4)

Field changes: (1) *Paracentral scotoma*

(2) *Bjerrum scotoma*

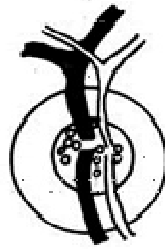
(3) *Double arcuate scotoma*

(4) *Tubular field with temporal island*




Physiological cup

Diameter *small*
Depth *v. shallow*
Edge *sloping*



*Atrophic cup
(primary optic atrophy)*

diameter *intermediate*
depth *intermediate*
edge *sloping*



Glaucomatous cup

diameter *very large*
depth *very deep*
edge *undermined*

Cupping of the Optic Disc.

Optical coherence tomography (OCT):

As the early sign of glaucomatous damage appears in the nerve fiber layer (NFL), detection of early loss in this layer can help in early diagnosis and follow up of glaucoma before the development of pathological cupping or detectable field changes. OCT is a, sophisticated computer dependent machine that uses plane-polarized light to measure the thickness of the nerve fiber layer around the optic nerve head.

Management of POAG:

Treatment of POAG is mainly medical except in cases of:

1. Progressive nerve fiber layer (NFL) damage; progressive optic disc cupping and / or progressive field defects with maximum tolerated medical treatment.
2. Non-compliance of the patient to medical treatment.
3. Intolerability to medical treatment or significant side effects.

If medical treatment fails, the alternatives are laser treatment or surgery.

A) Medical treatment:

I. Topical (Eye drops):

1. Beta-blockers:

This group of medications blocks the sympathetic beta-receptor, which plays an important role in aqueous secretion, thus decreasing aqueous formation e.g. Timolol maleate (non-selective beta blocker) and Betaxolol (selective beta blocker).

Side-effects:

- Systemic side effects can be quite dangerous as worsening of bronchial asthma, heart disease and myasthenia gravis.

2. Adrenergic agonists:

e.g. Epinephrine and Brimonidine → increase aqueous outflow.

3. Miotics:

Miotics especially Pilocarpine nitrate 1-4% leading to contraction of ciliary muscle → pull on the trabecular meshwork → ↑aqueous outflow.

Side effects of miotics:

- Ocular:
 1. Constriction of the field of vision.
 2. Worsening of vision in patients with nuclear cataract.
 3. Spasm of accommodation.
 4. Cataract.
 5. Excessive use may cause pupillary block glaucoma.

- Systemic:
 1. Bradycardia,
 2. Gastro-intestinal colics.
 3. Headache.

4. Prostaglandin analogues:

1. Latanoprost (Xalatan).
2. Bimatoprost (Lumigan).
3. Travoprost (Travatan).
4. Unoprostone (Rescula).

They reduce the IOP by increasing the uveo-scleral outflow.

5. Carbonic anhydrase inhibitors:

Topical CAIs as Dorzolamide (Trusopt) has fewer systemic side effects but may cause allergic conjunctivitis and is less potent than systemic CAIs.

II. Systemic:

Systemic carbonic anhydrase inhibitors:

These are very effective medications but have a lot of systemic side effects on the GIT, urinary and nervous systems. That is why they are used only for a short term as in 2ry glaucoma and post-operative cases. The most common drugs are Acetazolamide (Diamox, Cidamex) 250mg/6hrs and Dichlorpheniramide (Oratrol) 50mg/8hrs.

B) Laser trabeculoplasty (LT):

It is the technique of applying low power laser burns (Argon or Double Frequency YAG) to the trabecular meshwork aiming at shrinkage of the trabecular ring and contraction leading to widening of the inter-trabecular spaces, which will help to drain aqueous.

C) Surgery:

1. The standard technique is sub-scleral trabeculectomy (SST), which is done under a scleral flap to minimize the effects of excessive filtration, which could result in severe hypotony; it is done if all the previous lines fail to control the glaucoma. Failure of control is commonly due to non-compliance and negligence. Surgery reduces the IOP by creating a channel for the exit of aqueous humor from the AC into the subconjunctival space.
2. Resistant cases may need a glaucoma device which is a large reservoir implanted between two rectus muscles and connected to the AC with a silicon tube (Glaucoma valve).
3. Ciliary body ablation procedures; the principle is to destroy the ciliary epithelium leading to decrease in aqueous secretion.

It's indicated in difficult cases unresponsive to other measures.

Methods include:

- a. Cyclodiathermy.
- b. Cyclocryotherapy.
- c. Cyclophotocoagulation either trans-scleral or transpupillary.

Ocular Hypertension

Ocular hypertension is an elevated intraocular pressure without evidence of anatomic or functional damage to the eye. The optic disc cup is normal in size and the field of vision of the patient is normal. Frequent measuring of IOP as well as testing the field of vision is necessary to detect any changes early.

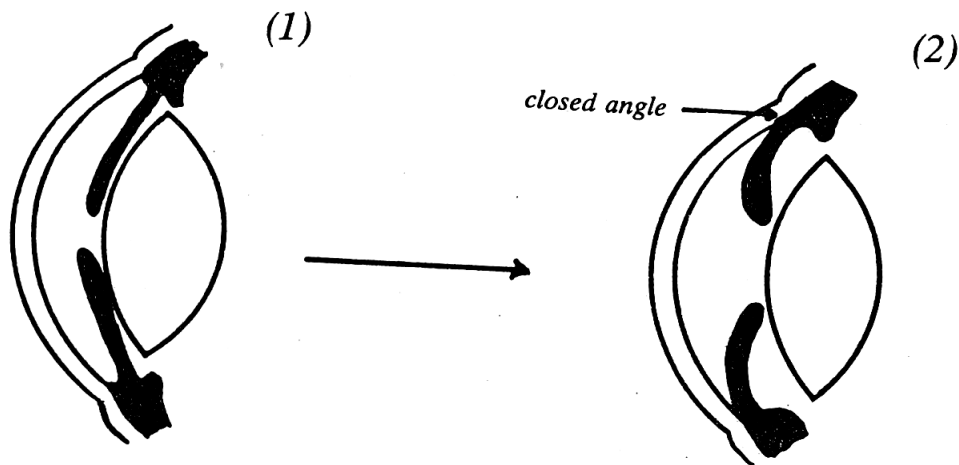
Normal Tension Glaucoma

In normal tension glaucoma, the intraocular pressure is not high, but the optic disc cup and field of vision are affected. In those patients, the IOP should be kept below 12 mm Hg.

Primary Closed-Angle Glaucomas

In this disease, the cause is the strong contact between the iris and the crystalline lens in small anterior segment of the eye with a shallow AC and crowded structures.

The attack comes on suddenly when any additional factor increases the already present contact between the iris and the lens as pupillary dilatation from emotional excitement, dilating drops or staying in the dark.



Iris Bomb's Mechanism in Closed Angle Glaucoma

Clinical stages:

1. Intermittent (Prodromal) stage:

- **Symptoms:** Transient attacks of ocular pain, headache blurring of vision and colored haloes.
- **Signs:** The eye may look normal in between the attacks.

During the attack there may be elevated IOP, dilated pupil & mild epithelial corneal edema with shallow AC. Gonioscopy reveals narrow angle.

The attack may be broken after 1-2 hours by physiological miosis (exposure to sunlight or sleep).

- **Provocative tests:** (a rise of IOP by 8 mmHg or more is diagnostic).
 - a. **Mydriatic test:** IOP is measured before & after pupillary dilatation by weak mydriatic e.g. Phenylephrine 5% drops.
 - b. **Dark room test:** IOP is measured before & after patient stay in dark room (awake) for one hour.

- **Treatment:**

Prophylactic Pilocarpine drops, peripheral iridectomy or laser iridotomy.

2. Acute stage: (Acute congestive or acute angle closure glaucoma).

- **Symptoms:**

1. Acute pain due to stretching of ocular coats.
2. Severe headache referred along the trigeminal nerve.
3. Rapid drop of vision due to corneal edema.
4. Nausea and vomiting that may simulate acute abdomen due to reflex vagal stimulation.

- **Signs:**

1. Acute red eye due to ciliary congestion with lacrimation and severe photophobia.
2. Eyelid edema.
3. Marked visual impairment (down to PL in some cases).
4. Corneal edema and haze.
5. Very shallow AC.
6. Semi-dilated irreactive vertically oval pupil.
7. Marked increase in the IOP up to 70 mmHg (stony hard).
8. The fundus is hardly seen due to corneal edema.

- **Fate of the attack:**

1. Recovery: Either with treatment or very rarely spontaneous (due to miosis when patient sleeps or relieve of pupillary block due to iris atrophy).
2. Chronic stage: When resolve leaving PAS.
3. Absolute: Complete loss of vision in severe attack.

▪ **Management:**

Management of an acute attack is essentially surgical.

- Medications are given in the pre-operative period with the following goals:

1. Lowering the very high IOP prior to surgery.
2. Relieving the patient's suffering.

1) Hospitalization.

2) Hyperosmotic agents:

- a. These elevate the plasma osmotic pressure with the aim of withdrawing fluids from the eye into the plasma.
- b. The most commonly used is Mannitol 20-25% solution intravenous, 1-2 mg/Kg body weight, 60 drops / minute. Mannitol should be used cautiously in elderly and cardiac hypertensive patients.

3) Topical miotics:

- Pilocarpine 2-4% every 30 minutes until the pupil constricts.

4) Carbonic anhydrase inhibitors:

- Oral or IV carbonic anhydrase inhibitors are indicated to lower the IOP before surgery.

5) Analgesics and anti-emetics.

6) Gonioscopy: To visualize the angle of the anterior chamber.

- If the acute attack is recent (within 24 hours) and gonioscopy shows no evidence of peripheral anterior synechia, iridectomy is indicated.
- If the attack has lasted longer and gonioscopy shows evidence of peripheral anterior synechia, an external fistulizing operation is performed as in primary open angle glaucoma.

Prophylaxis of the other eye:

Pilocarpine should be used in the other eye to avoid an acute attack. A prophylactic peripheral laser iridotomy may be performed to avoid angle closure.

▪ **Differential diagnosis:**

1. Other causes of red eye:
 - a. Acute conjunctivitis.
 - b. Corneal ulcer.
 - c. Acute iridocyclitis.
2. Other causes of rapid rise of IOP:
 - a. Glaucomatocyclitic crisis.
 - b. Lens induced: Phacomorphic & phacolytic glaucoma.

Table (11): Differential diagnosis of acute red painful eye

	Conjunctivitis	Corneal ulcer	Iridocyclitis	Acute Glaucoma
Pain	Discomfort	Dull-aching	Dull-aching	Bursting
Defective V.A.	No	Yes	Yes	Yes
Ocular association	Discharge	Photophobia, Lacrimation	Photophobia	Severe photophobia
General association	No	No	Arthritis, psoriasis	Nausea, vomiting
Conjunctiva	Congestion, Discharge	Ciliary injection	Ciliary injection	Ciliary injection
Cornea	Clear	+ve fluorescein dye test	Hazy cornea, Keratic precipitate	Corneal edema ± fine Keratic precipitate
Anterior chamber	Normal	Normal or aqueous flare with secondary iritis	Aqueous flare Plasmoid aqueous Hypopyon	Shallow anterior chamber, Fine flare with secondary iritis
Iris	Normal	Normal	Muddy+ synechia	May be muddy
Pupil	Normal	Normal	Normal, miosis or festooned	Oval longitudinal axis vertical, semi- dilated, greenish
Lens	Clear	± Complicated cataract	± Complicated cataract	± Complicated cataract
IOP	Normal	Normal or ↑	Normal, ↑ or ↓	Very high (stonny)
Treatment	Hot foment, Antibiotic drops and ointment	Bandage Atropine Antibiotic or antiviral drops and ointment	Dark glasses, Atropine, Steroid drops and ointment	Hospitalization, Sedation & analgesia. Essentially surgical, Medical to ↓ IOP before surgery

3. Chronic stage:

If the acute attack is not properly managed, the condition turns to chronic stage with formation of PAS. This stage is characterized by:

- IOP is moderately elevated.
- Less ciliary congestion.
- Chronic corneal edema which may lead to bullous and filamentary keratopathy.
- Very shallow AC.
- Semidilated very sluggish pupil.
- Visual field defects.

- **Treatment:** External filtering operation (subcleral trabeculectomy).

4. Absolute stage:

It is the end stage of uncontrolled glaucoma with high IOP.

- **Symptoms:** Blind (no PL), painful eye.

- **Signs:**

1. Cornea: Insensitive and edematous.
2. Iris: Atrophic patches.
3. AC: Shallow.
4. Pupil: Dilated, fixed and greenish-blue.
5. Tension: Stony hard.
6. Fundus: Optic atrophy.

- **Sequelae:**

1. Degenerative pannus (granulation tissue invade cornea at level of BM).
2. Sclera: Staphyloma (intercalary, ciliary & equatorial).
3. Lens: Complicated cataract.
4. Atrophia bulbi: Due to ciliary body atrophy may occurs later.

- **Treatment:** (for blind painful eye).

Ciliary body ablation e.g. cyclo-photocoagulation or enucleation.

Table (12): Difference between open and closed angle glaucoma

	Open angle Glaucoma	Closed angle Glaucoma
Incidence	Common	Less common
Cause	Trabecular sclerosis	Closure of angle
Angle	Open	Closed
Age	Above 50 years	Above 40 years
Sex	Equal	Females more
Individual	Any person	Nervous people
Refraction	Any	Hyperopia with narrow angle
Symptoms	Very few	Marked
Prodroma	Absent	Present
Cupping & field changes	Occur early	Late, in chronic stage
Treatment	Medical	Surgical

Secondary Glaucomas

In secondary glaucoma, the rise of IOP is secondary to a local eye disease. It may be of the open or the closed angle type.

I. Secondary Open Angle Glaucoma

Common features:

1. The angle is wide open on gonioscopy.
2. The AC is of normal depth.
3. The cause of glaucoma can be identified by examination.

Classification:

1. Lens – induced glaucoma:

a) Phacolytic glaucoma:

It occurs in hypermature cataract where the lens proteins break down into small fragments that leak through the capsule into the AC where they are engulfed by the macrophages. The escaping macrophages are trapped in the trabecular pores.

Treatment: Lens extraction.

b) Phaco-anaphylactic glaucoma:

It follows trauma or surgery, where the lens proteins are released into the ocular fluid and initiate an autoimmune reaction, the products of which are deposited on the trabecular pores causing their narrowing and inflammation.

2. Glaucoma Secondary to Intraocular Inflammation:

a) Uveitis:

The cause of glaucoma is the plasmoid aqueous as well as swelling of the trabecular pores.

Treatment:

- 1- The uveitis is managed as usual (Atropine & steroids).
- 2- Beta blockers.
- 3- Local and systemic carbonic anhydrase inhibitors.

b) Glaucomato-cyclitic crisis:

Attacks of unilateral rise of the IOP with a normally open angle. Headache and blurring of vision are common due to corneal edema. The cause is mostly related to disturbance of prostaglandin metabolism in the eye.

c) Herpes Simplex and zoster:

The cause of glaucoma is inflammation of the trabecular cells.

N.B: Intraocular inflammation may be complicated by secondary angle-closure glaucoma due to the occurrence of peripheral anterior synechiae.

3. Traumatic Glaucoma:

Open-angle glaucoma following trauma may be due to:

1. Traumatic iridocyclitis: See inflammatory glaucoma.
2. Hyphema: The blood in the anterior chamber may obstruct the pores of the trabecular meshwork and decrease the aqueous outflow from the eye.
3. Ghost cell glaucoma:

It occurs in longstanding cases of vitreous hemorrhage where the red blood cells breakdown and their rigid walls (ghost cells) diffuse into the aqueous and obstruct the trabecular pores.

4. Angle recession glaucoma:

Glaucoma following trauma secondary to tear of the ciliary body and recession of the angle structures backwards that may obstruct the aqueous outflow channels.

5. Glaucoma Secondary To Intraocular Tumors:

In choroidal melanoma and retinoblastoma the IOP may rise due to:

1. The associated intra ocular inflammation.
2. Obstruction of the episcleral veins by the growing tumor.
3. Obstruction of the trabecular pores by the malignant cells.

6. Corticosteroid Induced Glaucoma:

Secondary open-angle glaucoma may follow the prolonged use of corticosteroids.

Treatment:

Stopping the steroid therapy, but if steroids are absolutely necessary, topical beta blockers should be prescribed to lower the IOP.

II. Secondary Angle Closure Glaucoma

In these cases, the IOP rise is secondary to pupillary block or chronic inflammation with subsequent formation of peripheral anterior synechiae.

Common features:

1. Gonioscopy shows closure of the angle.
2. The AC is shallow.
3. The cause of glaucoma can be identified by examination.

Classification:

1. Lens - induced Glaucomas:

a. Anterior lens dislocation:

It leads to pupillary block.

Treatment: Lens extraction.

b. Intumescent cataract:

The intumescent lens increases in size markedly due to its high fluid content. It may encroach upon the anterior chamber, produce a pupillary block, or cause angle occlusion, resulting in angle-closure glaucoma.

Treatment: Cataract extraction after control of the IOP by hyperosmotic agents.

2. Causes in the Iris:

a. Chronic iridocyclitis: The cause of glaucoma is ring synechiae or total posterior synechiae.

Treatment: Filtration surgery (sub-scleral trabeculectomy).

b. Iris tumors or cysts.

c. Pushing the iris forwards by a rapidly growing posterior segment mass or intra ocular hemorrhage.

3. Traumatic Glaucoma:

Secondary angle closure glaucoma following trauma may be due to

a) Traumatic iridocyclitis:

Leading to ring synechiae and occlusio- pupillae.

b) Anterior lens dislocation:

Dislocation of the lens into the anterior chamber.

4. Neovascular Glaucoma:

Neovascular glaucoma is due to abnormal blood vessels growing from the iris surface to the angle of the anterior chamber, obstructing the trabecular meshwork and impairing aqueous outflow.

The most common causes are DM and central retinal vein occlusion.

It passes into three stages:

- 1. Stage of rubeosis iridis:** The abnormal vessels are limited to the surface of the iris.
- 2. Stage of open angle glaucoma:** The abnormal vessels encroach on the angle, with subsequent leakage of proteins that lead to iridocyclitis and subsequent open angle glaucoma.
- 3. Stage of angle closure glaucoma:** The end stage where anterior synechiae closes the angle.

Treatment:

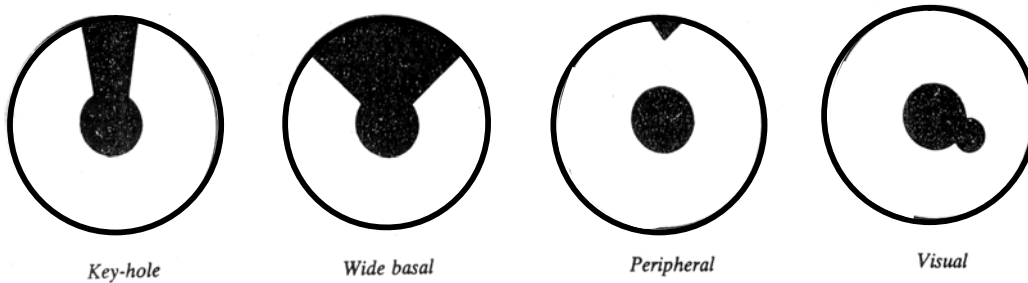
- 1-If discovered early:** Pan retinal photocoagulation using argon or diode laser to control the rise of pressure and cause regression of rubeosis.
- 2-In neglected cases:** Cyclodestructive procedures to diminish aqueous formation are indicated. This may be done using trans-scleral diode cyclodestruction.

Iridectomy

Iridectomy means removal of a portion of the iris.

Types of Iridectomy:

- (1) **Key-hole iridectomy (Complete or sector iridectomy)** means excision of a part of the iris from the pupil to the ciliary border in one snip.
- (2) **Wide basal iridectomy (Basal iridectomy or broad basal)**. Here a wide portion of the iris is excised in two snips and in between, the iris is torn from its root.
- (3) **Peripheral iridectomy (Incomplete or button hole)**. Here a portion of the iris near its root is removed. The pupil remains round.
- (4) **Visual iridectomy (Optical iridectomy)**. Here a small portion of the iris is removed near the pupillary and not reaching the ciliary border. Its site of choice is down and in to assist in convergence. It must be as small as possible to minimize dazzling.



Types of Iridectomy

Indications of Iridectomy:

(1) Key-hole iridectomy is usually performed as a part of other operations:

- Cataract extraction.
- Glaucoma operations.

(2) Wide basal iridectomy is the classic treatment for acute congestive glaucoma which cannot be controlled medically in 24 hours.

(3) Peripheral iridectomy:

1. As a part of other operations:

- a- Cataract extraction.
- b- Sub-Scleral Trabeculectomy (SST).

2. In the treatment of angle closure glaucoma:

- a- In prodromal stage.
- b- Cases controlled medically before peripheral anterior synechiae occur.
- c- Prophylactic against acute attack in the other eye.

(4) Visual iridectomy is indicated in central localized opacities of the cornea and lens provided the visual acuity improves after dilatation (mydriatic test).

(5) Miscellaneous indications for iridectomy:

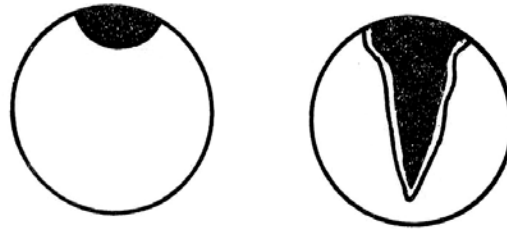
- 1. Post-traumatic or post-operative prolapse of iris.
- 2. Foreign body on iris.
- 3. Tumor of iris not reaching ciliary border.

Iridotomy

Iridotomy means to make a cut in the iris without removing any part of its tissue.

Indications:

- 1) For drawn up pupil (radial iridotomy).
- 2) Instead of iridectomy in cataract extraction.
- 3) Laser peripheral iridotomy (Argon or YAG).



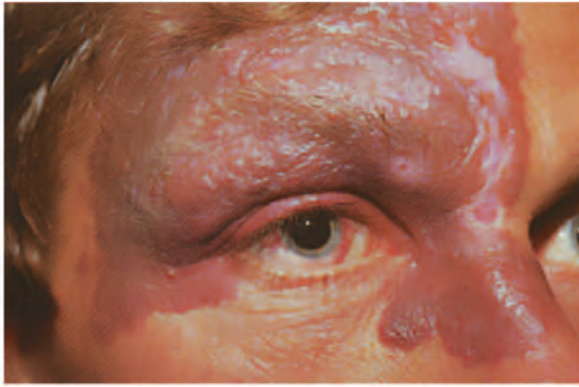Iridotomy for drawn up pupil

Laser Iridotomy

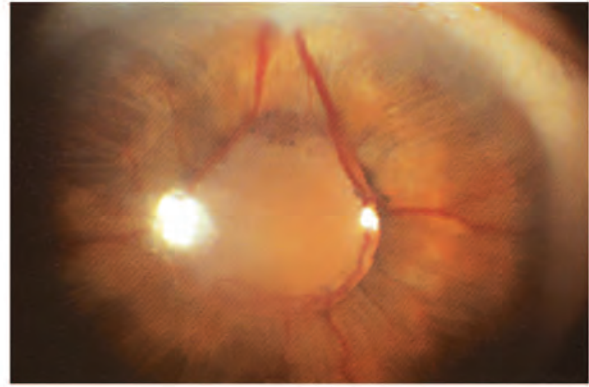
Laser energy can be used to make a hole in the iris. It can be done by Argon laser (laser photocoagulation) or YAG laser (Surgical laser).

Indications:

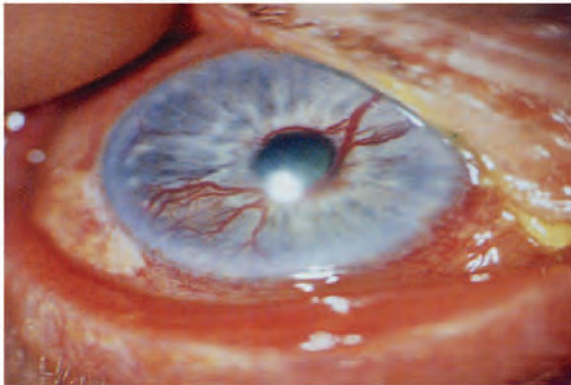
- 1) Closed angle glaucoma.
- 2) Pupillary block glaucoma.
- 3) Drawn-up pupil.



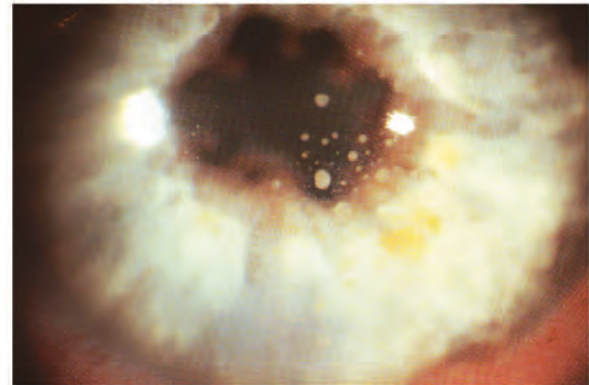
Facial haemangioma in sturge-Weber syndrome



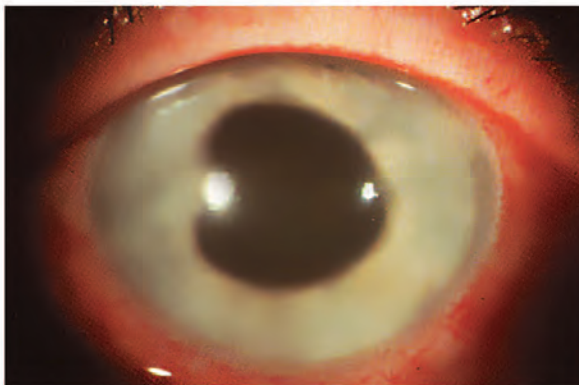
Neovascular glaucoma due to rubeosis iridis



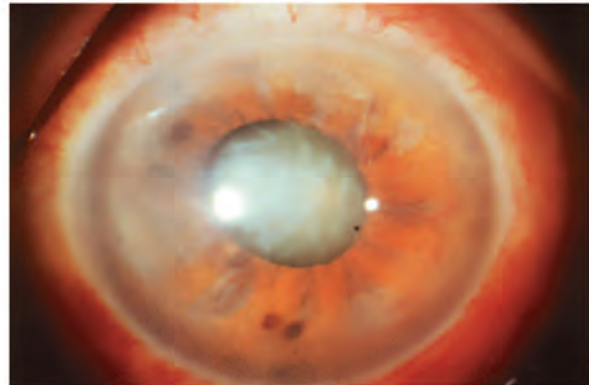Rubeosis iridis



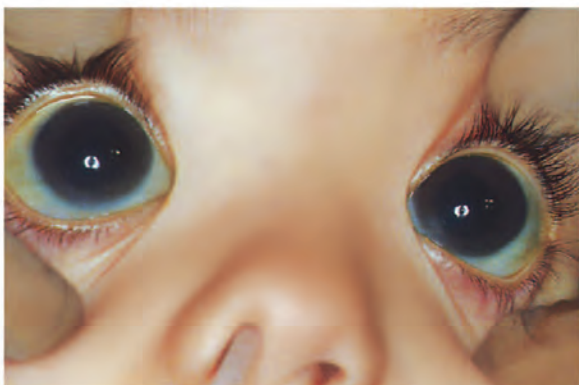Glaucoma secondary to chronic iritis



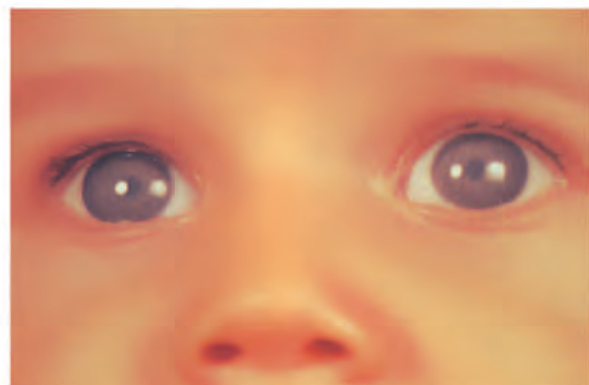Acute congestive glaucoma



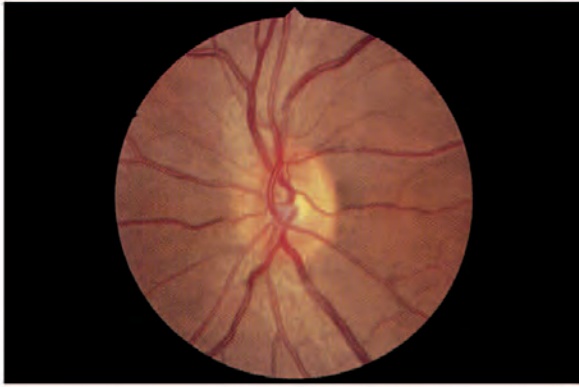Corneal oedema in acute congestive glaucoma



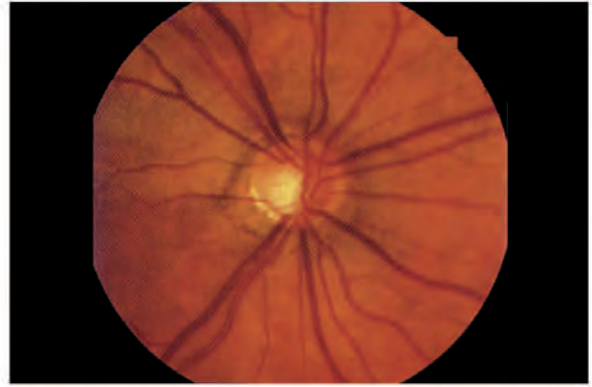
Bilateral congenital glaucoma



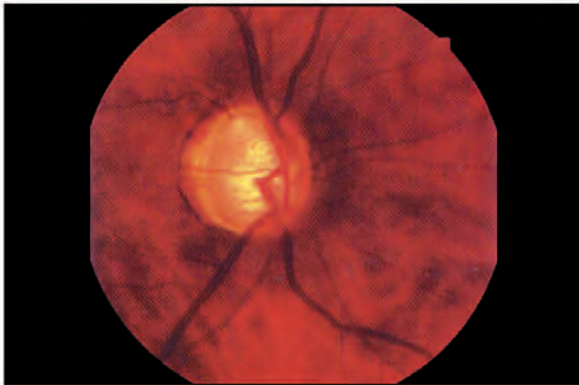Bilateral congenital glaucoma (corneal clouding)



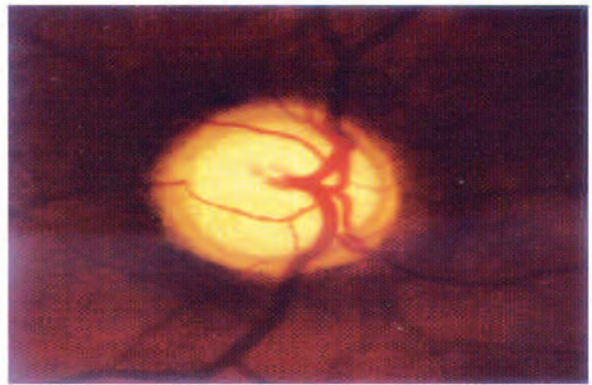
Normal non- glaucomatous optic disc



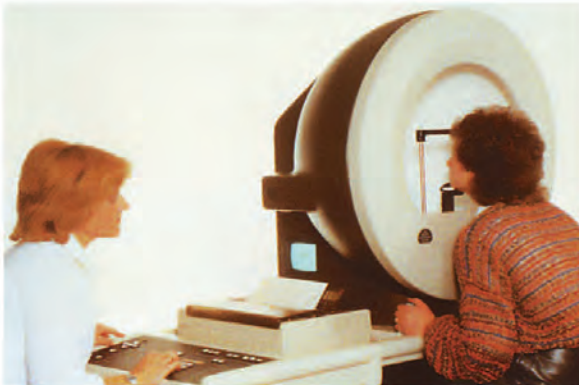Early glaucomatous cupping



Moderate Cupping



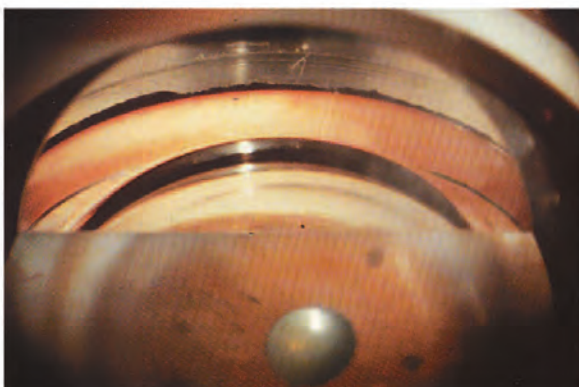
Advanced glaucomatous cupping



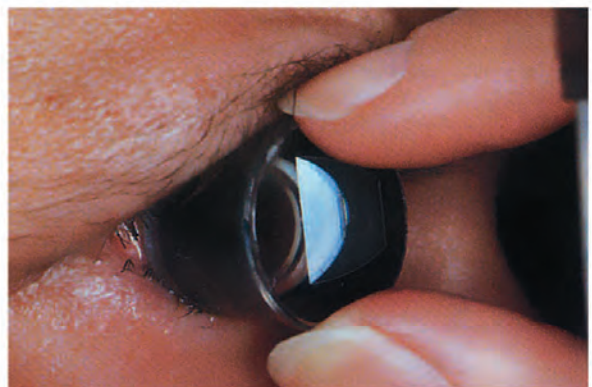
Automated perimetry



Hand-held Perkins tonometer



Gonioscopic appearance of a wide open angle



Gonioscopy with the Goldmann lens

Chapter 11

Retina

Anatomy:

The retina is the neuro-sensory layer of the eye that receives light and translates photon energy into electrical impulses that reach the visual cortex in the brain and are transformed into a visual sensation.

It is the innermost layer of the eye and is composed of two parts:

1. The retinal pigment epithelium (RPE): A single layer of hexagonal cells continuous with the pigment epithelium of the ciliary body at the ora serrata.

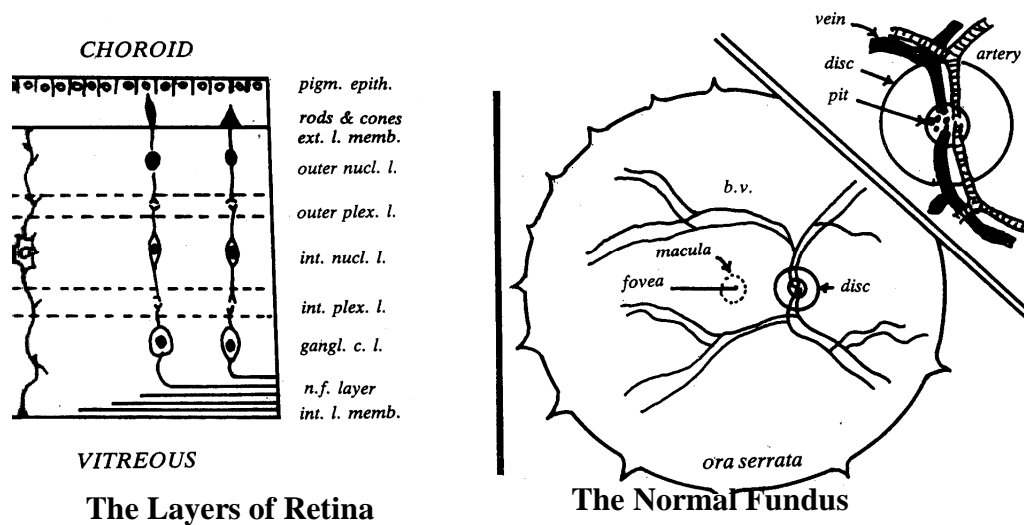
2. Sensory retina: The sensory retina is a thin transparent tissue, varying in thickness from 0.4 mm near the optic disc to 0.15 mm anteriorly at the ora serrata.

Separation of the two layers causes retinal detachment.

Retina is divided into:

1. Central retina (the macula lutea 6-7.5 mm in diameter). The center of the macula is the fovea centralis 1.5mm in diameter which contains only cone receptors. Functions of the macula include central vision, color vision and form sense.

2. Peripheral retina that ends at the ora serrata. The retinal periphery contains mainly rods and is responsible for peripheral vision and night vision.



Histology:

The retina consists of 10 layers, which are, from outside in:

1. RPE: It consists of hexagonal cells containing melanin pigment. It is in contact with Bruch's membrane of the choroid.
2. Photoreceptor cells (rods and cones): The rods are responsible for night vision (scotopic vision) and are located at the periphery of the retina. Cones are responsible for day vision (photopic) and are located at the fovea.
3. External limiting membrane: It is formed by the ends of Muller's fibers.
4. Outer nuclear layer: It is formed by the nuclei of the rods and cones.
5. Outer plexiform layer: It is formed by the synapses between the nuclei of the rods and cones and the bipolar cells.
6. Inner nuclear layer: Containing the bipolar cells and the cells of Muller's fibers.
7. Inner plexiform layer: It is made by the synapses between the bipolar cells and the ganglion cells.
8. Ganglion cell layer: One layer of ganglion cells.

9. Nerve fiber layer: It is formed by the axons of the ganglion cells; these fibers form the optic nerve. The central retinal vessels are located in this layer.
10. Internal limiting membrane: It is formed by the footplates of Muller's fibers.

Blood supply of the retina:

1. The retina is supplied by the central retinal artery (CRA), a branch of the ophthalmic artery, which is a branch of the internal carotid artery. Its branches are end arteries and supply only the inner half of the retina.

The CRA pierces the subarachnoid space accompanied by the vein to reach the center of the optic nerve. It turns forwards at a right angle and passes through the lamina cribrosa to enter the eye through the physiologic cup.

The half layers of the retina and the fovea are avascular and receive nutrition by diffusion from the choriocapillaris.

2. The retina is drained by the central retinal vein (CRV), which ends in the cavernous sinus.

Fundus of the Eye

Fundus examination is an essential part in the evaluation of any patient.

The following structures can be seen:

1. The retina.
2. The optic disc is the visible part of the optic nerve.
3. The choroid.
4. The vitreous.

Examination of the fundus:

A. Indirect ophthalmoscopy:

This method allows the surgeon to see an inverted image of the fundus magnified 3-5 times. It allows examination of the central fundus as well as the periphery.

B. Direct ophthalmoscopy:

Using a direct ophthalmoscope, the fundus is seen erect and magnified 15 times, but the field is small. This method allows detailed examination of the macula and optic disc.

C. Fundus biomicroscopy:

Using the slit lamp and a +90 or +60 diopter lens, a stereoscopic view of the fundus is obtained, valuable in evaluating the macular area, the optic disc and the periphery of the retina.

The appearance of the normal fundus:

1. The optic disc:

- Site: Placed to the nasal side of the posterior pole of the eye.
- Size: Vertically oval 1.8X1.6 mm.
- Color: Pale pink.
- Edges: Well-defined.
- Optic cup: A pale depression, one third disc diameter in size, from which the central vessels emerge, and in which the dots of the lamina cribrosa may be seen. The normal cup is also called the physiologic cup.

2. Macula and fovea:

- a) **The macula** appears yellowish red in color (due to a high content of xanthophyll pigment). The center of the macula lies 2 disc diameters

from, and slightly below the center of the disc. The macula is 6mm in diameter.

b) The fovea is a dark red area in the center of the macula. Its center is depressed and gives a bright reflex when seen by ophthalmoscopy (foveal reflex). It contains only cones. The fovea is approximately one disc diameter in size (1.5 mm).

c) Foveal avascular zone (FAZ) lies within the fovea at the center of the macula, and is 500 um in diameter. It is devoid of retinal capillaries.

3. The retinal vessels:

a. Central retinal artery:

The central retinal artery enters the eye through the physiologic cup. It divides into upper and lower branches. Each divides into nasal and temporal branches. The inner layers of the retina are supplied by the CRA, while the outer layers are supplied by the choriocapillaris. The center of the fovea (foveal avascular zone) is avascular and receives its nutrition from the choroid.

b. Central retinal vein:

It has an upper and lower branches, each has a nasal and a temporal branch. The central retinal vein passes through the centre of the disc to end in the cavernous sinus.

4. The retina proper:

The retina appears pink in color but it is transparent. The pink color is the color of the blood in the underlying choroid. If the retinal pigment is not excessive, the choroidal vessels appear with the choroidal pigment in between. This is called a tigroid or tessellated fundus. If the choroidal pigment is poor, the white sclera can be seen between the choroidal vessels (albinotic fundus).

Diseases of the Retina

Retinal Vascular Disorders

Two basic mechanisms affect the retina in vascular disorders:

1. Abnormal vascular permeability.
2. Retinal ischemia due to generalized arteriolar vasoconstriction. Prolonged constriction results in hemorrhages, exudates, cotton-wool spots (local micro-infarctions) and lipid exudates.

The above mechanisms play a great role in the development of:

- **Vascular Occlusions:**

1. Retinal vein occlusion.
2. Retinal artery occlusion.

- **Vascular Retinopathies:**

1. Diabetic retinopathy.
2. Hypertensive retinopathy.
3. Renal retinopathy.
4. Toxemia of pregnancy.
5. Retinopathy associated with blood disorders: As in sickle cell disease, leukemia, anemias, and hyperviscosity disorders.

Vascular Occlusions of the Retina

I. Retinal Vein Occlusion

May affect the CRV, one, or more of its branches.

Types:

1. Central retinal vein occlusion (CRVO):
 - a. Non ischemic CRVO.
 - b. Ischemic CRVO.
2. Branch retinal vein occlusion:
 - a. Non ischemic.
 - b. Ischemic.

Predisposing factors:

Systemic predisposing factors:

1. Systemic hypertension.
2. Diabetes mellitus.
3. Blood diseases as leukemia, polycythemia, sickle-cell disease.

Ocular predisposing factors:

1. Rise of intraocular pressure.
2. Periphlebitis.

Central Retinal Vein Occlusion

▪ Non-ischemic central retinal vein occlusion:

The site of occlusion is behind the cribriform plate.

Symptoms:

Moderate loss of vision, noticed more in the early hours of the morning following sleep. During sleep, the circulation is sluggish and the venous pressure in the head increases.

Ophthalmoscopy:

1. Tortuosity and dilatation of all branches of the central retinal vein.
2. Retinal hemorrhages, flame-shaped or punctate (dot-and-blot), are scattered at the central fundus and at the periphery in all quadrants.
3. Disc edema.
4. Macular edema.
5. Pupils: Mild afferent pupillary defect.

▪ **Ischemic central retinal vein occlusion:**

Ophthalmoscopy:

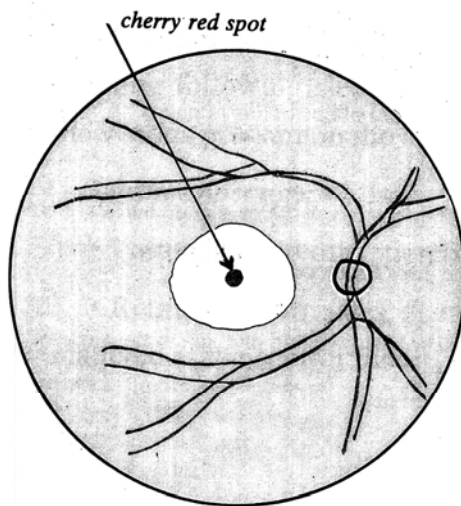
- a. Marked tortuosity of all branches of the central retinal vein.
- b. Extensive retinal hemorrhages.
- c. Cotton wool spots indicating capillary occlusion (microinfarctions).
- d. Extensive disc edema.
- e. Extensive edema at the macular area up to cystoid macular edema.
- f. Pupils: Marked afferent papillary defect.

Complications:

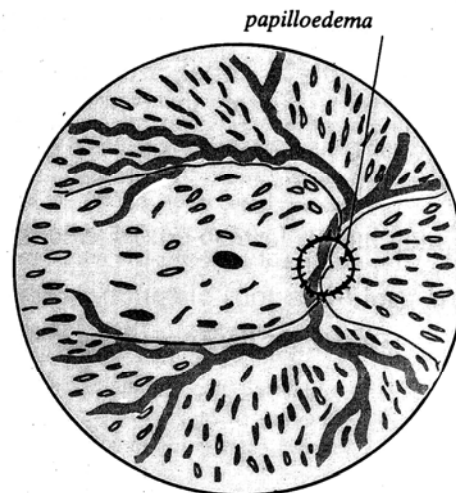
1. Development of new vessels at the disc (NVDs) and elsewhere (NVEs), which may bleed leading to vitreous hemorrhage.
2. Rubeosis iridis (iris new vessels) and new vessels at the angle of the AC cause secondary glaucoma (100-day glaucoma) as it usually occurs 100 days after the onset of the vein occlusion.

Management:

1. Medical and cardiovascular evaluation to detect a cause for thrombosis.
2. Control of hypertension and diabetes.
3. After resolution of hemorrhages, fluorescein angiography is performed to detect ischemia, macular edema and neovascularization.
4. Antiplatelet medication like aspirin 75 mg / day.
5. Argon laser photocoagulation in ischemic cases and in cases developing neovessels or neovascular glaucoma, but only after hemorrhage resolve.
6. Neovascular glaucoma: Is difficult to control and may require:
 - i. Cyclocryotherapy.
 - ii. Insertion of a valve as Ahmed valve or Molteno tube.



C.R.A. occlusion



C.R.V. thrombosis

Branch Retinal Vein Occlusion

Definition:

Occlusion of one of the branches of the central retinal vein. If this branch is more peripheral, vision is not impaired. If the occluded branch is central, macular edema is extensive and vision is impaired.

Ophthalmoscopic picture:

The occluded branch is dilated and tortuous, with hemorrhages along the course of the occluded vein. Macular edema is common.

II. Retinal Artery Occlusion

Retinal artery occlusion is mainly caused by emboli reaching the retinal circulation via the ophthalmic artery, a branch of the internal carotid. The obstruction of blood flow is usually at the level of the lamina cribrosa. Since it is an end artery and has no collaterals, occlusion results in irreversible ischemic infarction of the retina.

Etiology:

1. Thrombosis following atherosclerosis, which is more prevalent in diabetic and hypermetropic patients.

2. Embolism:

- a. Detached thrombus as in:
 - i. Myocardial infarction.
 - ii. Aortic aneurysms.
 - iii. Subacute bacterial endocarditis.
- b. Air embolism.
- c. Fat embolism as in:
 - i. Crush injury.
 - ii. Acute hemorrhagic pancreatitis.

3. Spasm of the central retinal artery as in:

- i. Hypertensive encephalopathy.
- ii. Migraine.
- iii. Quinine poisoning.

4. Arteritis as in:

- i. Giant cell arteritis.
- ii. Polyarteritis nodosa.

5. Raised intraocular pressure: If the pressure is very high as during retinal detachment surgery.

Central retinal artery occlusion (CRAO)

Central retinal artery occlusion is an ocular emergency resulting in sudden painless loss of vision in few hours. Visual loss is associated with Marcus-Gunn pupil (relative afferent pupillary defect, RAPD).

Symptoms:

Sudden unilateral painless loss of vision.

Signs:

1. Normal external appearance of the eye.
2. Pupil: The pupil is dilated with loss of the direct light reflex (RAPD) and preservation of the consensual.
3. Severe impairment of the visual acuity (up to no PL) except in patients with a cilioretinal artery.

Ophthalmoscopy

1. Arteries are attenuated (narrowed).
2. Extensive central retinal edema due to coagulative necrosis of the inner retinal layers and cloudy swelling of the ganglion cells.

3. Cherry red spot at the macular area. The macula receives its supply from the intact choriocapillaris, thus retaining its red color against the rest of the retina which is milky white due to the necrosis.
4. Marked narrowing of the retinal arterioles; the blood may be dark due to stasis, segmentation of the blood column.
5. Consecutive optic atrophy is the end stage.

Fate:

1. Death of the inner half of the retina supplied by the CRA occurs in 5-10 minutes. It is irreversible.
2. The central vision may sometimes be preserved due to the presence of a cilioretinal artery, arising from the posterior ciliary arteries, which enters the fundus near the edge of the disc and supplies the macular area in 15% of the population.

After few weeks, the color of the fundus returns to normal as the macrophages engulf the dead ganglion cells and the disc shows consecutive optic atrophy.

Branch Retinal Artery Occlusion

Branch occlusion is most commonly caused by emboli. Only one or two of the branches of the central retinal artery are occluded leaving the patient with a permanent field defect.

Ophthalmoscopy

A white area of infarction is seen along the course of the occluded artery. It is associated with a field defect corresponding to the area of infarction.

Management of Arterial Occlusions:

Treatment should start immediately. The rationale of treatment is to lower the intraocular pressure and dilate the artery to eliminate the obstruction. The prognosis is bad, but all patients should be treated as an emergency:

1. The patient should lie flat.
2. An attempt is made to restore blood flow in central retinal artery by:
 - a. **Ocular massage** to lower the intraocular pressure (IOP).
 - b. **Intravenous Acetazolamide** 500 mg to lower IOP.
 - c. **Anterior chamber paracentesis**.
 - d. **Inhalation of carbogen mixture** of 5% carbon dioxide and 95% oxygen to dilate the retinal vessels.
3. **Intra venous Streptokinase** injection may be useful in the first 24 hours.
4. **Search for the cause** as it may be due to a life-threatening disease as cardiovascular disease, or emboli.

Prognosis:

The prognosis is very poor.

Retinopathies

Definition: Bilateral affection of the retina due to a systemic disease.

I. Diabetic Retinopathy

Diabetic retinopathy is microangiopathy affecting retinal capillaries, arterioles and venules.

Risk factors for developing diabetic retinopathy (DR):

1. The duration of diabetes: The longer the duration of diabetes, the more likely it is to develop retinopathy. Almost 50% of diabetic patients develop retinopathy after 10 years and almost 90% develop retinopathy in 30 years.

2. Metabolic control: Good metabolic control does not prevent retinopathy, but it merely delays its onset.

3. Miscellaneous factors: Pregnancy, hypertension, renal disease, smoking, and anemia have an adverse effect on DR.

Pathogenesis of diabetic retinopathy:

1) Changes in blood characteristics, mainly:

- Lack of red cell deformability.
- Increased stickiness and aggregation of platelets.

2) Micro vascular leakage due to breakdown of blood retinal barrier.

Clinical types of diabetic retinopathy:

A. Background Diabetic Retinopathy (BDR):

The main findings in background type are:

1. Microaneurysms.
2. Hemorrhages, deep, in the form of blots and dots.
3. Hard exudates.

4. Retinal edema: When close to the macular area, vision is seriously affected.

B. Pre-Proliferative Diabetic Retinopathy (PPDR):

It is due to retinal ischemia and shows the following:

1. Venous changes in the form of beading and looping.
2. Hemorrhages.
3. Cotton-wool spots due to capillary occlusion.
4. Intra-retinal micro-vascular abnormalities (IRMA).
5. Extensive areas of ischemia, which may be detected by FA.

C. Proliferative diabetic retinopathy (PDR):

- 1) Neovascularization may develop at the optic disc (NVDs) or at the retina along the course of retinal vessels, new vessels elsewhere (NVEs). These new vessels are unhealthy and liable to leak. They are also liable to repeated hemorrhage.
- 2) Vitreous detachment.
- 3) Hemorrhage, which may be retinal, preretinal (subhyaloid) or vitreous hemorrhage.
- 4) Later, fibrosis occurs around the new vessels exerting traction on the retina resulting in tractional retinal detachment (retinitis proliferans).

D. Diabetic maculopathy:

Definition:

Diabetic maculopathy is the presence of any retinal thickening or hard exudates within the macula.

Involvement of the macula by edema and/or hard exudates is the most common cause of visual impairment in diabetic patients.

Clinical presentation of diabetic macular edema (DME):

1. Focal (circinate).
2. Diffuse (cystoid).
3. Ischemic.
4. Mixed.

Complications of diabetic retinopathy:

In cases where laser treatment was not implemented in the early stages of the disease, the following vision-threatening complications may occur:

1. Persistent vitreous hemorrhage.
2. Retinal detachment.
3. Opaque membranes.
4. Rubeosis iridis, which may lead to neovascular glaucoma.

Management of diabetic retinopathy:

1. Control of blood sugar.
2. Follow-up of diabetic patients and regular fundus examination:
 - ◆ Without retinopathy: Yearly.
 - ◆ Mild non-proliferative diabetic retinopathy: Every 9 months.
 - ◆ Moderate & severe: Every 4 months.
3. Fluorescein angiography (FA) is done to detect leaking areas and ischemic changes.
4. In cases with clinically significant macular edema, focal or grid argon laser photocoagulation is indicated.
5. If the patient develops new vessels (NVDs or NVEs or rubeosis iridis), pan retinal photocoagulation is indicated using argon or diode laser.

6. Vitrectomy: In cases where the patient develops:
 - a. Recurrent vitreous hemorrhage.
 - b. Tractional retinal detachment.
 - c. Rubeosis iridis associated with vitreous hemorrhage is an indication for vitrectomy and intraoperative pan-retinal photocoagulation (endolaser) to prevent neovascular glaucoma.
 - d. Macular epiretinal membrane distortion.
 - e. Severe retinal neovascularization unresponsive to photocoagulation.

Treatment of macular edema:

1. Laser treatment:
 - a. Focal → focal laser treatment.
 - b. Diffuse → grid or modified grid treatment.
 - c. Ischemic → no laser treatment.
2. Intravitreal injections (IVTA):
 - a. Intravitreal injection of TAA (Triamcinolone Acetonide).
 - b. Intravitreal injection of anti VEGF (vascular endothelial growth factors).

II. Hypertensive Retinopathy

Retinal arterioles respond to hypertension by narrowing.

Fundus picture

1. Vasoconstriction: Localized or generalized.
2. Leakage due to abnormal permeability of the vessel walls, leading to flame-shaped hemorrhages, retinal edema and hard exudates. Disc edema develops in malignant hypertension
3. Arteriosclerosis causes thickening of the vessel walls. Arteriovenous crossing changes constitute the most important finding.

Grading of Hypertensive Retinopathy

1. **Grade 1:** Mild generalized arteriolar attenuation especially branches.
2. **Grade 2:** More severe, generalized, and focal arteriolar constriction associated with deflection of veins at arteriovenous crossings (Salus sign).
3. **Grade 3:** Copper wiring of arterioles, banking of veins distal crossing changes, tapering of veins on either side of the crossing and right-angled deflections of veins. These findings are associated with flame-shaped hemorrhages, cotton wool spots and hard exudates.
4. **Grade 4:** All of the above changes as well as silver wiring of arterioles and disc swelling.

Other ocular complications of hypertension

Hypertension also plays a role in:

1. Branch retinal vein occlusion.
2. Retinal artery occlusion.
3. Ischemic optic neuropathy.

4. Ocular motor nerve palsy.
5. Uncontrolled hypertension also has an adverse effect on diabetic retinopathy.
6. Retinal artery macro-aneurysms.

III. Retinopathy due to Malignant Hypertension & Renal Failure

1. If it occurs on top of benign hypertension, vessels will show changes of hypertensive retinopathy, but if it develops rapidly, the vessels are attenuated and straight.
2. Hemorrhages of all types:
 - a. Flame-shaped.
 - b. Dot and blot, and may be confluent.
3. Exudates may radiate from the fovea along Henle's fiber layer to macular fan or star.
4. Cotton-wool spots: Numerous and are a manifestation of arteriolar occlusion. They are micro- infarctions.
5. Edema of the disc is common (papilledema).
6. Sometimes diffuse retinal edema, especially in renal cases, causing exudative RD.
7. Death from renal failure unless treated.

VI. Retinopathy due to Toxemia of Pregnancy

Definition:

A bilateral retinal affection secondary to toxemia of pregnancy.

Pathology:

1. The disease affects females after the 20th week of pregnancy.
2. Due to the effect of hypertension in toxemia of pregnancy, retinal arterioles show marked vasoconstriction leading to ischemia.

Symptoms:

In severe cases, the patient presents with the following:

1. Mild cases may show no symptoms.
2. In severe cases, metamorphopsia and blurring of vision due to macular exudates and hemorrhage.
3. Rapid painless diminution of vision due to exudative retinal detachment.

Signs:

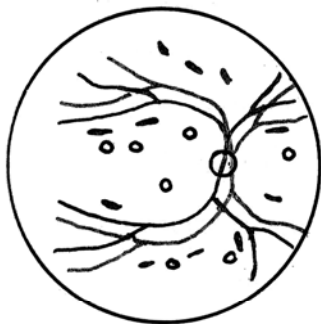
1. Spasm and narrowing of retinal arterioles.
2. Flame-shaped hemorrhages.
3. Cotton wool exudates due to microinfarctions.
4. Papilledema.

Treatment:

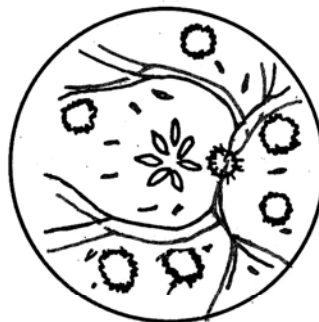
Termination of pregnancy is indicated if the patient develops an exudative retinal detachment characterized by rapid bilateral onset in the absence of retinal breaks. The retinopathy resolves after termination of pregnancy and the prognosis for vision is good.

Table (13): Differential diagnosis of retinopathies

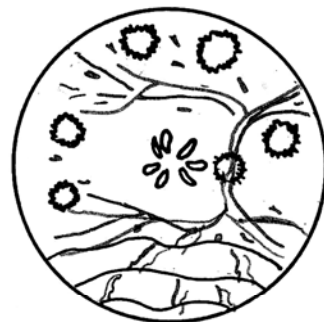	Arteriosclerosis and benign hypertension	Malignant and renal hypertension	Toxemia of pregnancy
Vessels	Arteriosclerosis	Arteriosclerosis or spasm	Spasm
Hemorrhages	Flame-shaped	Flame-shaped	Flame-shaped
Exudates	Deep round	cotton wool patches	Cotton wool patches
Macular Star	Absent	Present	Present
Edema	Absent	Retina and disc	Retina and disc + detachment



Arteriosclerosis and B. Hypertension



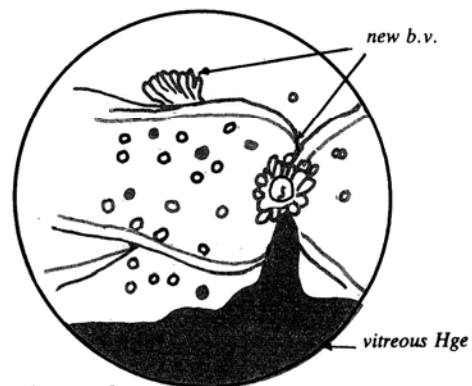
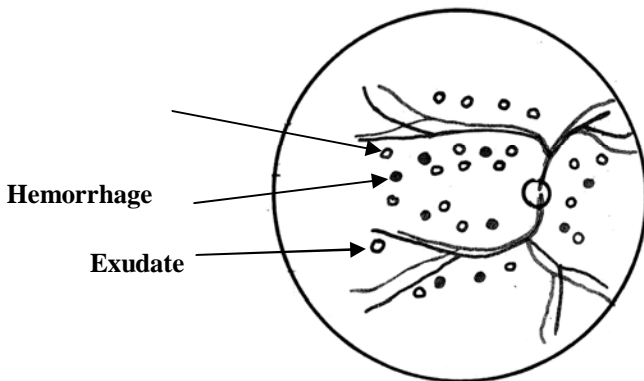
Renal and Malignant hypertension



Eclampsia

Simple

Proliferative



Diabetic retinopathy

Photoreceptor Dystrophies

Retinitis pigmentosa (Pigmentary Retinopathy)

Retinitis pigmentosa is a group of hereditary disorders characterized by progressive loss of photoreceptors (rod-cone dystrophy) and RPE function, resulting in retinal degeneration.

The affection starts at the equator then spreads anteriorly then posteriorly.

Etiology: Definite cause is unknown, Inheritance plays a role.

Inheritance:

The hereditary pattern in RP could be:

1. Autosomal dominant.
2. Autosomal recessive.
3. X-linked.

Clinical Picture:

1. The patient presents with defective dark adaptation (night blindness).
2. Later, progressive loss of vision.
3. Gradual concentric contraction of the peripheral field.

4. **Ophthalmoscopy:**

- a) Arteriolar attenuation.
- b) Spider-like pigmentations at the equator and periphery of the retina.
- c) Later, waxy disc pallor of the optic disc due to consecutive optic atrophy.

Electrophysiological tests:

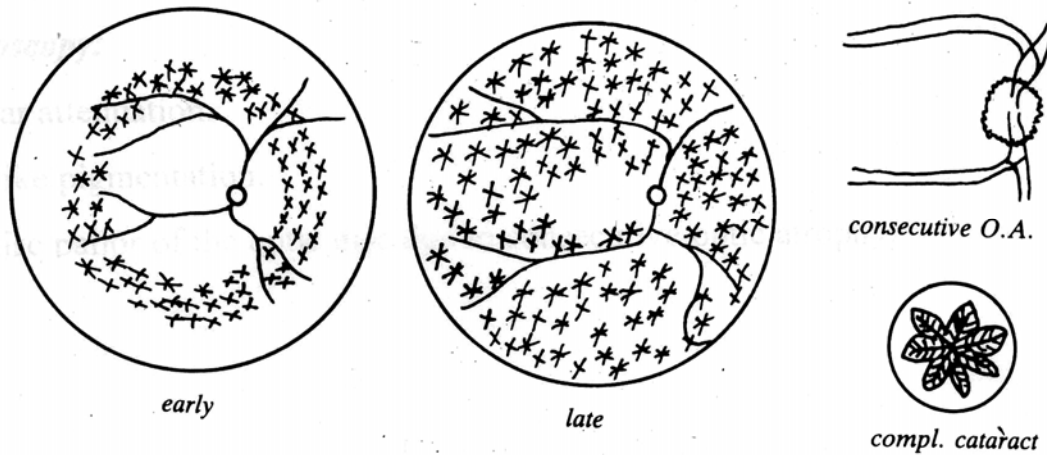
Electroretinogram (ERG) is markedly diminished especially scotopic ERG.

Syndromes associated with retinitis pigmentosa:

1. Laurence-Moon-Biedl syndrome:
 - a. Obesity.
 - b. Hypogenitalism.
 - c. Mental retardation.
 - d. Polydactyly.
2. Refsum's disease:
 - a. Deafness.
 - b. Ataxia.
 - c. Polyneuropathy.
 - d. Electro-oculogram (EOG) changes.

Prognosis:

Loss of visual acuity may be due to macular affection, cataract or consecutive optic atrophy.



Retinitis Pigmentosa

Age-Related Macular Degeneration (ARMD)

It is a visual loss associated with drusen and atrophy of the RPE in patients above the age of 50 years. There are two main types, dry and wet. Wet ARMD is due to abnormal new vessels growing from the choroid under the retina resulting in macular edema with severe loss of vision.

Retinal Detachment (RD)

Definitions and Classifications:

RD is separation of the sensory retina (inner retinal layer) from the retinal pigment epithelium (RPE, outer retinal layer) by subretinal fluid (SRF). There are two main types:

I. Primary or rhegmatogenous RD:

Caused by a retinal break, which permits fluid, derived from the liquefied vitreous (subretinal fluid or SRF) to gain access to the subretinal space.

II. Secondary or non-rhegmatogenous RD:

Not caused by a retinal break. It has two types.

A. Tractional:

In which the sensory retina is pulled away from the RPE by contracting fibrous tissue in the vitreous (vitreoretinal traction), e.g. proliferative stage of diabetic retinopathy, cyclitic membrane, retinopathy of prematurity. The source of SRF is not known.

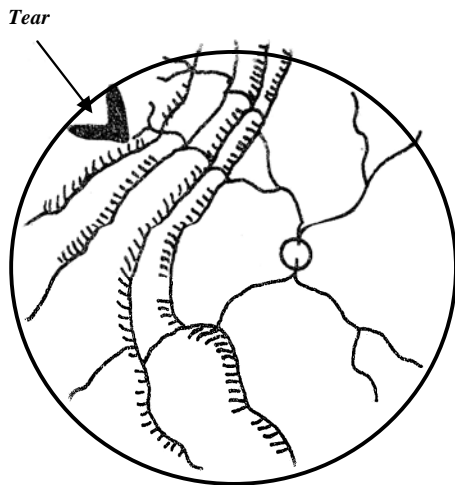
B. Exudative:

In which the retina is pushed off the choroid. The SRF, derived from the choroid, gains access to the subretinal space through the damaged RPE, e.g. exudative choroiditis, toxemia of pregnancy, choroidal hemangioma, and malignant melanoma of the choroid.

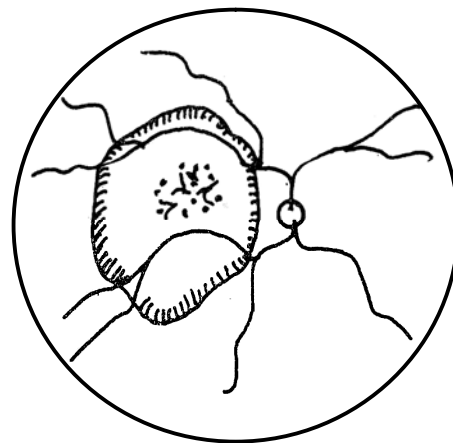
Primary (Rhegmatogenous) Retinal Detachment

The retinal breaks responsible for RD are caused by interplay between:

1. Dynamic vitreoretinal traction.
2. Weakness in the peripheral retina, referred to as predisposing peripheral retinal degeneration.



Simple (Rhegmatogenous) Detachment



Malignant Detachment

Simple and Malignant Retinal Detachment

Risk Factors:

1. High myopia.
2. Aphakia.
3. Trauma (blunt or perforating).
4. Family history of RD or history of RD in the fellow eye.

Retinal breaks:

A retinal break is a full-thickness defect in the sensory retina. Breaks can be classified according to pathogenesis, morphology and location.

Pathogenesis:

1. Tears are caused by dynamic vitreoretinal traction. They have a predilection for the upper fundus (temporal more than nasal).
2. Holes are caused by chronic atrophy of the sensory retina. They have a predilection for the temporal fundus (upper more than lower). They are less dangerous than tears (less risk of RD).

Types of retinal breaks:

1. Retinal holes: Are round or oval.
2. Retinal tears: Horse-shoe tears (U-shaped).
3. Retinal disinsertion: At the ora serrata.

Clinical Picture:

Symptoms:

1. Flashes of light (photopsia): Photopsia is caused by traction at sites of vitreoretinal adhesion. The cessation of photopsia is the result of either separation of the vitreoretinal adhesion or complete tearing away of a piece of the retina (operculum) around the site of adhesion.

2. Floaters (musca volitantes): Are moving vitreous opacities perceived by the patient when they cast a shadow onto the retina. A sudden shower of minute red-colored or dark spots usually indicates vitreous hemorrhage secondary to tearing of a peripheral retinal blood vessel.

3. Visual field defect: Is caused by spread of subretinal fluid behind the equator. It is perceived by the patient as a black curtain. The quadrant of the visual field in which the field defect appears first is useful in

predicting the location of the primary retinal break (which will be in the opposite quadrant).

4. Loss of central vision: Due to involvement of the fovea by subretinal fluid (foveal detachment).

Signs:

1. Visual acuity: Depends on whether the fovea is involved and on the extent of RD. In total RD, vision is usually hand movement (HM).
2. The intraocular pressure is usually lower by about 5 mmHg as compared to the normal eye. This is caused by absorption of SRF by the choroid.
3. Red reflex is grey.
4. Slit-lamp examination reveals:
 - A mild iritis is common.
 - The retrolental vitreous shows pigment cells (tobacco dust).
5. Fundus examination reveals:
 - a. Retinal break(s) appear as red discontinuities in the retinal surface.
 - b. The subretinal fluid may extend up to the ora serrata and gives the retinal surface a wavy appearance.
 - c. The retinal findings depend on the duration of retinal detachment and the presence or absence of proliferative vitreoretinopathy.

Proliferative Vitreo-Retinopathy (PVR)

PVR is caused by proliferation of membranes on the inner retinal surface (epiretinal membranes), on the detached posterior hyaloid surface and occasionally on the outer retinal surface (subretinal membranes).

Severe postoperative contraction of these membranes is the most common cause of failure in RD surgery.

The main clinical signs of PVR are retinal folds and rigidity so that retinal mobility induced by eye movements is decreased.

Tractional Retinal Detachment

The main causes of tractional RD are:

1. Proliferative diabetic retinopathy (most common).
2. Retinopathy of Prematurity (ROP).
3. Proliferative sickle cell retinopathy.
4. Penetrating posterior segment trauma.

Exudative Retinal Detachment

Exudative RD is much less common than both rhegmatogenous and tractional RD. It is caused by disorders that damage the RPE and thereby allows the passage of fluid derived from the choroid into the subretinal space as in the following:

1. Choroidal tumors such as melanoma, hemangioma and metastases.
2. Intraocular inflammation such as Harada's disease and posterior scleritis.
3. Iatrogenic causes such as retinal detachment surgery and panretinal laser photocoagulation.
4. Subretinal (choroidal) neovascularization.
5. Systemic causes such as severe hypertension, toxemia of pregnancy and hypoproteinemia.

Examination of a case of retinal detachment:

1. Indirect Ophthalmoscopy to detect:-
 - a. Extent of RD.
 - b. Site, shape, size and number of retinal breaks.
 - c. State of the macula.
 - d. Presence and severity of PVR.
2. Slit-lamp Biomicroscopy:
 - a. Using the Goldmann three-mirror contact lens.
 - b. Using a non contact lens +90 or +60 diopter lens.
3. Ultrasonography:

B-scan Ultrasonography is extremely useful in:

- a. Patients with opaque media (e.g. corneal opacities, cataract or vitreous hemorrhage), suspected to have RD.
- b. Exudative RD with suspected intraocular tumor.

Management of Rhegmatogenous retinal detachment:

A-Prophylactic treatment:

Indications:

- Flat retinal tears.
- Peripheral retinal lesions predisposing to RD.

Treatment Modalities:

The retinal tear is surrounded with either:

1. Two or three rows of argon laser photocoagulation.
2. A single row of cryo applications.

B-Scleral Buckling (standard retinal surgery):

Principle:

1. To seal the retinal break(s) by surrounding it (them) with a single row of cryo applications. Cryotherapy creates, an inflammatory chorioretinal lesion, which on scarring, results in strong adhesion between the sensory retina and RPE. This results in permanent sealing of retinal breaks.
2. Creation of inward indentation of the sclera (buckle) at the site of retinal break(s), using an inert explant sutured to the sclera. The two main purposes of scleral buckling are:
 - Closure of retinal break(s) by opposing the RPE to sensory retina.
 - Reduction of vitreoretinal traction.
3. With or without drainage of sub retinal fluid.

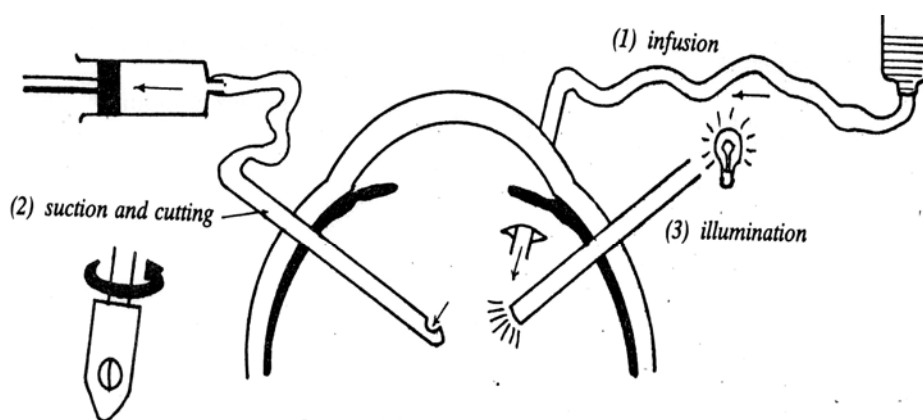
C- Pars Plana Vitrectomy:

Principle:

Vitrectomy is a microsurgical procedure (done under the operating microscope), designed to remove the vitreous gel in order to gain access to a diseased retina. The approach is via three separate incisions in the pars plana, one incision for introduction of infusion fluid, the second for introducing illumination, and the third for the vitreous cutter and aspiration.

Indications:

1. In rhegmatogenous RD:
 - To clear vitreous opacities e.g. vitreous hemorrhage, to visualize retinal breaks.
 - Very large breaks including giant retinal breaks.
 - Posterior retinal breaks including macular holes.
 - RD associated with PVR.
2. In proliferative diabetic retinopathy:
 - Unresolving vitreous hemorrhage.
 - Tractional RD involving the macula.
 - Combined tractional and rhegmatogenous RD.



Principle of Vitrectomy

Table (14): Differential diagnosis of retinal detachment

	Simple detachment	Malignant detachment
Incidence	Common	Rare
History	Trauma	-
Refraction	Usually myopic	Any refraction
Tension	Soft	May be elevated
Fundus:		
- onset	Starts peripheral	Starts central
- tear	Present	Absent
- retina	Wavy and tremulous	Tent-like not tremulous
- abnormal pigment & B.V.	Absent	Present
Transillumination	Translucent	Opaque
Ultrasonography	No solid tissue	Solid tissue under retina

Retinoblastoma

It is the most common primary intraocular malignancy in childhood. It occurs in about 1 in 20,000 live births. It almost always presents prior to the age of 3 years.

A positive family history is present in only 6% of cases, while sporadic cases account for the remaining 94% of cases. The tumor may be bilateral in 20% of the cases.

It is thought to be caused by a mutation in a gene on chromosome 13.

Clinical features:

Retinoblastoma may present as:

1. Leukocoria (from Latin leukos=white and coria=pupil): White pupillary reflex, accounts for 65% of cases.
2. Squint: If the tumor affects the macular area.
3. Secondary glaucoma.
4. Proptosis due to extraocular extension.
5. Accidental discovery on routine examination.

Diagnosis: Is based on:

1. Ophthalmoscopy: With maximal pupillary dilatation, preferably under general anesthesia. It is of extreme importance to examine both eyes due to the relatively high incidence of bilaterality.
2. X-ray may show tumor calcification.
3. Ultrasonography.
4. Computerized Tomography (CT scan).

Treatment:

A. Quiescent stage:

1. Photocoagulation for small central tumors.
2. Trans-scleral cryotherapy.
3. Diode laser photocoagulation for small peripheral tumors.
4. Radiotherapy.
5. Trans-pupillary Thermo-Therapy (TTT) for medium tumors.

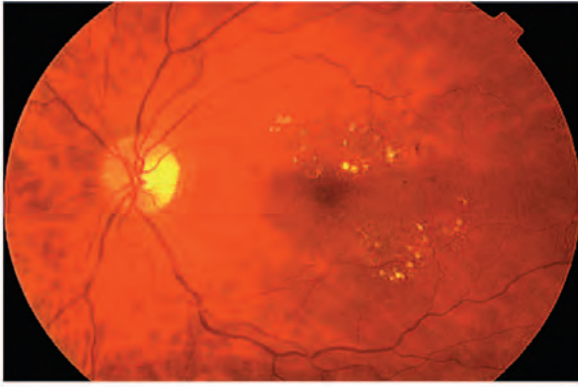
B. Glaucomatous stage: Enucleation with excision of a long stump of the optic nerve.

C. Extra-ocular (orbital) extension stage: Orbital exenteration.

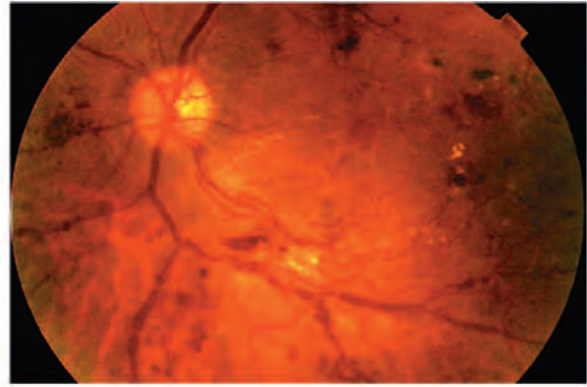
D. Distant metastases stage: Systemic chemotherapy.

Differential Diagnosis of white pupil (leukocoria) in infants:

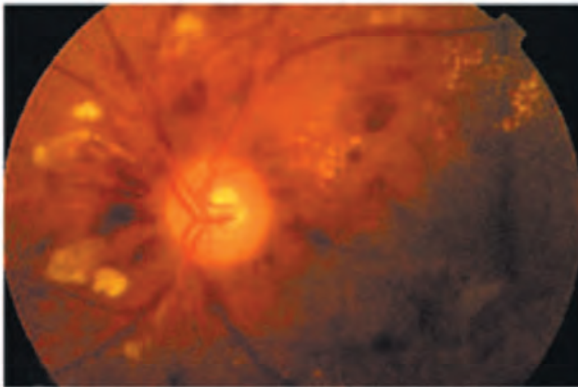
1. Retinoblastoma.
2. Congenital cataract.
3. Retinopathy of prematurity: Failure of vascularization of the peripheral retina in prematures exposed to high oxygen concentration in incubators with subsequent fibrosis and tractional retinal detachment.
4. Persistent Hyperplastic Primary Vitreous: Congenital anomaly with fibrosis of the anterior vitreous.
5. Coat's disease: Unilateral extensive leakage from the retinal vessels resulting in large masses of subretinal lipids.
6. Retinal dysplasia: Chromosomal defect resulting in development of a disorganized retina.



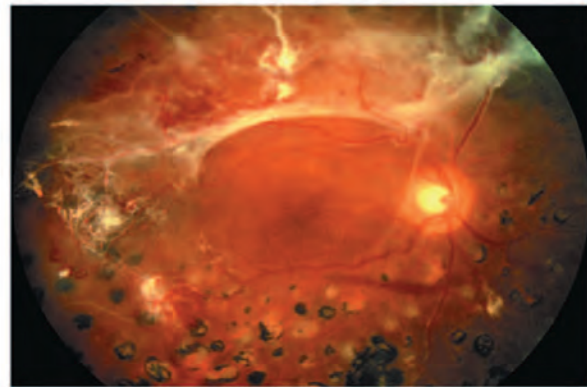
Hard exudates and microaneurysms



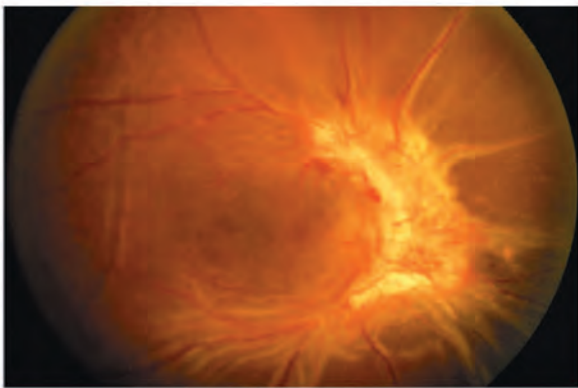
Cotton-wool spot, severe venous changes and dark blot haemorrhages



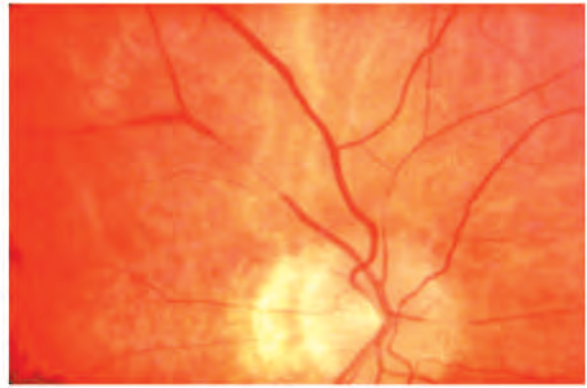Flame-shaped and dark blot haemorrhages, cotton-wool spots and hard exudates



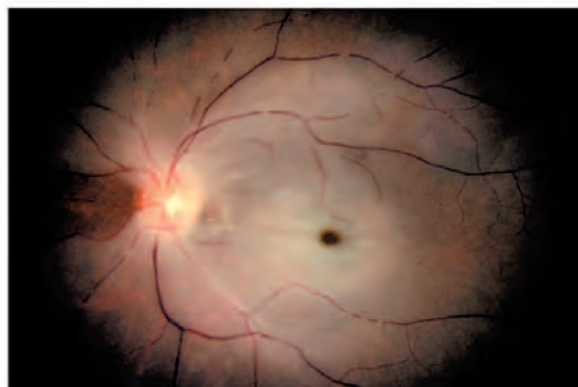
Localised superior tractional retinal detachment and laser scars inferiorly



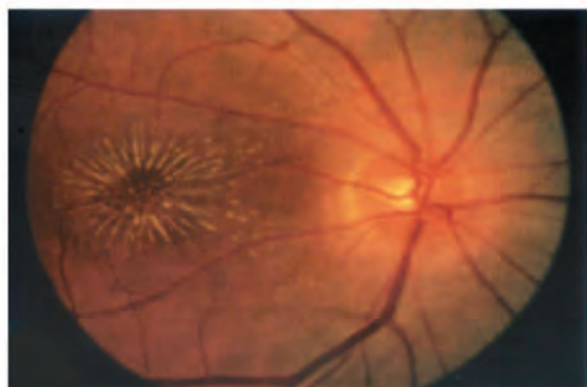
Extensive tractional retinal detachment



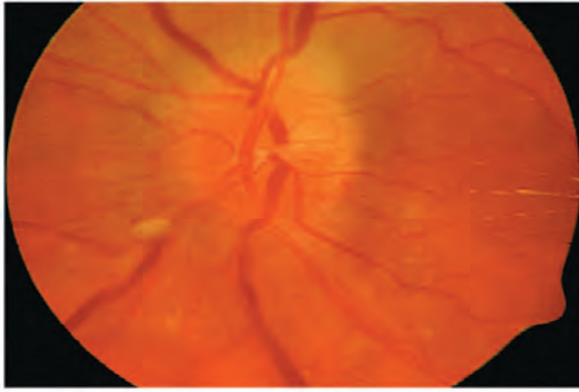
Focal and generalized arterial narrowing



Central retinal artery occlusion
(Cherry red spot)



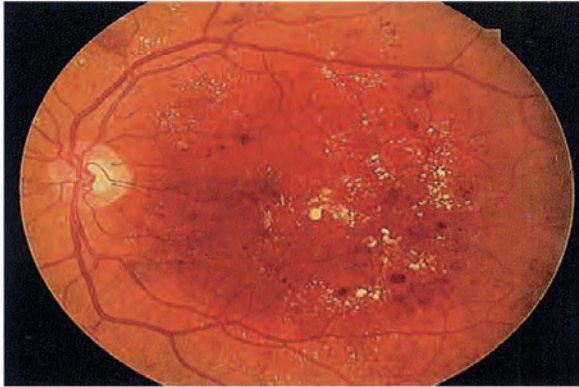Macular star



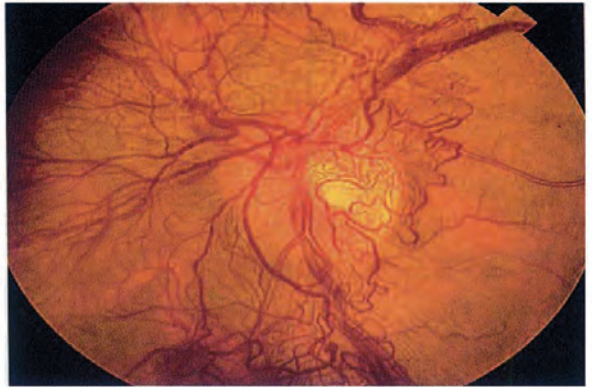
Mild disc oedema in malignant hypertension



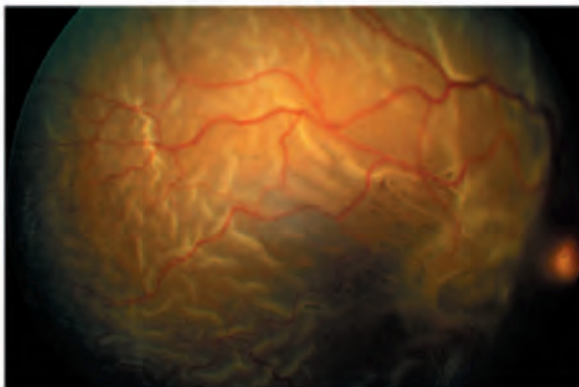
Retinal hole in flat retina



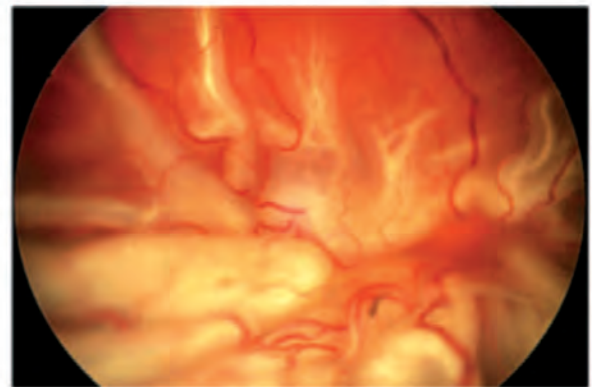
Severe background diabetic retinopathy



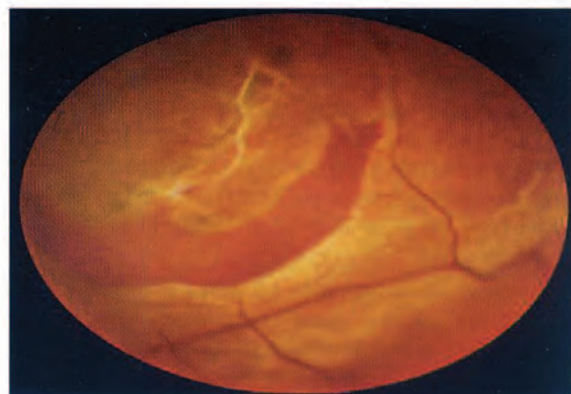
Severe NVD



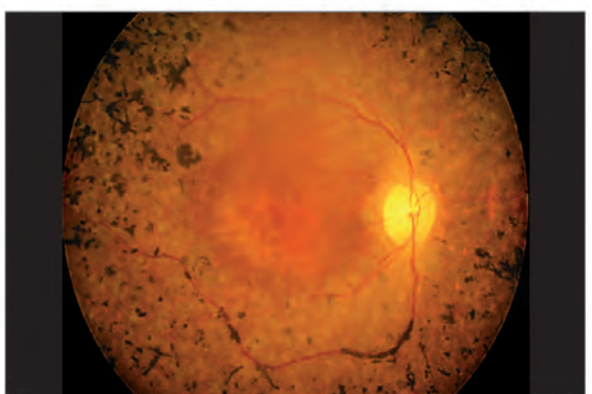
Extensive retinal detachment



End-stage PVR



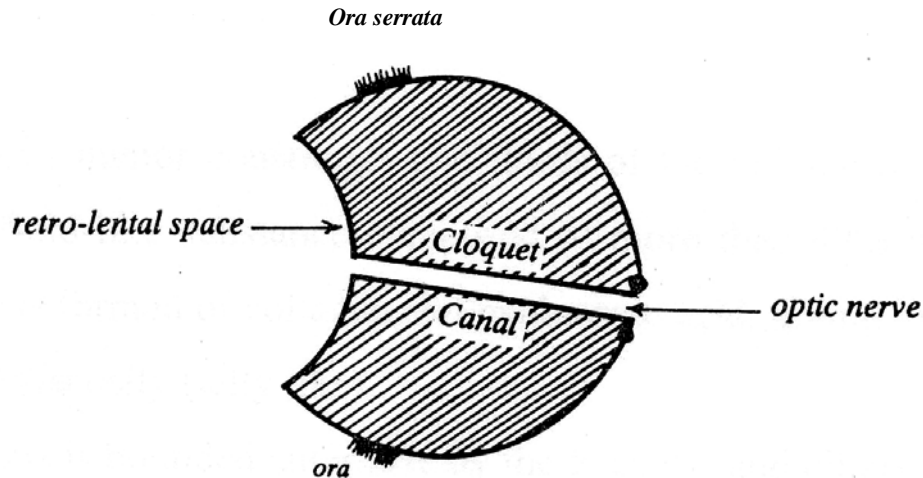
Retinal detachment with tear



Retinitis pigmentosa with severe arteriolar attenuation and waxy disc pallor

Chapter 12

Vitreous



Anatomy of the Vitreous

Anatomy

The vitreous humor constitutes two thirds of the volume of the entire globe. It is a fluid-like substance composed of more than 99% water. The remaining part is formed of collagen and hyaluronic acid, giving the vitreous its rigidity and viscosity (jelly like).

The vitreous is bounded anteriorly by the lens, iris and ciliary body, and posteriorly by the retina and optic disc.

The outer portion of the vitreous body is denser than the center and called the cortex, and its surface is called the hyaloid membrane.

In youth, the anterior hyaloid is fixed firmly to the posterior lens surface; this attachment becomes weaker with age.

Cloquet's canal runs anteroposteriorly in the center of the vitreous and is the site of the embryonic hyaloid artery. The strongest attachment of the

vitreous is to the retina and pars plana in the area of the vitreous base, straddling the ora serrata.

Functions of the vitreous:

1. Stabilizes the volume of the globe.
2. Acts as a cushion for the retina.
3. One of the optical media of the eye.

Diseases of Vitreous

Aging changes of the vitreous

Age-related changes of the vitreous include liquefaction (synchysis). This results in the formation of fluid lacunae inside the vitreous gel. These may rupture through the cortical vitreous and cause separation of the cortical vitreous from the inner retinal surface (posterior vitreous detachment). The patient may complain of flashes of light (photopsia) and vitreous floaters. The patient describes it as black dots, rings or other shapes moving in his/her field of vision (Musca volitantes).

Vitreous Hemorrhage

Causes:

1. Proliferative retinopathies, as diabetic retinopathy.
2. Retinal breaks.
3. Central retinal vein occlusion.
4. Trauma.
5. Blood diseases as anemia, leukemia and purpura.
6. Intraocular tumors.

Fate of vitreous hemorrhage:

- Absorption is very slow.
- Retinitis proliferans leading to retinal detachment.

Degenerative vitreous changes

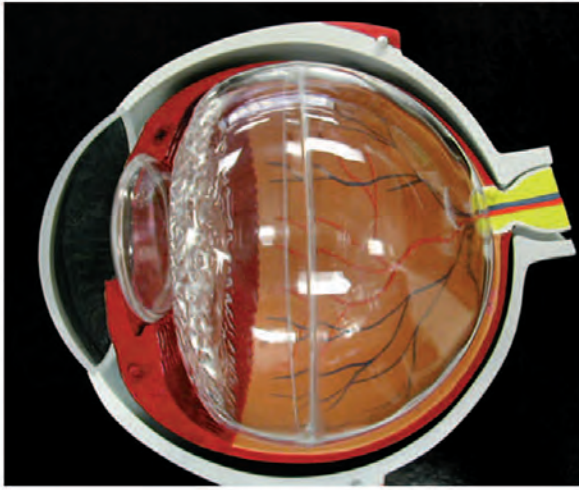
1. Asteroid hyalosis:

The condition is characterized by the presence of small oval, reflective, white-to-yellow opacities attached to formed vitreous. Usually unilateral in old age. Patients are usually asymptomatic and vision is rarely affected.

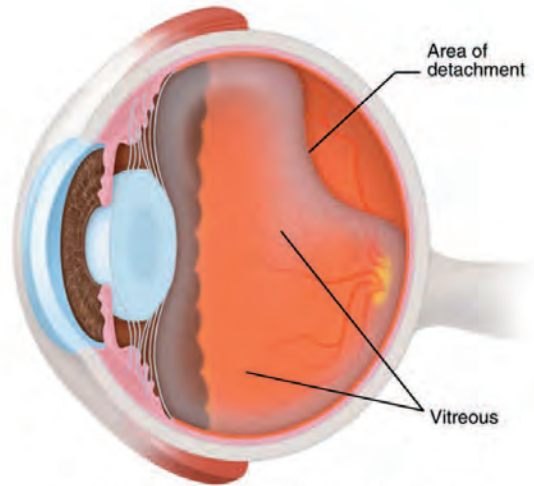
The opacities are formed of calcium and phosphorus.

2. Synchysis Scintillans:

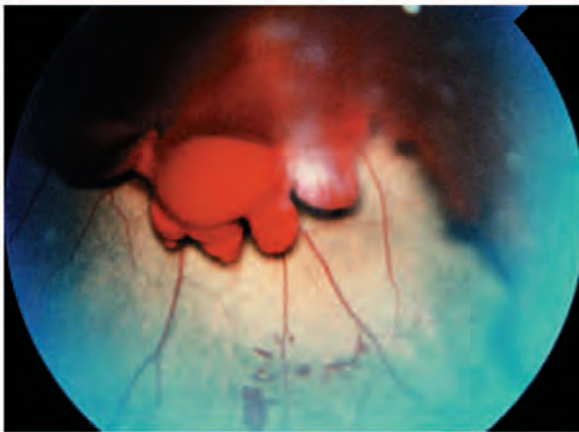
This condition is characterized by the presence of fine, highly refractile crystals in degenerated (liquified) vitreous, usually in young age. These crystals are composed of cholesterol esters. The condition is usually bilateral. The crystals are mobile, settle down by rest, and disperse on eye movement.




Diagrammatic illustration of the vitreous humour



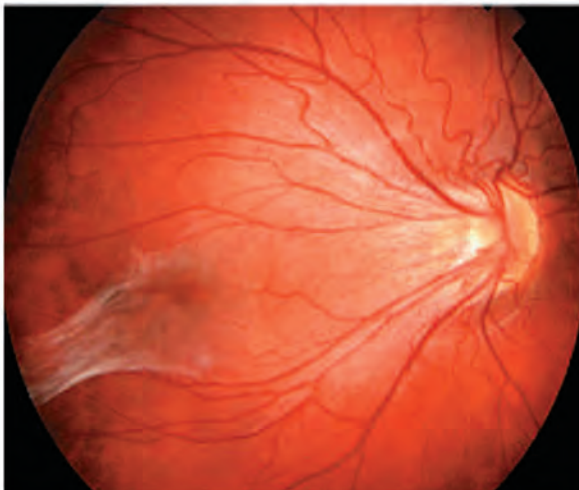Partial detachment of the posterior vitreous



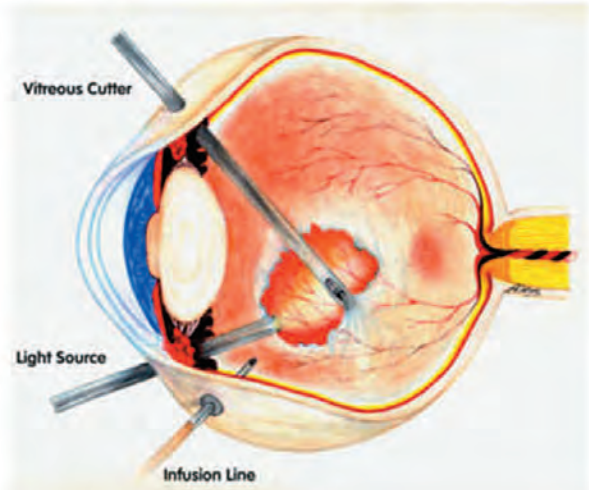
Vitreous haemorrhage



Subhyaloid (pre-retinal) haemorrhage



Vitreoretinal fibrosis



Diagrammatic illustration of vitrectomy technique

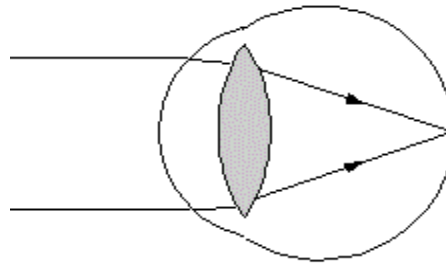
Chapter 13

Errors of Refraction

Definitions:

1. Emmetropia:

Emmetropia is the state of refraction of the eye in which, with accommodation completely relaxed, parallel rays come to a focus on the retina.

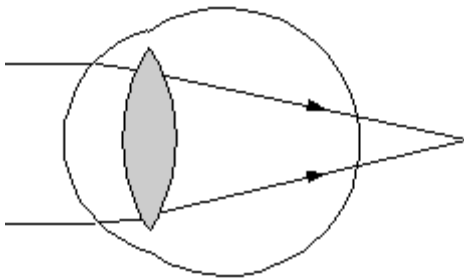


Emmetropic eye

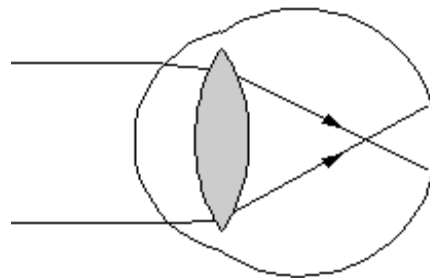
2. Ametropia:

Ametropia is the state of refraction of the eye in which, with accommodation completely relaxed, parallel rays do not come to a focus on the retina. It is the presence of an error of refraction.

Hypermetropia



Myopia



Errors of refraction

Types of ametropia:

1. Myopia.
2. Hypermetropia.
3. Astigmatism.
4. Anisometropia.
5. Aphakia.

Measurement of refractive errors (Refraction):

Determination of refractive correction can be achieved by objective or subjective means and is best accomplished by a combination of both.

a. Manual retinoscopy can be performed by using a plain mirror and a source of light to produce a red reflex or by a retinoscope which projects light directly into the eye.

b. Automated refractometers are available for rapidly determining objective refraction.

Retinoscopy is done after inducing cycloplegia by Cyclopentolate or Atropine.

Myopia

Definition:

Myopia or shortsightedness is the error of refraction in which, with accommodation completely relaxed, parallel rays come to a focus in front of the retina.

Etiology:

1. Axial myopia: When the eye is longer than average.
2. Index myopia: When the refractive index of the cornea or the lens nucleus is more than average.

3. Curvature myopia: Due to increase in the curvature of the cornea or the lens.
4. Abnormal position of the lens: e.g. anterior dislocation.

Types :(Table 15)

1. Simple: Usually does not progress after adolescence when it reaches -5 or -6 diopters.
2. Progressive (high myopia): Which increases steadily up to 25 years or beyond and may reach more than -25 diopters. It is hereditary, more common in women, and has a racial tendency.
3. Congenital: The child is born with an abnormally long eye giving a refraction of about -10 diopters but progression is rare.

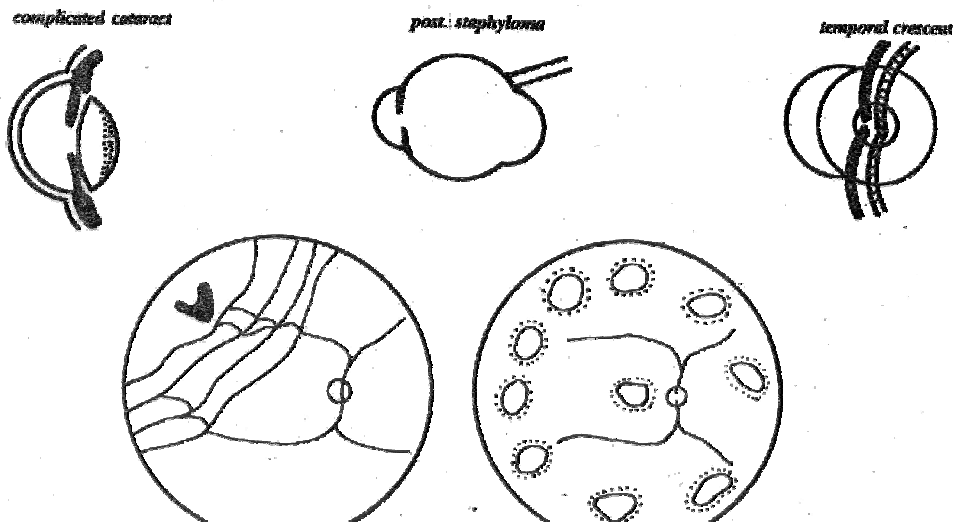
Symptoms:

1. Indistinct far vision.
2. Screwing of eyelids to simulate a pinhole which increases the depth of focus.
3. Defective night vision (in progressive myopia).
4. Musca volitans.

Complications of high myopia:

1. Divergent squint.
2. Complicated cataract.
3. Peripheral chorio-retinal degenerations, retinal breaks and retinal detachment.
4. Macular complications:
 - Fuch's spot (A black area at the macula which leads to loss of central vision).
 - Macular hemorrhage.
 - Macular hole.

5. Vitreous degenerations: Floaters and posterior vitreous detachment.
6. Consecutive optic atrophy.
7. Posterior staphyloma: High myopia is the only cause of posterior staphyloma.
8. Lens subluxation and dislocation.
9. Increase incidence of glaucoma (Primary open angle and pigmentary).



Complications of degenerative myopia

Table (15): Types of myopia

	Simple Myopia	High Degenerative Myopia
Onset	Later (around 14 years)	Earlier (around 7 years)
Progresses till	Less than 20 years	More than 20 years
Degree	Less than -6 dioptries	-15 to -25 dioptries or more
Degenerative Changes:	Absent	Present

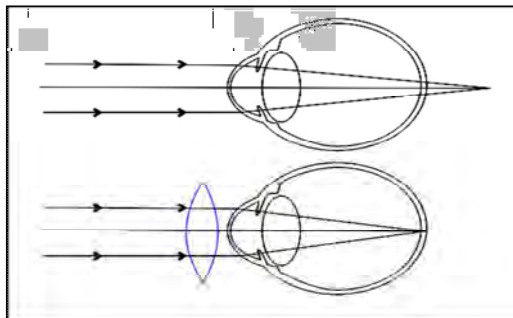
Correction of myopia:

1. Glasses using concave spherical (minus) lenses to move the image back to the retina.
2. Contact lenses.
3. Refractive surgery can be done when indicated.
 - a. Mild: LASIK.
 - b. Moderate: LASIK (up to -10.0 D).
 - c. High: Phakic IOL or clear lens extraction.

Hypermetropia

Definition:

Hypermetropia (hyperopia) or far sightedness is the error of refraction in which, with accommodation completely relaxed, parallel rays come to a focus behind retina.



Hypermetropia

Etiology:

1. Axial: When the eye is shorter than average.
2. Curvature: Due to decreased curvature of the cornea or lens.
3. Index: When the refractive index of the cornea or the lens nucleus is less than average.
4. Aphakia or posterior displacement of the lens.

Symptoms:

1. Blurring of near objects.
2. Accommodative asthenopia (eye strain).
3. Early presbyopia.

Complications:

1. Squint: Esophoria, and esotropia.
2. Primary angle closure glaucoma: Due to the shallow anterior chamber and narrow angle.

Correction of hypermetropia:

1. Glasses: Using convex spherical (plus) lenses to move the image forward to the retina.
2. Contact lenses: Can be used but are usually less tolerated than in myopia.
3. Refractive surgery (LASIK): Can be done when indicated but the procedure is less successful than in myopia.

Astigmatism

Definition:

Astigmatism (a=not; stigma=point) is the error of refraction in which, with accommodation completely relaxed, parallel rays do not form a point focused on the retina. Instead, the eye produces an image with multiple focal points or lines i.e. the eye has different refractive powers in different meridians.

Etiology:

Corneal astigmatism is the most common and may be induced by surgical or traumatic scars. It may also occur due to ectatic diseases of the cornea as keratoconus.

Rarely, the astigmatism may be due to lens factors as in subluxation of the crystalline lens or tilted IOL.

Types:

I. Regular: When the strongest meridian and the weakest meridian are perpendicular to each other and the meridians in between are regularly arranged.

▪ It may be:

a) Simple:

One meridian is emmetropic and the other is ametropic, i.e. simple myopic or simple hypermetropic astigmatism.

b) Compound:

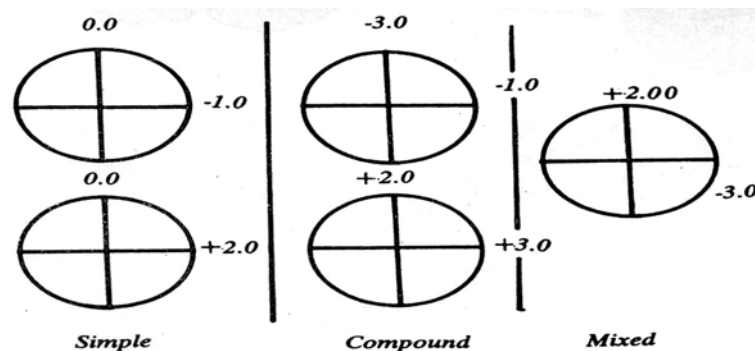
Both meridians are ametropic but of the same type, i.e. compound myopic or compound hypermetropic astigmatism.

c) Mixed:

One meridian is myopic and the other is hypermetropic.

II. Irregular: In which the meridians of maximal and minimal powers are not at right angle to each other and the changes from highest to lowest powers is not gradual or regular.

- It occurs in keratoconus and corneal scars.
- It can't be corrected by ordinary glasses.



Astigmatism

Symptoms:

1. Blurring of vision.
2. Accommodative asthenopia.

Signs:

1. The patient reads some types on the visual acuity charts and cannot read other types on the same line.
2. Special tools as Placido Disc, retinoscopy, automated refractometer, keratometer, and corneal topography.

Correction of Astigmatism:

Regular:

1. Glasses using cylindrical lenses that have the maximum refractive power perpendicular to its axis and no refractive power along its axis.
2. Toric contact lens (Special type of soft contact lens).
3. Refractive surgery.

Irregular:

1. Rigid or hard contact lens to convert the irregular anterior surface into a regular one.
2. Penetrating keratoplasty.

Ophthalmic Lenses

1- Cylindrical lens:

Is a piece of glass cut from a cylinder in a plane parallel to its axis. The cylindrical lens may be concave or convex (minus or plus cylinder). The axis of the cylindrical lens is parallel to the axis of the cylinder from which the lens has been cut.

Rays of light passing in a plane parallel to the axis of the cylinder undergo no refraction. Rays passing in a plane at right angle to the axis undergo refraction. Accordingly the cylindrical lens exerts its effect in a direction at right angle to its axis and has no effect in the direction of its axis.

- Cylindrical lenses are used for the treatment of regular astigmatism.

2- Spherical lens:

Is a piece of glass bounded by two surfaces each is a portion of a sphere. Spherical lenses may be convex (plus lenses) or concave (minus lenses).

- Spherical lenses are used in the treatment of spherical errors of refraction.

Concave lenses for myopia and convex for hypermetropia. They are also used in the treatment of presbyopia. The unit of lens power is the dioptre.

The dioptre:

It is the unit of lens power. It is defined as the power of a lens which brings parallel rays falling on it to a focus at a distance of one meter. It is the power of a lens whose focal distance is one meter. If the lens is concave its power is expressed as minus and vice versa.

The eye is a complex system of lenses. Its dioptric power is about 60 D. The power of the cornea is 42 D. and of the lens 18 D.

Anisometropia

Definition:

Anisometropia is a significant difference in refraction between the two eyes.

Symptoms:

1. Asthenopia.
2. Difficult binocularity (Diplopia).
3. Squint: Divergent or convergent, according to the age.

Correction of anisometropia:

1. Glasses can be used after undercorrecting the eye with a higher error at the expense of good vision.
2. Contact lenses reduce the difference in retinal image to about 6%.
3. Refractive surgery makes the difference negligible.

Asthenopia

Definition:

Asthenopia or eyestrain is a group of symptoms noticed with visual tasks chiefly after close work, especially in the evening by artificial illumination.

Symptoms:

1. Eye ache and burning.
2. Dry sensation leading to frequent blinking.
3. Lacrimation.
4. Hyperemia of the conjunctiva and lid margin.
5. Headache, usually frontal.

Causes:

A. Accommodative asthenopia:

1. Hypermetropia.
2. Astigmatism.
3. Presbyopia.
4. Anisometropia.

B. Muscular asthenopia:

Due to disproportion between convergence and accommodation as in heterophoria (latent squint).

Aphakia and Pseudophakia

See chapter 9: lens

Presbyopia

Definition:

Presbyopia is recession of the near point, due to progressive weakness of accommodation with aging (after the age of 40) making near vision uncomfortable.

Mechanism:

The crystalline lens becomes hard with age and loses its ability to change its dioptric power associated with ciliary muscle weakness.

Symptoms:

1. Difficult near vision usually occurs around the age of 40 in a previously emmetropic eye. A previously hypermetropic patient may need a

presbyopic correction at an earlier age. A previously myopic patient may need a presbyopic correction at an older age.

2. Accommodative asthenopia.

Correction of presbyopia:

1. Glasses:

Plus lenses (added to the far correction) are used to compensate for the lost automatic focusing power of the crystalline lens.

2. Multifocal Contact Lenses:

Have been tried with limited success.

3. Multifocal Intra Ocular Lenses:

May be used during cataract extraction.

Contact Lenses

Indications:

- 1. Optical:** To correct an error of refraction that can hardly be corrected by glasses as in aphakia, high myopia, high hypermetropia, anisometropia, and astigmatism. This is particularly true in unilateral aphakia.
- 2. Therapeutic:** To treat a corneal disease as recurrent erosions, exposure keratopathy, and small corneal perforations or wound leaks.
- 3. Cosmetic:** To improve an individual appearance e.g. to replace glasses and in a disfiguring eye which can be covered by a tinted contact lens with an artificial iris pattern.

Advantages:

1. The size of the retinal image is near to normal.
2. The field of vision is larger than spectacles as it moves with the eye and not restricted with a frame.
3. No spherical or chromatic aberrations.

Disadvantages:

1. Special care is required for its cleanliness and storage.
2. Some people do not tolerate them and others develop allergy to contact lens solutions.
3. Traumatic corneal abrasions may occur during manipulation.
4. Infection is always a risk with bad hygiene.

Types:

1. **Soft:** Made of various hydrogel plastics.
2. **Hard:** Made of polymethyl-methacrylate.
3. **Rigid gas permeable:** Made of various silicone and plastic polymers.

Refractive Surgery

Definition:

Refractive surgery is the modification of refraction of the eye by surgical interference.

Indications:

It is only indicated when glasses and contact lenses cannot be used due to:

1. **Optical reasons** as anisometropia with intolerance to contact lenses.
2. **Mechanical reasons** as nose and orbit configuration difficult to fit spectacles with intolerable contact lenses.
3. **Cosmetic and occupational reasons** as people working in the media and sport fields and contact lens intolerance.

Classification:

A. Corneal surgery as:

1. Radial Keratotomy:

Where radial incisions were done to weaken the cornea and make it flatter by the effect of IOP to correct low myopia. of $< -4.00D$.

2. Astigmatic keratotomy:

Where corneal incisions are done to flatten the steep meridian.

3. Excimer laser ablation of the anterior corneal surface either by PRK (Photorefractive Keratectomy) or LASIK (Laser in Situ Keratomileusis) can correct low and moderate myopia, astigmatism, and low hyperopia.

- **In PRK**, the laser ablation is done on the surface of the cornea after removing the overlying epithelium.
- **In LASIK**, a corneal flap is made using a special microkeratome .The excimer laser is directed to the center of the cornea, ablating (removing) part of the corneal thickness in a calculated manner. The flap is returned again.

B. Intra-ocular surgery as:

- Clear lens extraction with implantation of an IOL with the desired power in high errors in people near or after the age of presbyopia.
- Phakic IOL implantation either in the anterior chamber or the posterior chamber. Used mainly for high errors in people below the age of presbyopia.

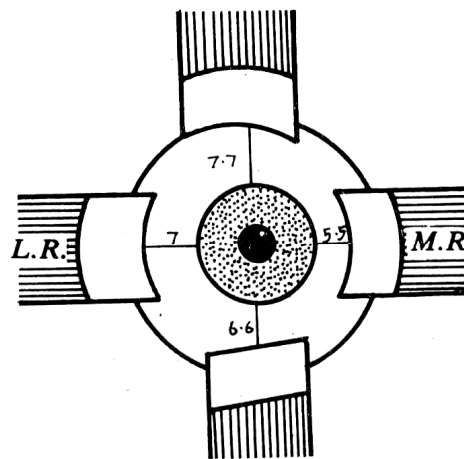
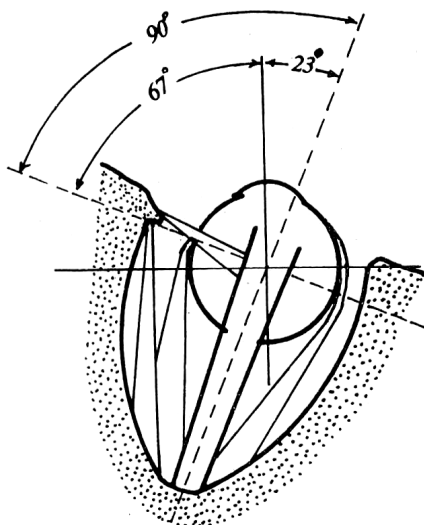
Chapter 14

Strabismus

Introduction and Definitions:

- Each eye moves around 3 axes (vertical, horizontal, anteroposterior) by six muscles (4 recti and 2 obliques).
- When the two eyes are directed straight ahead, this is called (primary position) and in this position no muscle is contracting.
- Optic axis: A line joining the center of the cornea, nodal point and center of the retina.
- Visual axis: A line between the macula, nodal point and the object of regard.
- Muscle axis: A line between the origin and the insertion of the muscle.
- Orthophoria: Is perfect equilibrium of oculomotor apparatus.
- Squint: Is the condition in which the visual axes of both eyes are not directed to the same object of regard. They are neither straight nor parallel in the primary position.

Anatomy of Extraocular Muscles



The extraocular muscles

Extraocular muscles:

- Four recti: Superior, inferior, medial and lateral rectus
- Two obliques: Superior and inferior oblique

Origin:

- Four recti and superior oblique: arise from a common tendinous ring (Annulus of Zinn) which is a fibrous ring around the optic foramen.
- Inferior oblique: Arises from the floor of the orbit lateral the opening of the nasolacrimal duct.

Insertion:

1. Four recti: Pass forwards to be inserted in the sclera in front of the equator at variable distances from the limbus.
2. Superior oblique: Passes forwards and medially to reach the trochlea at the upper medial part of the orbit and then bends backwards, downwards and laterally to be inserted in the upper posterolateral part of the eye.
3. Inferior oblique: Passes backwards and laterally below the globe to be inserted in the lower posterolateral part of the eye, 5 mm from optic nerve almost over the macula.

Action:

1. Medial rectus: Adduction.
2. Lateral rectus: Abduction.
3. Superior rectus:
 - Elevation (primary action).
 - Adduction and intorsion (subsidiary actions).
4. Inferior rectus:
 - Depression (primary action).
 - Adduction and extorsion (subsidiary actions).

5. Superior oblique:

- Intorsion (primary action).
- Depression and abduction (subsidiary actions).

6. Inferior oblique:

- Extorsion (primary action).
- Elevation and abduction (subsidiary action).

N.B:

- The superior rectus is the only elevator in abduction.
- The inferior oblique is the only elevator in adduction.
- The inferior rectus is the only depressor in abduction.
- The superior oblique is the only depressor in adduction.
- Recti muscles are adductors.
- Oblique muscles are abductors.
- Superior muscles are intortors (SR, SO).
- Inferior muscles are extortors (IR, IO).

Nerve Supply:

- Oculomotor (3rd) cranial nerve supplies medial, superior, inferior rectus and inferior oblique.
- Trochlear (4th) cranial nerve supplies superior oblique.
- Abducent (6th) cranial nerve supplies lateral rectus.

Blood Supply:

- Muscular branches of ophthalmic artery.

Cardinal positions of gaze:

Examination of ocular movements is carried out in six directions (cardinal positions). One muscle in each eye is the primary mover in any of these directions. Each eye is examined individually and then both eyes are examined together.

Eye movements:

A. Ductions:

- These are monocular eye movements: Adduction, abduction, elevation, depression intorsion and extorsion.
- Agonist: The primary muscle which moves the eye in a given direction.
- Antagonist: The muscle that acts in the opposite direction.
- Sherrington's law (governs monocular eye movements): Increased innervation of a muscle is automatically associated with reciprocal decreased innervation of its antagonist.

B. Versions:

- These are binocular eye movements in which the two eyes move synchronously and symmetrically in the same direction.
- Yoke muscles: When the two eyes move in a certain direction, a muscle of one eye is paired with a muscle of the other eye called the yoke muscle.
- Hering's law (governs binocular eye movements): Equal and simultaneous innervations flows to yoke muscles to move both eyes in a certain direction.

C. Vergence:

- These are binocular eye movements in which two eyes move synchronously and symmetrically in opposite directions: Convergence (both eyes move inwards to look at a near object) and divergence (both eyes move outwards to look at a far object).

The General Order of Examination for Strabismus:

1. History:

- a. Deviation: Age of onset, description of deviation, duration, previous treatment.
- b. Personal and family history: Strabismus in blood relatives.

2. General observation: Abnormal head posture.

3. Visual acuity.

4. Ocular motility (ocular movements):

- a. Ductions (movements of each eye, with other eye covered).
- b. Versions (movements of both eyes together).

5. Measurement of angle of deviation:

- Corneal light reflex test (see concomitant squint).
- Cover tests (phoria or tropia) with prisms.

6. Tests of binocular functions.

7. External examination.

8. Anterior segment examination.

9. Fundus examination.

10. Cycloplegic refraction.

Binocular Single Vision

Definition:

It is the ability of the brain to see one fused image of one object by using the two eyes.

Prerequisites:

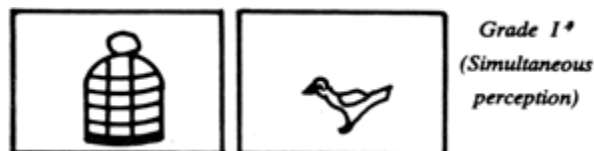For fusion to occur there are three pre-requisites:

1. The two images on both retinae should be identical or nearly identical as regard size, shape, clarity, brightness, etc. This implies that, good vision in both eyes should be present i.e. no marked anisometropia.
2. The two identical images should fall on normal retinal correspondence. This fine adjustment requires good extraocular muscle function.
3. Normal fusion centre should be present; no ischemia, no thrombosis, no under development... etc.

Grades of binocular single vision:

Grade I (Simultaneous perception):

It is the ability to see two objects at one time e.g. a bird and a cage. The right eye sees the image of a bird, while the left eye is fronted by the image of a cage. The two eyes can see a single image of the bird in its cage.



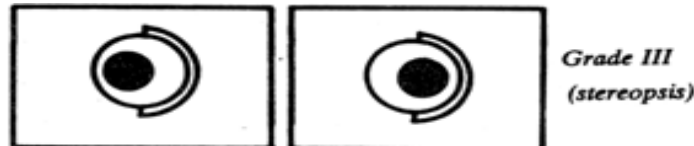Grade II (Fusion):

It is the ability to fuse similar objects with control e.g. rabbit with a tail and another without but with ears, the fused image is one rabbit with a tail and ears.



Grade III (Stereopsis):

It is the ability to perceive depth when each eye is presented with slightly dissimilar image of the same object.



Double vision

Manifest squint will cause double vision. There are two components of double vision:

1. Confusion:

In a case of squint, the two visual axes will be misaligned so that they will not intersect at the point of fixation, the object of fixation; (e.g. a rounded circle) stimulates the fovea of the fixing eye; while the fovea of the deviated eye will be stimulated by another nearby object (e.g. a triangle). As the two foveae are normal corresponding points; the image of the triangle will be superimposed on the image of the circle resulting in confusion.

2. Diplopia:

At the same time, the single rounded object will stimulate a non corresponding retinal point, in the deviated eye. It stimulates the fovea of the fixing eye and a clear image is projected into a straight head position. In the deviated eye it stimulates a point that is nasal or temporal to the fovea and will therefore be projected into the temporal or nasal field resulting in binocular diplopia. The clear image is seen by the fixing eye and at the same time a faint false image is seen by the deviated eye.

- Diplopia: Is to see two images of one object.
- Confusion: Is to see 2 different images of different objects superimposed on each other.

Double vision is incompatible with life so many adaptive phenomena occur to overcome such unusual condition even on expense of the visual acuity of the deviated eye.

Adaptive phenomena arising to overcome double vision:

As double vision is intolerable, every effort from the sensory system as well as the motor system is made so as to overcome such problem.

The compensatory mechanisms which develop to overcome diplopia & confusion depend upon:

- Age of onset of the squint.
- Angle of the squint.
- State of binocular function.

Any of the following adaptive phenomena may arise:-

I- Motor Adaptation:

1- Latent squint:

When the angle is small, and binocular function is good, corrective straightening of the eye occurs by re-adjustment of the extraocular muscle tone. So that manifest squint becomes latent when both eyes are used together. If binocular vision is dissociated (by occlusion of one eye) the covered eye becomes squinting again.

2- Purposive squint (Blind spot syndrome):

When the angle of deviation is not small enough to be overcome by fine adjustment of extraocular muscle tone, alteration of E.O.M. tone occurs in

an attempt to throw the unwanted image on the optic disc (Blind spot). So, overcomes double vision.

3- Compensatory head posture:

This occurs in patient with paralytic squint in which the binocular function is fully developed, angle is fairly large. The patient experiences diplopia when looking to the direction of action of paralyzed muscle. So the patient avoids looking to that direction by turning the direction of the head toward the direction of action of the paralyzed muscle (direction of diplopia).

Components of Abnormal head posture:

According to the paralyzed muscle, 3 components of abnormal head posture may develop.

- 1- Face turn in a case of horizontal recti paralysis.
- 2- Chin elevation or depression in a case of vertical recti paralysis.
- 3- Head tilt in a case of oblique muscle paralysis.

II- Sensory adaptation:

1-Suppression:

A type of adaptation that occurs mainly in children is the development of suppression which is produced subconsciously by an active inhibition of vision in the squinting eye by visual cortex.

Suppression is a temporary phenomenon occurring only when both eyes are open, if the fixing eye is covered, the suppression stops immediately and the squinting eye takes up fixation. In unilateral squint, suppression is always to the squinting eye leading to development of a type of amblyopia (Strabismic amblyopia) in which the vision of the squinting eye is markedly reduced without any organic lesion while in alternating squint, suppression is also alternating so amblyopia does not develop in this type of squint.

2- Abnormal retinal correspondence (ARC):

ARC is a form of binocular co-operation in which the visual cortex adapts itself to ocular deviation by establishing new series of retinal correspondences in the squinting eye which only come to play when the two eyes are functioning together. The fovea of the normal eye and an extrafoveal point (which is normally non corresponding) of the squinting eye will develop a common visual direction. In other words it can be said that, ARC is a form of adaptation in which there is corrective straightening of the images by psychological adjustment without corrective straightening of ocular deviation by muscular effort as in latent squint.

3- Eccentric fixation:

In ARC the extrafoveal point of the squinting eye corresponds the fovea of non squinting eye when the two eyes are used together but if the normal eye is covered, the squinting eye regains fixation by its normal fovea; but in eccentric fixation, the extrafoveal point in squinting eye is maintained to be the fixation point even when the normal eye is covered so eccentric fixation is a permanent type of ARC.

Strabismus Classification

- Apparent strabismus (Pseudostrabismus).
- Latent strabismus (Heterophoria).
- Manifest strabismus (Heterotropia):
 - Paralytic.
 - Concomitant.

I. Pseudo-strabismus = Apparent = False squint

It is a condition in which a false impression of ocular deviation is present but on examination eyes are orthophoric with normal binocular single vision.

Etiology:

1. Apparent convergent squint:

- Epicanthus: Prominent epicanthal folds hiding part of the normally visible sclera giving a false impression of convergent squint.
- Small interpupillary distance.

2. Apparent divergent squint:

- Large interpupillary distance.

Diagnosis:

- Corneal light reflex test: Normally centered.
- Cover test: No movement occurs.

II. Latent Strabismus (Heterophoria)

It is tendency of the eye to deviate from orthophoric position (straight head) but this tendency is checked subconsciously by the brain to maintain binocular single vision. When the patient is fatigued and the brain loses interest in binocular single vision, latent squint becomes manifest. Also, disrupting fusion by covering one eye causes deviation of the covered eye.

Etiology:

1. Uncorrected errors of refraction:

- **Hypermetropia:** The patient uses excessive accommodation to see clearly.

As a result, excessive convergence occurs with accommodation which causes latent convergent squint.

- **Myopia:** The patient relaxes his accommodation which results in lack of convergence and the occurrence of latent divergent squint.

2. Congenital weakness of one or more of extraocular muscles.

Types:

Esophoria, exophoria, hyperphoria, hypophoria.

Clinical picture:

Symptoms:

Latent squint is present in a large percentage of the population. Patients may present with:

- **Muscular asthenopia:** Eye strain, headache and lacrimation.
- **Occasional diplopia:** Running letters during reading.
- Patient or his parents may complain that the child's eye deviates when tired or not concentrating.

Diagnosis: Depends on abolishing fusion by covering one eye or providing each eye by a different image.

(1) **Cover test:** The patient is asked to fix the finger with both eyes, the eyes appear normal. One eye is then covered by a piece of paper. The covered eye is observed. If heterophoria is present the covered eye will be seen to squint. Remove the cover, the squinting eye will correct its position

and binocular fixation is resumed. If no movement occurs, the patient has a correct muscle balance (Orthophoria).

(2) Maddox rod test: The patient sits at a distance of 6 meters from a spot light. In one side of the trial frame maddox rod is placed and the rods are placed horizontally. The patient will see the light by one eye and a vertical red line by the other eye. If the patient sees the light coinciding with the centre of the line, he has no horizontal phoria. If the light falls to one side of the line, he has eso or exophoria.

The rod is now rotated to make the rods vertical. The red line will appear horizontal and the patient will tell if the light is on the line or not. If the light falls above or below the line the patient has hypophoria or hyperphoria. The angle of deviation can be measured by finding the prism which makes light coincide with the line.

(3) Maddox Wing is used to diagnose heterophoria for near. The patient reads directly the angle of his latent squint.

Treatment:

- Compensated cases with no symptoms require no treatment.
- Correction of error of refraction.
- Surgery: Indicated when symptoms are not relieved by glasses (very rarely).

III. Manifest Strabismus (Heterotropia)

A. Paralytic Strabismus

Definition: Deviation of the eye due to paralysis of one or more of the extraocular muscles.

Etiology: Lower motor neuron lesion (LMNL).

N.B: Upper motor neuron lesions (UMNL) don't produce paralysis of individual muscle but paralysis of the conjugate movements and the patient can't look to the right or left etc...

1. Nuclear lesions:

- Congenital: Absence of the nucleus.
- Inflammatory: Encephalitis.
- Vascular: Hemorrhage, thrombosis or embolism.
- Neoplastic: Brain tumors.

2. Nerve lesions:

- Traumatic: Fracture base of the skull.
- Inflammatory: Neuritis e.g. diabetes and diphtheria (toxic neuritis).
- Vascular: Subarachnoid hemorrhage and cavernous sinus thrombosis.
- Neoplastic: Brain tumors (due to increased intracranial pressure).

3. Muscle lesions:

- Congenital: Maldevelopment of the muscle.
- Traumatic: Fracture orbital bones.
- Neuro-muscular: Myopathy and myasthenia gravis.
- Neoplastic: Orbital tumors.

Diagnosis:

1. Ocular deviation: The paralyzed muscle loses its tone, the antagonist draws the eye towards it, i.e. the eye deviates to the opposite direction of the paralyzed muscle.

2. Limitation of movement of the eye in direction of action of the paralyzed muscle diagnosed by motility test.

3. Angle of deviation: Changes in different directions of gaze and also changes depending on which eye is fixing:

- Primary angle of deviation: Angle of squint when the patient is fixing with the normal eye.

- Secondary angle of deviation: The angle of squint when the patient is trying to fix with the squinting eye (normal eye is covered). It is larger than the angle of primary deviation due to excessive impulses sent by the brain to the paralyzed muscle to contract. The same excessive impulses also reach the normal yoke muscle in the other eye producing a larger deviation.

4. Binocular diplopia: It is maximum when the patient looks at an object situated in the direction of action of the paralyzed muscle and decreases in the opposite direction. Binocular diplopia disappears when one eye is covered. The false image is the one seen by the squinting eye; it is blurred because it falls outside the macula.

5. False projection: Wrong estimation of the sites of objects.

6. Compensatory head posture: Abnormal head position adopted to avoid diplopia. The head is turned in direction of action of paralyzed muscle.

Abducent or sixth nerve palsy (lateral rectus palsy):

If the right lateral rectus is affected, the clinical picture will be:

1. Convergent squint in the right eye.
2. Limitation of movement when the patient moves his eye to the right.
3. The angle of squint is large when the patient looks to the right side.
4. The angle of squint is large when the right eye is fixing.
5. Diplopia most marked when the patient looks to the right.
6. Face turn to the right.

Oculomotor or third nerve palsy:

1. Ptosis.
2. Deviation of the eye down (superior oblique) and out (lateral rectus).
3. Limitation of movement in the direction of action of the involved muscles.
4. No diplopia (ptosis).
5. Dilatation of the pupil, paralysis of accommodation.

Trochlear or fourth nerve palsy:

If the right superior oblique is affected, the clinical picture will be:

1. Squint: The eye is deviated upwards and slightly inwards with extorsion.
2. Limited depression in adduction (much discomfort on going downstairs).
3. Uncrossed binocular diplopia on looking down and in.
4. Abnormal head posture: Chin depression with face turn to left and head tilt towards left shoulder.

Combination of muscle palsy:

Ophthalmoplegia = Ocular muscle palsy.

External ophthalmoplegia = Paralysis of extraocular muscles.

Total ophthalmoplegia = Paralysis of extraocular and intraocular muscles.

Superior orbital fissure syndrome = Paralysis of 3, 4, 6 + ophthalmic nerve (pain and anesthesia).

Orbital apex syndrome = Paralysis of 3, 4, 6 + ophthalmic + optic nerve (optic atrophy).

Treatment of paralytic strabismus:

- Treatment of the cause.
- Surgery: Wait for 6 months before surgery for spontaneous nerve regeneration then reassess ocular motility:
 - a) If the eye moves to mid-line, only paresis of the muscle is present; therefore, strengthen the weak paretic muscle by resection and weaken the direct antagonist by recession.
 - b) If the eye does not move to mid-line, complete palsy is present and transposition of healthy non-paralyzed muscles is needed.

B. Concomitant Strabismus

It is manifest squint in which the visual axes of the 2 eyes are not directed to the same object and they maintain their abnormal relation in all directions of gaze.

Etiology: Obstacles that interfere with the development of binocular single vision.

1. Refractive causes (uncorrected errors of refraction):

- In hypermetropia (more than 3.00D), the child accommodates to see clearly. Accommodation is associated with convergence and esotropia occurs (accommodative esotropia).
- In myopia, relaxation of accommodation and lack of convergence (weak M.R. ms) results in concomitant divergent squint.

2. Non-refractive causes:

- Congenital: Esotropia much more common than exotropia.
- Sensory: Secondary to monocular impaired vision. If visual acuity in one eye is weak the brain will suppress it and unilateral squint will result.

Sequelae of concomitant squint:

1. Suppression: The brain neglects the image of the squinting eye.
2. Amblyopia: Visual acuity in the suppressed eye starts to deteriorate permanently.
3. Eccentric fixation: Occurs in some cases of amblyopia when the patient uses a parafoveal area for fixation (pseudo macula).

Infantile Congenital Esotropia:

Presentation: Within the first 6 months of life.

Examination reveals:

- i. Angle of deviation is usually large.
- ii. Fixation is usually alternating.
- iii. Refractive error is normal for the age of the child (not excessively hypermetropic).

Management:

- i. Refractive errors and amblyopia treated first.
- ii. Eyes are aligned surgically, usually at the age of twelve months.

Refractive (Accommodative) Esotropia:

It is associated with activation of the accommodative reflex in response to excessive hypermetropia.

Presentation: Usually at age 2-3 yrs.

Examination:

1. Visual acuity: To determine if one eye sees worse.
2. Corneal reflex test: To confirm presence of manifest deviation and determine the angle of squint.
 - Light is shone into the eye and the corneal light reflex is noted.
 - It should be symmetrical and centered in the pupils, if the light is not centered, squint is present.
3. Cover test:
 - Ask the patient to fix an object (first at a distance then at near).
 - Cover the normal eye; the patient will move the squinting eye to fix the object and the normal eye will deviate under the cover.

- Remove the cover:
 - i. In unilateral squint the previously deviating eye will deviate again.
 - ii. In alternating squint the patient remains fixing with the previously squinting eye.
 - iii. Unilateral squint: Squinting eye is amblyopic.
 - iv. Alternating squint: Equal vision in both eyes.
- 4. Fundus examination and refraction with a cycloplegic drug: e.g. Cyclopentolate 1%.
- 5. State of Binocular vision:
 - i. Grade I Simultaneous perception.
 - ii. Grade II Fusion.
 - iii. Grade III Depth perception.

Management of accommodative esotropia:

Treatment should be carried out as early as possible to avoid amblyopia.

1. Glasses: Correction of error of refraction giving full cycloplegic refraction to relax accommodation.
2. Amblyopia therapy: Amblyopia is diagnosed if unilateral squint is present. Covering the sound eye to improve the vision of the amblyopic eye is carried out.
3. Surgery: If glasses do not fully correct the deviation within one month.

Types of surgery:

1. Weakening procedures = recession.
2. Strengthening procedures = resection.

Clinical evaluation of a case of concomitant squint

History:

1. Age of onset: In general, the earlier the onset, the more likely is the need for surgical correction. The later the onset the greater the likelihood that the deviation has an accommodative element.
2. Family history: Strabismus is frequently hereditary.
3. Variability: If the deviation is worse when the child is tired or ill, an accommodative element is likely to be present.
4. Intermittent or constant: In intermittent cases it is likely that some form of binocular single vision is still present and the prognosis is better than in constant cases.
5. Diplopia: The presence of diplopia in older children might suggest a parietic component due to neurological disease.

After careful history taking you have to answer the following questions:

A- Is the squint unilateral or alternating?

- Unilateral squint means that one eye is always squinting all the time, and the other eye is always fixing, so amblyopia occurs in the squinting eye.
- Alternating squint means that each eye can maintain fixation; so, no amblyopia occurs.

To differentiate between the two types, the following are tested:-

1- Visual acuity:

- In unilateral cases: The squinting eye shows marked diminution of vision than the normal eye because of amblyopia.

- In alternating cases: Usually vision is equal or nearly equal in both eyes as there is no amblyopia.

2- Cover test:

In manifest squint, cover one eye and ask the patient to look to your finger or a pencil torch to allow the uncovered eye to take fixation and then remove the cover and notice the uncovered eye (fixing) when you remove the cover.

- If the uncovered (fixing now) can maintain fixation when the other eye is uncovered so, the patient can fixate with this eye.
 - Repeat the test on the other eye:
- If the patient can maintain fixation with either eye → it is alternating.
 - If the patient can maintain fixation with one eye only → it is unilateral.

B- Is it concomitant or paralytic?

This is achieved by:

1- Testing the ocular motility:

Examine each eye separately for movement in the six cardinal directions of gaze namely:

Up and out	→ to examine S.R.
Up and in	→ to examine I.O.
Down and out	→ to examine I.R.
Down and in	→ to examine S.O.
Abduction	→ to examine L.R.
Adduction	→ to examine M.R.

- Notice any limitation of movement in any direction. If there any limitation, the responsible muscle is identified.
- Then examine the movements of the two eyes simultaneously, also in the six cardinal directions of gaze to detect any paresis in conjugate eye movements.

2- Angle of the squint:

- In concomitant squint, the angle of deviation is the same irrespective which eye is fixing.
- In paralytic squint, the secondary angle of deviation (when the paralyzed eye is fixing) is much larger than the primary angle of deviation (When the normal eye is fixing) (see before).

C- Is it convergent or divergent?

By asking the patient to fixate the light of a pencil torch and notice the corneal reflection of the light. Normally, it is at the centre of the pupil. In case of convergent squint, the image of the light deviates temporally, and in case of divergent squint, it deviates nasally.

In a case of convergent squint, you should know whether it is accommodative or non accommodative type. This is achieved by examining the refraction of the eye. If there is hypermetropia, more than the age, it is accommodative, if not, it is non accommodative.

D- Is it primary or secondary?

Secondary squint should be excluded by careful examination of the eye both anterior and posterior segments.

Causes of secondary squint:

- 1) Unilateral corneal opacity.
- 2) Unilateral lens opacity.

- 3) Unilateral retinal detachment.
- 4) Unilateral intraocular tumor.

N.B:

- Twenty percent of cases of retinoblastoma present for the first time with squint.
- If no organic cause is detected it is called primary squint.
- Secondary squint is always divergent (resting position of the eye) except if its cause started during early childhood. In this case it will be convergent.

E- What is the angle of the squint?

The angle of the squint is the angle between the two visual axes. It is measured by:

Corneal reflection method:

The patient is asked to look at a light source at a distance of 50 cm. The position of the corneal reflex in the squinting eye indicates the angle as follows:

- If it is at the centre of the pupil → 0 degree (No squint).
- At the edge of a normal sized pupil → 10-15 degree.
- Midway between the edge of the pupil and the limbus → 20-25 degree.
- At the limbus → 40-50 degree.
- Outside the limbus → more than 45 degree.

F- The condition of binocular vision:

The state of binocular function should be studied before treatment of squint. A rough idea can be taken by the use of Worth's four dots test but the Synoptophore enables us to detect the actual grade of binocular vision.

Worth's 4 dots test:

Four colored illuminated dots are viewed by the patient at a distance of six meters. The dots are one red, one white and two green. The patient wears red-green goggles. Red in front of the right eye and green in front of the left eye. So,

- The right eye will see two red dots (the red and the white as red).
- The left eye will see 3 green dots (the 2 green and the white as green).

Then the patient is asked about the number and color of the dots he sees binocularly.

Interpretation:

1. The normal subject will see 4 dots:
 - One red & two green.
 - One pink to green according to the dominant eye.
2. If the patient sees two red only, this means that the left eye (green) does not see i.e. left suppression.
3. If the patient sees 3 green only. This means that the right eye (red) does not see i.e. right suppression.
4. If the patient sees 5 dots; 2 red and 3 green i.e. he has diplopia (each eye sees separately).
5. If he sees 4 dots one red two green. One pink to green, in presence of manifest squint, this means that he has developed abnormal retinal correspondence (ARC).

Synoptophore:

This instrument consists of two tubes which can be moved separately. At one end of each tube, a slide can be put. The patient looks through the eye piece which contains +6.5 dioptre lens to abolish accommodation.

Uses of Synoptophore:

i- Diagnostic:

- Measures the angle of the squint.
- Determines the grade of binocular vision.
- Detects suppression.
- Measures the angle alpha.

ii - Therapeutic:

- Treatment of suppression.
- Improves the grades of binocular vision.

By answering these questions you can arrive to the proper diagnosis of the case of squint and in this way you can suit the proper lines of management as there is no one ideal line of treatment for all cases of squint but many options are available and you must suit from these options the most proper line for each case. In other words, the treatment of squint should be individualized.

Table (16): Types of squint

	Concomitant	Paralytic
Ocular motility	Free	Limited
Angle of squint	Constant	Variable
Diplopia	Absent	Present
Primary & secondary angles	Equal	Secondary angle greater
Headache & vomiting	Absent	Present
False projection	Absent	Present
Compensatory head posture	Absent	Present

Amblyopia

Amblyopia is impaired vision in the absence of organic disease. It is most likely the result of lack of continuous use of one or both foveas for vision.

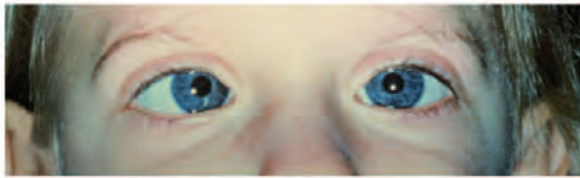Types:

- 1. Strabismic amblyopia:** In order to avoid diplopia, the brain will suppress the image of the squinting eye which over time will result in amblyopia.
- 2. Anisometropic amblyopia:** Is the result of a marked difference in refraction between the two eyes. The brain suppresses the blurred image of the eye having the higher error causing amblyopia.
- 3. Visual deprivation amblyopia (amblyopia ex anopsia):** Due to opacities in the ocular media as unilateral developmental cataract or ptosis covering the pupillary area.
- 4. Toxic amblyopia due to chronic retrobulbar neuritis.**
- 5. Nystagmic amblyopia.**

Treatment:

Treatment is based on forcing the patient to use the amblyopic eye for vision, after removing the cause.

Occlusion (patching) of the preferred eye is carried out. It is important to diagnose amblyopia as early as possible (before age 9); otherwise occlusion will not improve visual acuity.



Without spectacle correction

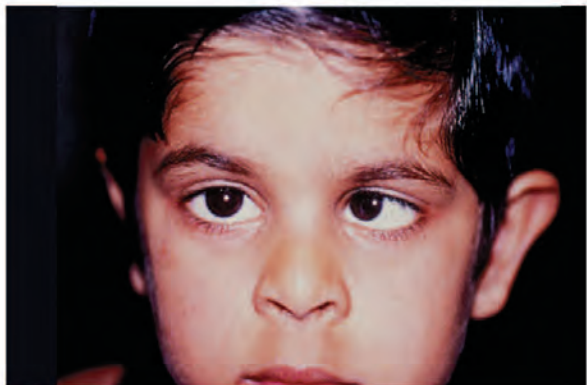

Fully corrected with spectacles

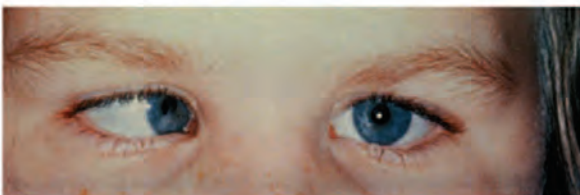Accommodative esotropia



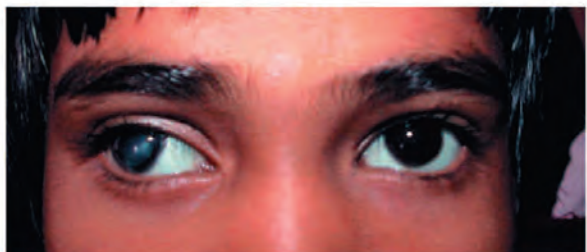False appearance of esotropia due to epicanthic folds



Left esotropia



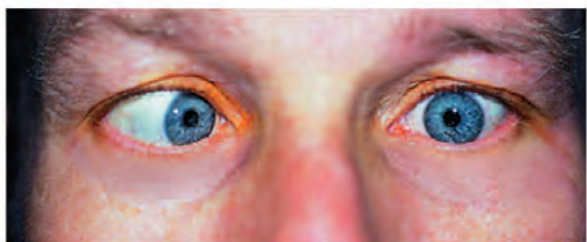
Right esotropia



Right secondary divergent squint due to cataract



Compensatory head posture in left superior oblique palsy



Marked limitation of left abduction due to weakness of the left lateral rectus

Chapter 15

Neuro-Ophthalmology

Anatomy of the visual pathway

a. First Neuron:

Visual pathway starts at the photoreceptors (rods & cones) in the retina. They synapse with the bipolar cells, then with the ganglion cells of the retina.

b. Second Neuron:

Axons of the ganglion cells form the optic nerve which carries fibers from the temporal and nasal halves of the retina to optic chiasma where nasal fibers decussate to the contralateral optic tract whereas the temporal fibers pass in the ipsilateral optic tract to end by synapsing in lateral geniculate body (LGB).

c. Third Neuron:

Fibers from LGB pass through the optic radiation to synapse in calcarine area of the occipital cortex (visual cortex).

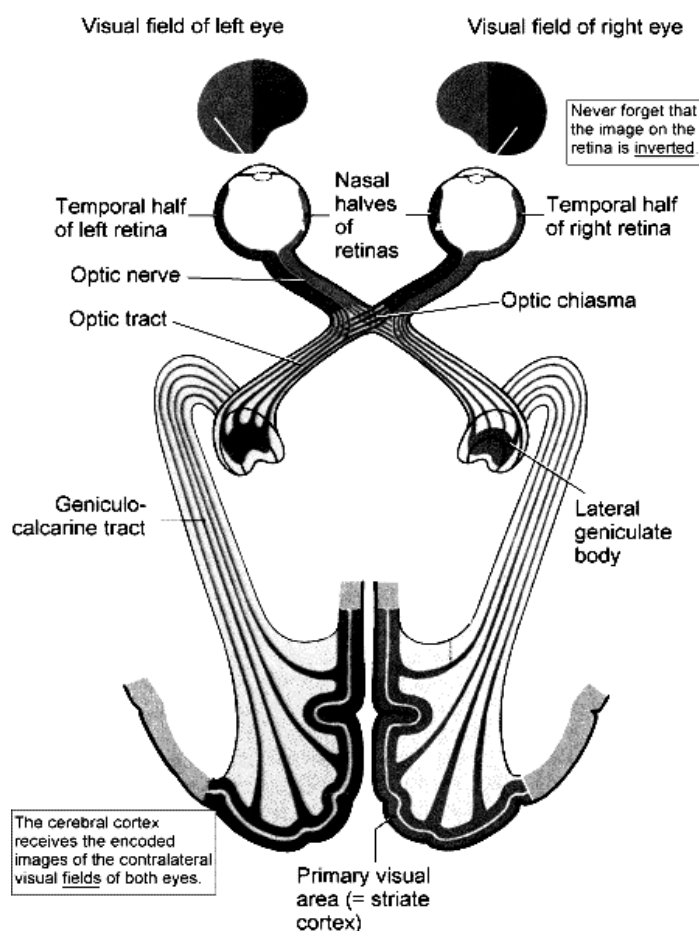
Visual cortex includes:

- Primary visual area (area 17): Striate cortex.
- Visual association area (area 18): Peristriate cortex.
- Parastriate cortex (area 19).

The optic nerve is the 2nd cranial nerve which is responsible for vision.

It consists of:

- Axons of the ganglion cells of the retina which converge into the nerve fiber layer of the retina which pass through the lamina cribrosa of the sclera forming the optic nerve which becomes myelinated and covered with meninges.
- On leaving the globe, the optic nerve runs backwards in the orbital cavity (25mm).
- Then passing through optic canal (8mm) to the cranial cavity (25mm) where it joins the opposite nerve to form the optic chiasma.



Anatomy of the visual pathway

Diseases of the optic nerve

A) Optic Neuritis

Means inflammation of the optic nerve.

Optic neuritis is divided into two main categories:

1. Papillitis: Inflammation of the optic nerve head.
2. Retrobulbar optic neuritis: Inflammation of the optic nerve behind the eyeball and it is divided into:
 - a. Acute retrobulbar neuritis.
 - b. Chronic (toxic) retrobulbar neuritis.

Causes of optic neuritis

1. Demyelinating diseases (D.S).
2. Local inflammatory causes: Uveitis, orbital inflammation, sinusitis, meningitis.
3. General inflammatory causes: Neuromyelitis Optica, Herpes-zoster (HZ), Neuro-Syphilis.
4. Metabolic disorders and malnutrition: Diabetes mellitus, vit. B deficiency, Anemia.
5. Intoxication by: Lead, arsenic or ergot.

1. Papillitis

Symptoms:

1. Rapid loss of central vision.
2. Central scotoma.

Signs:

- 1) Sluggish unsustained pupillary reaction to direct light with normal reaction to consensual light (Marcus-Gunn pupil).

- 2) Ophthalmoscopy:
 - a. Disc is hyperemic with blurring of the margin.
 - b. Later, disc is edematous with hemorrhage and exudates at the edge.
 - c. Retinal blood vessels: Narrow arteries and congested veins.
 - d. Vitreous cells in front of the optic disc.
 - e. In severe cases, post neuritic secondary optic atrophy may occur.
- 3) Visual field, central scotoma to colors (red & green).

2. Acute Retrobulbar Neuritis

Symptoms:

- 1) Rapid loss of central vision.
- 2) Pain: Dull aching exaggerated by ocular motility.
- 3) Central scotoma.

Signs:

- 1) Tenderness on pressing the globe back.
- 2) Unsustained pupillary contraction to direct but not to consensual light
(Relative Afferent Pupillary Defect - RAPD) (Marcus-Gunn pupil).
- 3) Ophthalmoscopy: No changes.
- 4) Later, optic disc pallor and secondary optic atrophy.
- 5) Visual field, central scotoma to colors (red/green).
- 6) Prognosis is good if the condition is treated early.

3. Chronic Retrobulbar Optic Neuritis (Toxic Amblyopia)

A number of conditions in which the optic nerve fibers are damaged by exogenous poisons.

Classification:

1. Toxins which produce central scotoma e.g. Tobacco, Ethyl alcohol.
2. Toxins which produce constriction of the peripheral field e.g. Quinine.
3. Toxins which produce severe optic atrophy e.g. Methyl alcohol.

Clinical picture:

1. Bilateral condition but, more in one eye.
2. Gradual diminution of vision, (misty).
3. Difficulty to do close works e.g. reading.
4. Difficulty to discriminate colors.
5. Visual field: Centrocecal scotoma more for red-green target.
6. Fundus is normal but later, temporal pallor of the optic disc appears.

Treatment:

1. Stop tobacco and alcohol.
2. Vitamin B1, B12.
3. Vasodilators.

Ischemic optic neuropathy

It is an ischemic papillitis resulting from infarction of anterior optic nerve fibers. It is due occlusion of the two posterior ciliary arteries.

Causes:

- a. Giant cell arteritis.
- b. Arteriolosclerosis.
- c. Emboli.

B) Papilledema

It is non-inflammatory passive edema of the optic disc. It is most often the result of increased intracranial pressure. Owing to the loose structure of the optic nerve head, there may be much swelling before nerve fibers are actually pressed on sufficiently to interfere with their conduction; so, there may be much swelling without visual loss.

Causes of swollen disc:

A. Increased intracranial pressure due to:

1. Neoplasm: Cerebral tumors.
2. Vascular: Subarachnoid hemorrhage.
3. Inflammatory: Meningitis.
4. Pseudotumour cerebri.

B. Systemic Disease:

1. Malignant hypertension.
2. Severe anemia.

C. Local disease of the eye and orbit (unilateral papilledema):

1. CRVO.
2. Uveitis.
3. Space occupying lesion of the orbit (orbital cellulitis).
4. Papilitis.
5. Hypotony (corneal fistula, choroidal detachment).

Clinical Picture:

Symptoms:

1. Headache, vomiting, diplopia in cases with increased intracranial pressure.
2. Transient blurring of vision.
3. Scotoma.

Signs:

Papilledema is usually bilateral. Unilateral papilledema means local orbital ocular disease.

l) Ophthalmoscopy:

• **Early stage:**

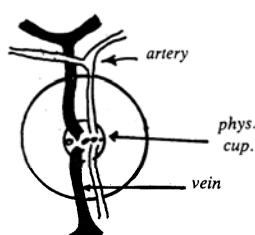
1. Engorgement & tortuosity of the veins.
2. Flame shaped hemorrhage at the disc margin.
3. Blurring of the disc margins.
4. Filling of the disc cup.
5. Swelling of the disc.

• **Late stage:**

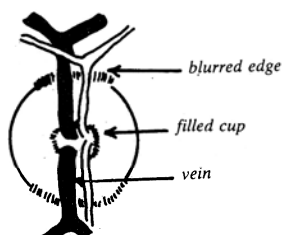
1. Elevation of optic disc up to 8-10 D (Champaigne Cork appearance or mushroom shaped).
2. Venous congestion increases.
3. Loss of normal venous pulsation.
4. White exudates appear at disc margin and retina.
5. Retinal edema (macular fan).

• **Very late stage:**

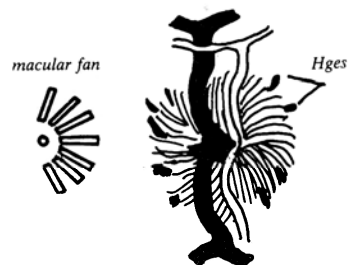
Post-papilledemic optic atrophy.



Normal Papilla



Early Papilledema



Advanced Papilledema

II) Visual field:

Early: Enlargement of the blind spot.

Late: Progressive contraction of the visual field and central scotoma to blue.

Other causes of swollen disc:

1. Papillitis.
2. Pseudo papilledema.

Table (17): Difference between papilledema & papillitis

	Papilledema	Papillitis
Symptoms of increased intra-cranial tension.	Present (headache& vomiting)	Absent
Vision	Normal	Markedly affected early
Bilaterality	Bilateral	Unilateral
Field	Enlarged blind spot	Central scotoma for red& green
Disc swelling	Up to 9 dioptrcs	Less than 3 dioptrcs
Vitreous	Normal	Dust like opacities
Pupils	Normal	RAPD
Course	Increases	Decreases

Pseudo-papilledema is caused by:

1. Bergmeister papillae.
2. Opaque nerve fibers.
3. High hypermetropia.
4. Drusen bodies of the disc.

Difference between papilledema & pseudo-papilledema:

- The swelling is not more 2 diopters.
- No venous engorgement.
- No exudates, hemorrhage or retinal edema.
- No enlargement of blind spot.

Treatment of papilledema:

Relief of the cause.

C) Optic Atrophy

Means degeneration of the axons of the ganglion cells.

Types of optic atrophy:

1. Primary optic atrophy.
2. Secondary optic atrophy.
3. Consecutive optic atrophy.
4. Glaucomatous optic atrophy.

1) Primary optic atrophy

It is caused by lesions primarily affecting the optic nerve behind the eyeball.

Ophthalmoscopic picture:

1. The whole disc is milky white, grayish-white, bluish-white in color.
2. The edges of the disc are sharply defined.
3. The lamina cribrosa is well seen.
4. There is shallow saucer shaped atrophic cup.
5. The retinal blood vessels are not altered.
6. The surrounding retina looks normal.

2) Secondary optic atrophy

It is the optic atrophy following papilledema or papillitis.

Ophthalmoscopic picture:

1. The disc is greyish white in color, the edges of the disc are ill-defined.
2. The lamina cribrosa is obscured.
3. The optic cup is filled with glial tissue.
4. The retinal veins are engorged and tortuous, while retinal arteries are constricted, both are sheathed.
5. Pigmentary changes at the edges of the disc.

3) Consecutive optic atrophy (yellow optic atrophy)

Optic atrophy due to chorio-retinal diseases.

Ophthalmoscopic picture:

1. Disc is waxy yellow in color.
2. Edges of the disc are ill defined.
3. Retinal blood vessels are markedly attenuated.
4. Retina shows the evidence of the causative disease.

4) Glaucomatous optic atrophy

Optic atrophy following none treated glaucoma.

Ophthalmoscopic picture:

1. The optic disc is pale white due to the atrophy of its fibers.
2. Optic cup is enlarged (increased C/D ratio).
3. Vessels are displaced nasally, and appear as broken off at the edge of the cup.
4. Retinal arteries show pulsation.

Table (18): Types of optic atrophy

Primary	Secondary	Consecutive		Glaucomatous
Cause; TD,DS,TR	Papillitis papilloedema	CRA occlusion	Retinitis nigmentosa	GL
Optic disc margin well defined	Ill defined Irregular	Well defined	Slightly ill defined	Overhang edges
Color Milky white	Pale Grey	White	Waxy yellow	Pale white
LAMINA well seen	Obscured	Well seen	Obscured	Well seen
Vessels Normal	Attenuated sheathed	Thread like	Markedly attenuated	Nasal shift interrupted
Cup Saucer shaped	Obliterated	Saucer shaped	Obliterate	Deep large
Retina Normal	Central pigmentary	Transparent pigmentary	Bone corpuscle pigmentation	TIGROID FUNDUS

Causes of primary optic atrophy:

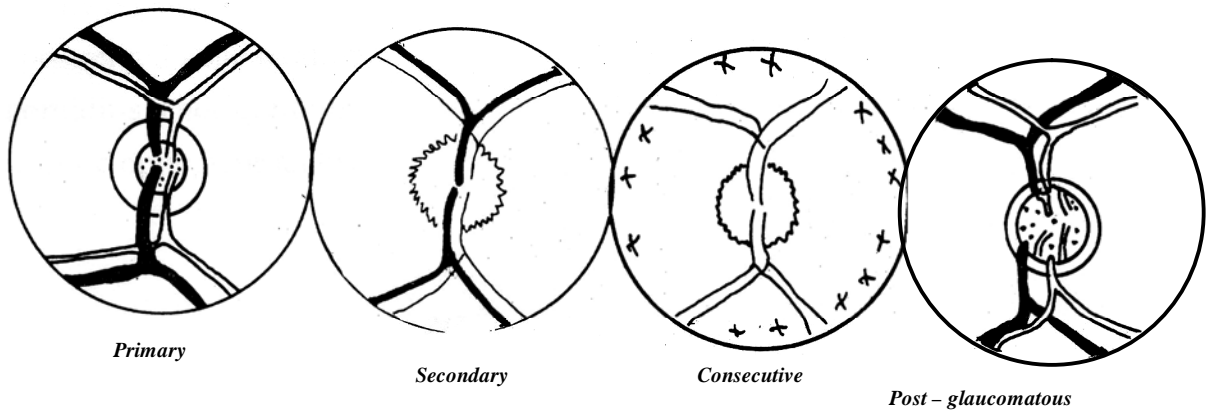
1. Central nervous system diseases: Tabes dorsalis, Disseminated sclerosis.
2. Severe blood loss, cardiac arrest, cardiac surgery.
3. Toxic e.g. Tobacco.
4. Pressure on the optic nerve, tumors, aneurysm, space occupying lesion.

Causes of secondary optic atrophy:

1. Papillitis.
2. Papilledema.

Causes of consecutive optic atrophy:

1. CRA occlusion.
2. Retinitis pigmentosa.
3. Chorioretinal degeneration.
4. High myopia.
5. Long-standing RD.
6. Diabetic retinopathy.
7. Choroiditis, chorioretinitis.
8. Ischemic optic neuropathy.



Types of optic atrophy

Investigations of optic atrophy:

1. Ophthalmoscopy.
2. Visual Field (VF).
3. Skull X –Ray.
4. Fluroscein Angiography (FA).

Table (19): Differential diagnosis of gradual painless progressive diminution of vision

	Senile cataract	Open angle glaucoma	Primary optic. A.	Senile M. D.	Progressive myopia
Pupil Color	White	Normal	Normal	Normal	Normal
Light reaction - Direct - Indirect	+ Ve + Ve	Sluggish Sluggish	Lost + Ve	Sluggish + Ve	+ Ve + Ve
Marcus Gunn	+ Ve	May by + Ve	+ Ve	May by + Ve	May by + Ve
Tension	Normal	High	Normal	Normal	Normal
Facility of aqueous outflow	Normal	Impaired	Normal	Normal	Normal
Field of vision	Cannot be done	Field defects of glaucoma	Marked peripheral const. or lost	Central scotoma especially for colors	May be arcuate or central scotoma
Refraction	Cannot be done	Variable	Variable	Variable	High myopia
Red reflex	Variable Normal if seen	Present Gl. Optic cup	Present White disc & atrophic	Present Sharply demarcated or several areas of chorioretinal atrophy	Present Myopic crescent, patches of chorioret. atrophy, fuch's spot, posterior staphyloma

Nystagmus

- Means involuntary oscillatory rhythmical movement of the eyes.
- It is usually bilateral and the movement is conjugate, coordinated and of equal intensity.

Clinical Forms:

1. **Jerky nystagmus:** It has two phases:
 - a. Slow movement in one direction.
 - b. Quick correcting jerk in the other direction (direction of nystagmus).

2. **Pendular nystagmus:**

Both phases are of equal speed and it is usually of ocular origin.

3. **Rotatory nystagmus:**

Oscillatory movements occur around the visual axis.

Causes:

1-Ocular nystagmus:

- a. Nystagmus due to defective central vision.
- b. Nystagmus due to blindness.
- c. Congenital idiopathic nystagmus.
- d. Spasmus Nutans.
- e. Miners disease.

2-Vestibular nystagmus:

- a. Lesions of labyrinth.
- b. Lesions of vestibular nerve.

3-Central nystagmus due to lesions of:

- a. Brain stem.
- b. Cerebellum.
- c. Spinal cord.

Treatment:

1. Treatment of the cause.
2. Optical: Correction of any error.
3. Medical: Anti parkinsonian drugs.
4. Surgical: Free tenotomy of muscles.

The Pupil

Functions of the Pupil:

- 1) Regulates the amount of light entering the eye.
- 2) By cutting peripheral rays, it diminishes spherical and chromatic aberrations of the eye.
- 3) It increases the depth of focus. The depth of focus is the distance along which an object can be moved without becoming blurred for a known amount of accommodation. The smaller the pupil, the greater the depth of focus.

I. The Light Reflex

When light falls on the eye, the pupil becomes constricted (direct light reflex) and so also the pupil of the other eye (consensual or crossed light reflex).

Pathway of light reflex:

1. *Stimulus:* Light.
2. *Receptors:* Rods and cones in the retina.

3. *Afferent*: From the retina fibers pass into the optic nerve. In the region of the chiasma the nasal fibers cross to reach the optic tract of the opposite side. The temporal fibers pass directly into the optic tract of the same side. The fibers leave the tract at its posterior third to enter the mid-brain and relay in the pre-tectal nucleus. From the pre-tectal nucleus a new neuron (inter-calated neuron) delivers the impulses to Edinger-Westphal nucleus on both sides i.e. another crossing.

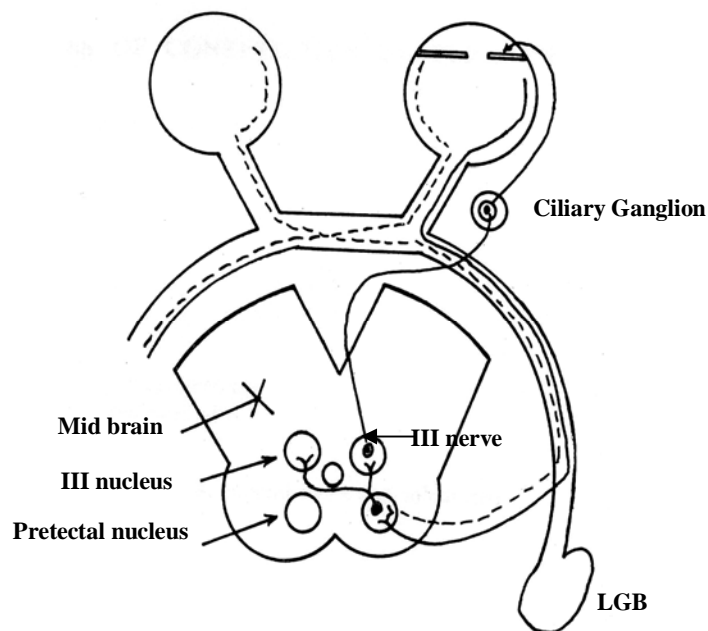
4. *Centre*: Edinger-Westphal nucleus (a part of third nerve nucleus).

5. *Efferent*: Along the oculomotor nerve to reach the ciliary ganglion along the branch from the nerve to the inferior oblique muscle. A relay occurs in the ciliary ganglion and post ganglionic fibers enter the eye (in short ciliary nerves) to supply sphincter pupillae muscle.

6. *Effector*: The sphincter pupillae muscle.

N.B: The consensual reaction is due to crossing of the fibers in:

- a- The chiasma b- The midbrain.



Pathway of pupillary Light Reflex

II. Near Reflex

When a near object is viewed, three related reflexes occur:

- (1) Accommodation: By contraction of ciliary muscle.
- (2) Convergence: By contraction of the two medial recti.
- (3) Miosis: By contraction of the sphincter pupillae.

All the three reflexes are associated (synkinesis) and are mediated by third nerve. The three reflexes form the near reaction.

Pathway:

1. *Stimulus*: Blurring of the image.
2. *Receptors*: Rods and cones.
3. *Afferent*: Rods and cones → optic nerve → chiasma (nasal fibers cross) → optic tract → lateral geniculate body → optic radiation → occipital cortex → frontal cortex → internal capsule → third nerve nucleus including Edinger Westphal nucleus.
4. *Centre*: Third nerve nucleus.
5. *Efferent*: The same as in the light reflex.

Causes of Constriction of Pupil (Miosis)

1) Physiological:

- a- Light reflex and accommodation reflex.
- b- During sleep.
- c- Senile miosis.
- d- Third stage of general anesthesia.

2) Drugs:

- a- Local miotics (Pilocarpine, Eserine, Di-isopropyl fluoro phosphate).
- b- Opium, morphine and parathion poisoning.

3) Local Cause:

- a- Acute iritis.
- b- Hypermetropia.
- c- Traumatic miosis.
- d- Puncture of anterior chamber.

4) Nervous:

- a- Horner's syndrome (ptosis, miosis, enophthalmos and anhidrosis).
- b- Argyll Robertson's pupil.
- c- Pontine hemorrhage.
- d- Irritative stage of extradural hemorrhage (Hutchinson's Pupil).

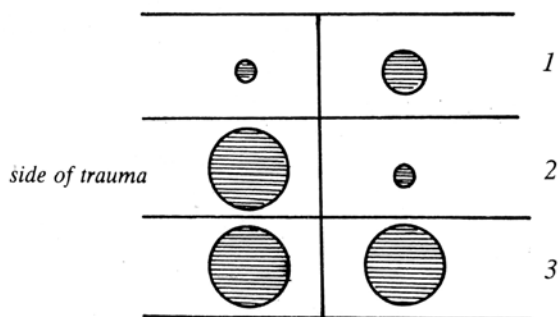
Hutchinson's Pupil

In traumatic subdural hemorrhage, consciousness is often disturbed and observation of the pupil becomes of utmost value. If hemorrhage is increasing coma will deepen and the pupils show the following changes:

Table (20): Hutchinson's pupil

Stages	Ipsilateral pupil	Contralateral pupil
Early	Constricted	Normal reactive
More advanced	Dilated not active	Constricted
Advanced	Dilated not active	Dilated not active

A dilating pupil plus a coma of increasing depth is an indication for cerebral decompression.



Hutchinson's Pupil

Argyll Robertson Pupil

It is a small irregular pupil (mostly bilateral) which does not react to light but reacts to accommodation (light near dissociation). It dilates poorly in the dark and with atropine.

Etiology: Commonest cause is neuro-syphilis (tabes dorsalis and general paralysis of insane GPI) less common causes are: diabetes, encephalitis and cerebral tumors. The site of the lesion is in the intercalated neuron near the aqueduct. A lesion in this locality interrupts the pupillary light reflex and spares the accommodation reflex.

Horner's syndrome

(Oculosympathetic palsy) consists of ptosis, miosis, anhidrosis, enophthalmos, and heterochromia iridis.

Causes of Dilatation of pupil (Mydriasis)

1) Physiological:

- a- Withdrawal of light.
- b- Second and fourth stage of general anesthesia.
- c- Excitement, fear and anger.

2) Drugs:

- a- Local mydriatics (Atropine, Homatropine, Hyoscine, Cocaine, Tropicamide, Cyclopentolate).
- b- Datura poisoning.

3) Local Causes:

- a- High myopia.
- b- Acute congestive glaucoma.
- c- Traumatic mydriasis.
- d- Optic atrophy and retinal degeneration.
- e- Central retinal artery occlusion.

4) Nervous:

- a- All causes of coma except pontine hemorrhage, morphine and parathion poisoning.
- b- Third nerve (Oculomotor) paralysis.
- c- Paralytic stage of Hutchinson's pupil.

Field Changes due to Lesions in visual pathway

1. Lesions in optic nerve:

Monocular field defects on the same side, normal field on the other side.

2. Lesions in optic chiasma:

Bitemporal hemianopia due to interruption of the nasal fibers of the optic nerve crossing at the chiasma. The commonest cause is pituitary tumors.

3. Lesions in optic tract:

Contra-lateral homonymous hemianopia that respect the vertical meridian.

4. Lesions in optic radiations:

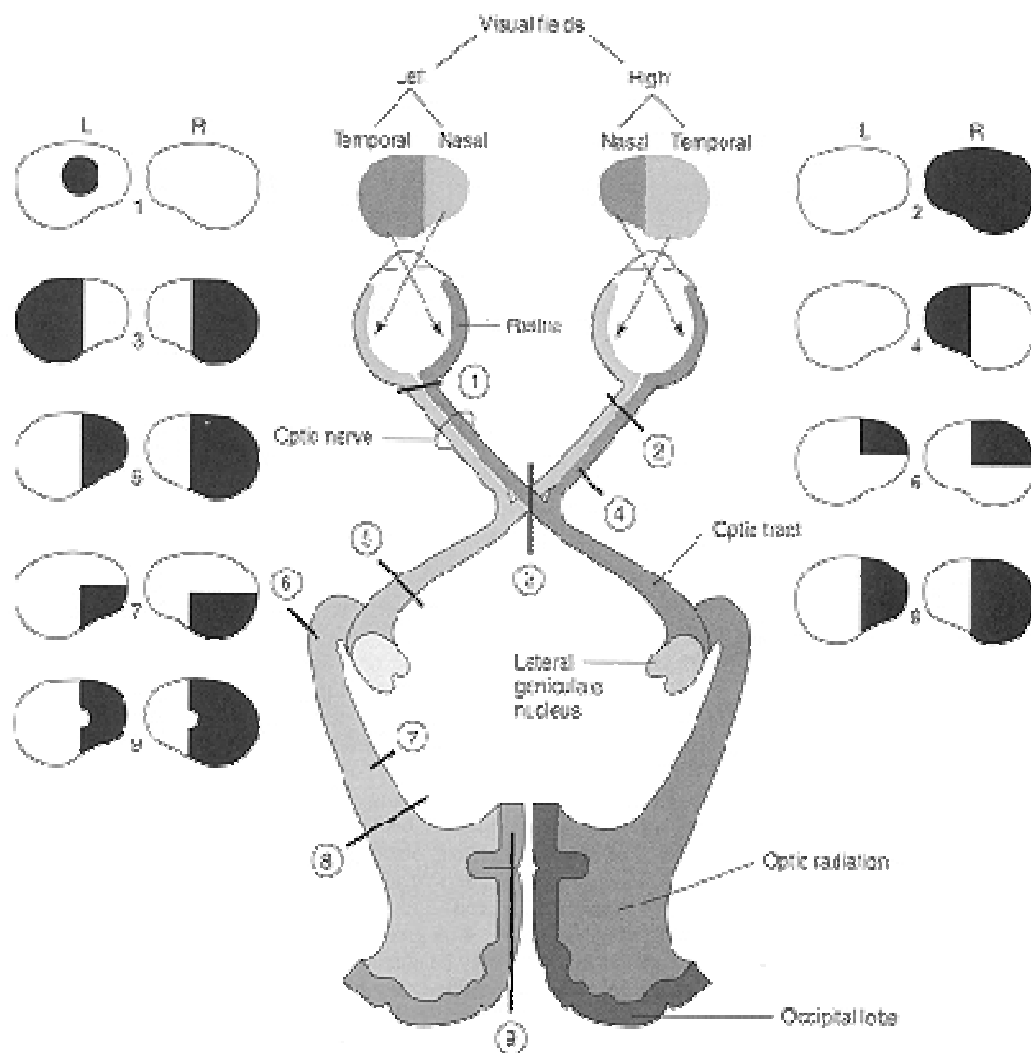
- a. Temporal lobe lesions: Contralateral homonymous superior quadrantanopia with hemiparesis and dysphasia.
- b. Parietal lobe lesions: Contralateral homonymous inferior quadrantanopia with agnosia.

5. Lesions in occipital cortex:

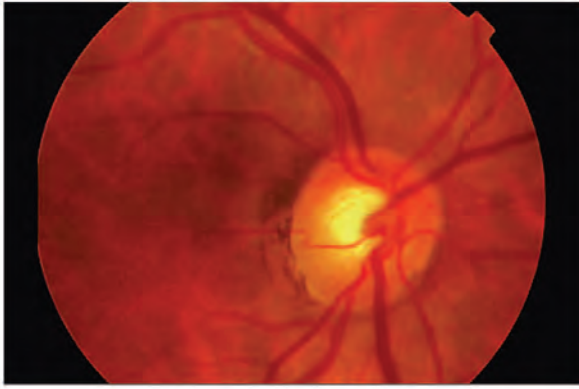
Contra-lateral homonymous hemianopia with macular sparing.

Macular sparing in occipital cortex lesions can be explained by:

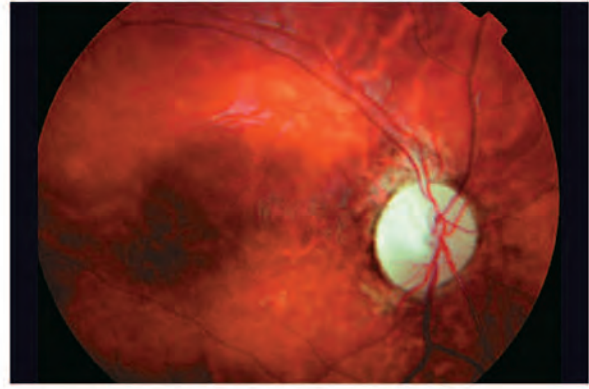
- a. Dual blood supply of the macular area (from the middle and the posterior cerebral arteries).
- b. Bilateral representation of the macular fibers.
- c. Large area of macular representation in the occipital cortex.



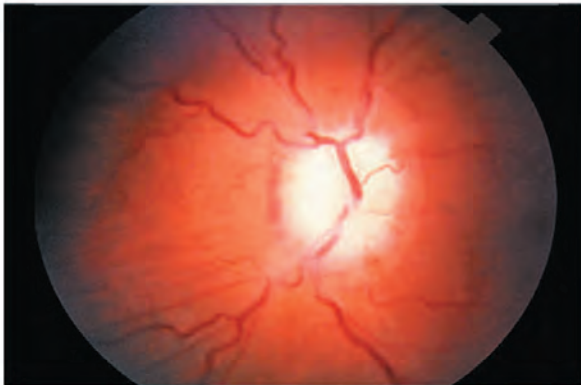- 1= Central scotoma secondary to optic neuritis (does not respect the vertical meridian).
- 2= Total blindness of the right eye from a complete lesion of the optic nerve.
- 3= Bitemporal hemianopia from a complete lesion of the optic chiasm.
- 4= Right nasal hemianopia from a perichiasmal lesion.
- 5= Right homonymous hemianopia from a complete left optic tract lesion.
- 6= Right homonymous superior quadrantanopia caused by partial involvement of the optic radiation in the left temporal lobe.
- 7= Right homonymous inferior quadrantanopia caused by partial involvement of the optic radiation in the left parietal lobe.
- 8= Right homonymous hemianopia from a complete lesion of the left optic radiation.
- 9= Right homonymous hemianopia (with macular sparing) from a posterior cerebral artery occlusion causing ischemia of the calcarine cortex of the occipital lobe.



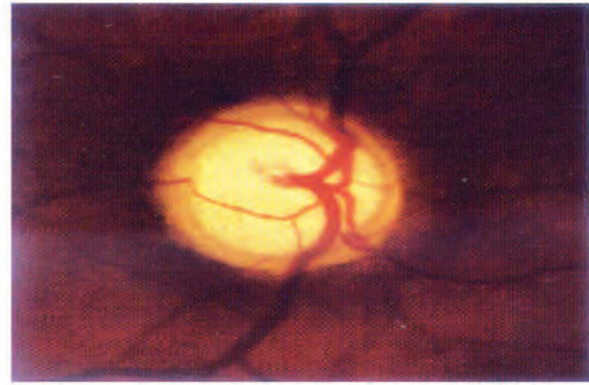
Normal optic disc



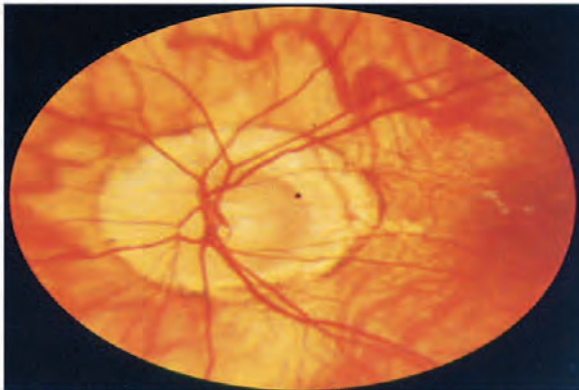
Primary optic atrophy



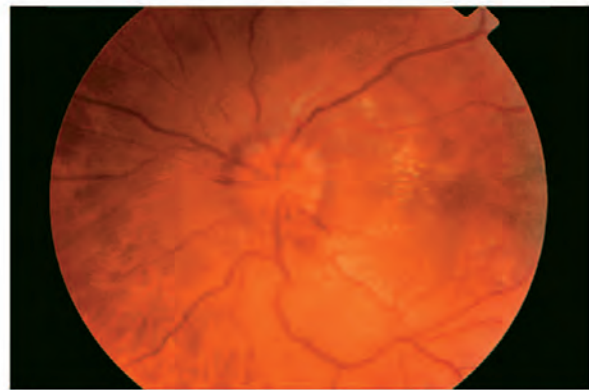
Secondary optic atrophy



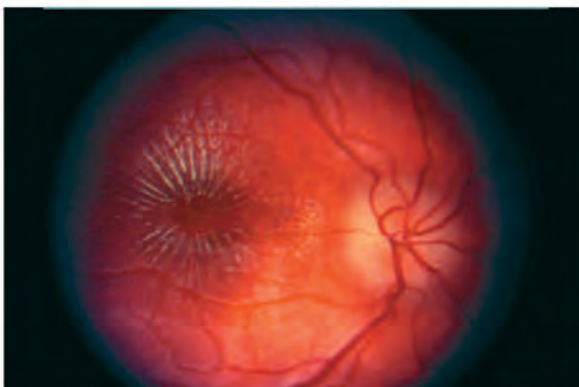Advanced glaucomatous cupping



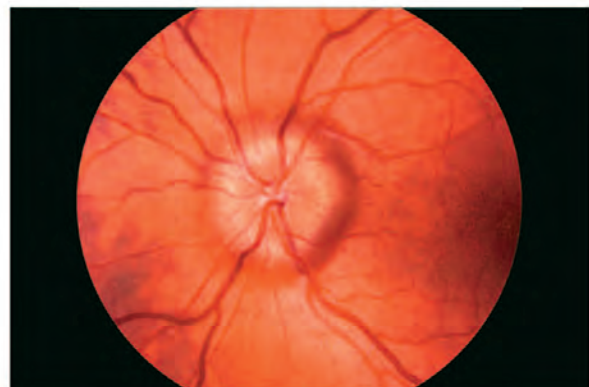Consecutive optic atrophy



Severe papillitis with flame-shaped haemorrhages and an early macular star



Papillitis associated with a complete macular star



Disc hyperaemia and slight elevation in early papilloedema

Chapter 16

Ocular Trauma

Classification of Ocular Injuries:

1. Mechanical injuries:

- a. Non – perforating i.e. blunt trauma.
- b. Perforating.
- c. Injuries with retained foreign body.

2. Chemical injuries.

3. Physical injuries:

- a. Thermal.
- b. Radiation.

Blunt Trauma

If a large object (such as a football) hits the eye, most of the impact is usually taken by the orbital margin. If a smaller object (such as a tennis ball) hits the area, the eye itself may take most of the impact.

Effects of blunt injuries on the orbital and ocular structures:

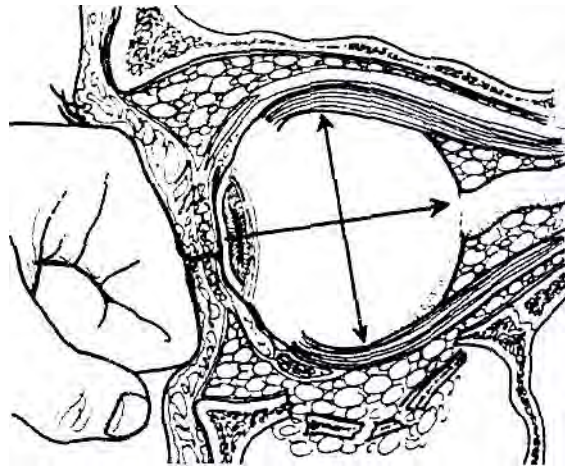
1) Orbit:

- Traumatic proptosis from orbital hemorrhage.
- Traumatic enophthalmos from fracture of the orbital floor (blow-out fracture).
In this case, the rise of intra-orbital pressure causes fracture of the thin orbital walls, especially the floor.

Signs and symptoms of a blow-out fracture:

- Peri-orbital emphysema (air in the lids) is often present. It is caused by communication between the orbit and the peri-orbital sinuses.

- Diplopia and defective eye movement, usually elevation, due to entrapment of an extra-ocular muscle in the fractured site.
- Enophthalmos due to herniation of fat into the maxillary sinus.



Blow-out fracture

Management:

1. Oral antibiotics (to protect against sinus bacteria and the development of orbital cellulitis).
2. Surgery will aim at correcting persistent problems as diplopia and disfiguring enophthalmos.

2) Eyelids:

1. Ecchymosis of the eyelids (traumatic black eye):

Treatment:

- a. Cold compresses in the first 24 hours (leads to vasoconstriction).
- b. Hot compresses after 24 hours helps absorption.

2. Lid lacerations:

- a. Horizontal wounds: Do not gape and produce a small scar.
- b. Vertical wounds: Gape and need suturing.

3. Traumatic ptosis:

- a. Mechanical from blood or edema.
- b. Paralytic from injury of the levator muscle or its nerve supply.

3) Conjunctiva:**1. Sub-conjunctival hemorrhage:**

Blood under the conjunctiva (due to ruptured conjunctival vessels) from blunt injury should be differentiated from that leaking from a fracture of the base of the skull due to severe head injury.

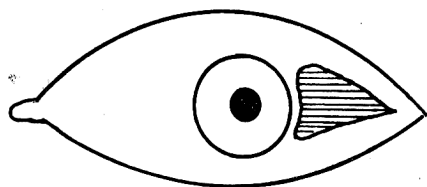
2. Conjunctival lacerations: Are sutured if large.

3. Chemosis: Edema of the conjunctiva.

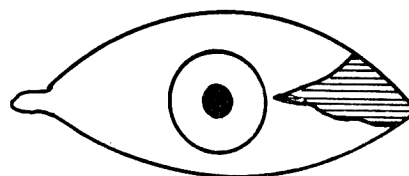
Table (21): Differential diagnosis of subconjunctival hemorrhage

	Local ocular trauma	Fracture base of skull
Onset	Immediate	Delayed
Trauma	To the eye with no proptosis	To the head with proptosis
Consciousness	Normal	Loss of conscious
Site	Usually on the temporal side	Usually in the fornices
Shape	Triangular, base towards the cornea	Triangular, apex towards the cornea
Color	Bright red	Dark red
Posterior limit	Seen	Not seen

Subconjunctival Haemorrhage



Due to local trauma



Due to fracture base

4) Cornea:

1. Corneal foreign Bodies:

Corneal foreign bodies are removed from the surface of the cornea by using a foreign body spud after instilling topical anesthesia. Topical cycloplegic, antibiotic drops and ointment are then instilled with patching of the eye.

2. Corneal abrasions:

Cause severe pain and photophobia.

Treatment: Topical cycloplegic, antibiotic and patch.

3. Recurrent corneal erosions:

They can be caused by scratches with fingernails or paper. Recurrent corneal erosions occur as a result of slight trauma such as opening the eyes in the morning due to imperfect healing of the epithelial basement membrane.

4. Blood staining of the cornea:

Is due to hyphema with increased intraocular pressure.

Clinically: The color of the cornea is reddish brown then greenish gray.

Clearing occurs from the periphery to the center by phagocytic action.

Complete clearing takes about 1-2 years.

Treatment:

- a. Prompt control of intraocular pressure in cases of hyphema to avoid blood staining of the cornea.
 - b. Keratoplasty if blood-staining becomes permanent.
- 5. Corneal edema:** Due to trauma to the endothelium and Descemet's membrane.

6. Rupture of the cornea:

It is less common than rupture of the sclera (as the cornea is stronger than the sclera).

Treatment: Suturing of the corneal wound.

5) Sclera:

Scleral rupture (ruptured globe):

Site: The rupture is usually up and in (concentric with and about 3 mm behind the limbus) because the trauma usually comes from down and out where the globe is least protected and the eyeball is pushed against the trochlea.

Signs and Symptoms:

1. Sudden diminution of vision.
2. Pain, watering and redness of the eye.
3. Chemosis of the conjunctiva and/or sub-conjunctival hemorrhage.
4. Shallow AC (with or without hyphema).
5. Hypotony (low ocular tension).
6. Abnormal site, size, and shape of the pupil.
7. Uveal prolapse.

Treatment:

1. Scleral repair with reposition of the prolapsed uvea.
2. Scleral repair with abscission of the prolapsed uvea if the eye is badly damaged to avoid infection.
3. Enucleation if the eye is seriously damaged with no perception of light (to avoid sympathetic ophthalmitis in the other eye).

6) Anterior Chamber:

Traumatic hyphema:

Blood in the anterior chamber due to ruptured iris vessels.

Treatment:

The goal of treatment is to prevent re-bleeding and complications related to high IOP and blood staining of the cornea.

1. Bed rest in a semi-sitting position.
2. Daily measurement of the ocular tension.
3. No aspirin or non-steroidal anti-inflammatory drugs.
4. Topical steroids to control iritis.
5. Topical beta blockers to control IOP (Timolol or Betaxolol).
6. Oral Aminocaproic acid, an antifibrinolytic, 50-100 mg /Kg every 4 hours to avoid rebleeding.
7. Immediate evacuation of the hyphema (paracentesis) if there is high IOP or early blood staining of the cornea.

7) Iris:

1. Traumatic iritis: Inflammation of the iris and ciliary body secondary to any type of trauma.

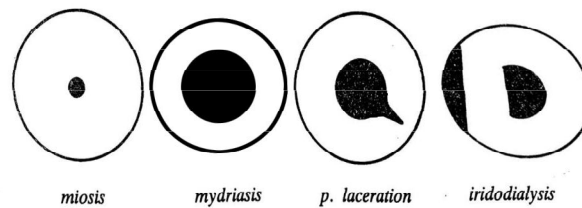
2. Iris sphincter tears:

Defects in the constrictor pupillae muscle at the pupillary border. They appear clinically as small V-shaped tears at the pupillary border. Mydriatics should be avoided since they enlarge the tears.

3. Irido-dialysis:

Separation of the root of the iris from the ciliary body. The pupil appears D-shaped. The patient may complain from uniocular diplopia or glare. Iridodialysis is often associated with hyphema.

4. Traumatic aniridia: Complete avulsion of the iris at its root.



Traumatic lesions of Iris and Pupil

8) Pupil:

May be damaged by blunt trauma and react poorly to light. This is particularly important in a patient with an associated head injury, as a poor reaction to light may be interpreted as a sign of increased intra-cranial tension.

1. Traumatic mydriasis: Due to paralysis of the third nerve fibers. It is usually associated with paralysis of accommodation and blurring of near vision.
2. Traumatic miosis: Occurs with milder trauma and is due to iridocyclitis.

9) Ciliary Body:

1. Traumatic spasm of accommodation (cyclospasm) with temporary myopia.
2. Traumatic paralysis of accommodation.
3. Suppression of aqueous humor secretion with hypotony.
4. Ciliary body injury near the angle with angle recession glaucoma.
5. Cyclo-dialysis: Separation of the ciliary body from the scleral spur usually with severe hypotony.

10) Lens:

1. Lens subluxation and dislocation: Due to rupture of the zonules.

Signs and symptoms:

- a. Decreased visual acuity.
- b. Monocular diplopia if the lens is subluxated.
- c. High degrees of astigmatism.
- d. Impaired accommodation.
- e. Tremulous iris due to loss of the lens support in its normal position.
- f. Deep (Dislocation) or irregular (Subluxation) anterior chamber.

Complications:

- a. Pupillary block glaucoma with anterior lens dislocation.
- b. Phaco-anaphylactic glaucoma with posterior dislocation.

Management:

Dislocated lenses should be removed to avoid complications.

2. Traumatic cataract:

1. Vossius ring: A circle of iris pigment on the anterior lens capsule due to the impress of the pupillary border of the iris on the lens.
2. Posterior cortical opacities: Posterior cortical cataract is more common, as the posterior capsule is thinner than the anterior capsule.
3. Rosette-shaped (Sunflower) cataract: Is pathognomonic of blunt trauma and is due to disruption of the lens architecture at the cortical sutures. It is called concussion cataract.

11) Vitreous:

1. Vitreous hemorrhage.
2. Vitreous opacities or floaters.
3. Vitreous prolapse through a ruptured globe with traction on the retina.
4. Avulsion of the vitreous base causing retinal disinsertion.

12) Choroid

1. Rupture of the choroid: A linear rupture may occur concentric with the optic disc. In recent trauma, the edges are covered with hemorrhage but later the white sclera is seen through the ruptured choroid. The condition is usually asymptomatic. If the rupture is underlying the fovea, vision will be severely affected.
2. Traumatic choroiditis.
3. Choroidal effusion or hemorrhage.
4. Spontaneous choroidal detachment from hypotony.

13) Retina

1. Commotio retinae:

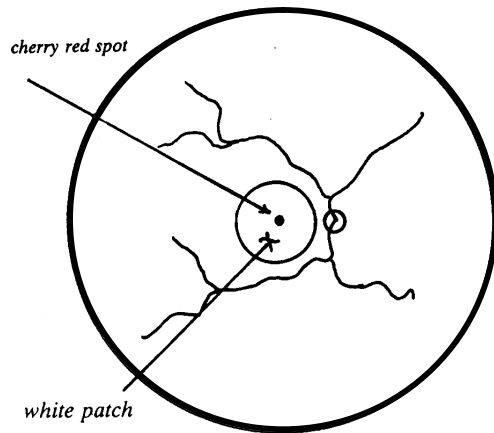
- Retinal edema caused by the contre-coup injury to the posterior pole, causing swelling of the ganglion cells.
- *Complaint:* Acute drop in visual acuity.
- *Fundus picture:* Retinal opacification (usually grayish- white) with or without scattered retinal hemorrhages and cherry-red fovea.
- Visual recovery usually occurs spontaneously within a month. Some cases may develop macular degeneration or macular holes with severe loss of the visual acuity.

2. Hemorrhages: Retinal (superficial or deep) or subhyaloid.

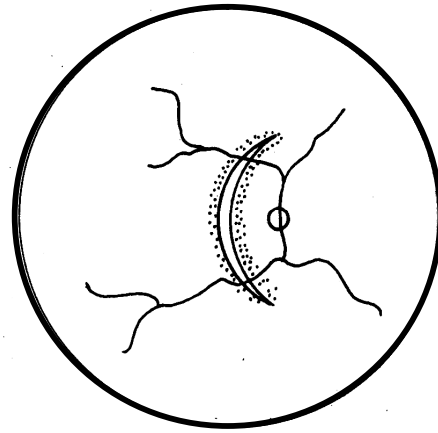
3. Retinal tears, dialysis: Giant retinal tears and retinal disinsertion are a common cause of traumatic retinal detachment.

4. Retinal detachment may be:

- i. Rhegmatogenous due to retinal tears.
- ii. Exudative due to severe hypotony.
- iii. Tractional due to vitreous prolapse and incarceration in a sclera wound.



Comotio Retina



Rupture of the Choroid

14) Optic Nerve

1. Hemorrhage of the optic nerve sheaths.
2. Edema of the optic nerve with hypotony.
3. Avulsion of the optic nerve with twisting injuries.
4. Traumatic optic atrophy usually of the primary type.

Perforating Ocular Trauma

- Corneal and scleral lacerations are due to perforating trauma to the eye with a sharp object such as a nail, knife, needle, scissors, or a piece of glass.
- Penetrating injuries may or may not be accompanied with an intraocular foreign body.

Clinical effects:

1. Mechanical (immediate effects):
 - Wounds of the lids, conjunctiva, cornea or sclera.
 - Uveal prolapse with or without vitreous loss.
 - Traumatic cataract.

2. Ocular infections: Severe infections usually follow in 24-48 hrs while milder infections and fungal infections, may be delayed.
3. Sympathetic ophthalmitis usually develops after a long latent period (up to several years).
4. Intraocular foreign body (IOFB): With serious consequences depending on the type of FB.

Clinical picture of globe perforation: See scleral rupture.

Examination:

The eye should be gently examined and handled with care. Direct pressure on the globe should be avoided for fear of rupturing a partial thickness wound.

Management:

1. Immediate patching and prophylactic systemic antibiotics.
2. Anti-tetanus toxoid may be given if the patient is not vaccinated.
3. X-ray is done to exclude the presence of IOFB.
4. Anti-emetics may be given because vomiting is very dangerous with an open globe.
5. Surgical repair of the wound.
6. Enucleation if there is no hope of repair to avoid sympathetic ophthalmitis.

Intra-Ocular Foreign Bodies (IOFBs)

1. The most common types of foreign bodies that hit the eye are metallic. They may be magnetic as iron or nonmagnetic as lead and copper. Non-metallic foreign bodies as glass are also common.
2. Metallic foreign bodies tend to enter the eyes of workers who operate high-speed grinders without goggles or those using a hammer and chisel without protection.
3. Lead pellets are also common from firearm injuries.
4. Glass foreign bodies usually result from car accidents or breakage of eye glasses.

Effects of IOFB:

1. Clinical effects of perforating trauma (see before).
2. Chemical effects: Are delayed and depend on the chemical nature of the FB as siderosis bulbi with iron FBs or, chalcosis bulbi with copper FBs.

A. Siderosis bulbi:

Manifestations:

1. Siderotic cataract: It is not a true cataract, but a rusty discoloration due to iron in the subcapsular epithelium.
2. Heterochromia iridis: With the ipsilateral iris darker.
3. Secondary open angle glaucoma from scarring of the trabecular meshwork.

B. Chalcosis bulbi:

Mechanism:

1. Pure copper produces severe inflammation that simulates endophthalmitis.
2. Copper in alloys binds specifically to collagen and basement membranes.

Manifestations:

1. Deposition in descemet's membrane leads to a golden brown ring; (Kayser-Fleisher ring).
2. Sunflower cataract.

Management of IOFB:

1. FBs should be localized by careful fundus examination, X-ray or CT scan.
2. Removal of the foreign body, except if it is small and inert e.g. small pieces of glass or plastic.
3. Removal of IOFB usually requires pars-plana vitrectomy and removal with a FB forceps.
4. Magnetic FBs may be pulled out with a magnet.
5. Any ocular injuries are repaired.
6. If the eye is badly damaged, enucleation is indicated to avoid sympathetic ophthalmitis.

Chemical Injuries

Exposure of the eye to chemicals is rather common and could result in various effects that range from very mild to very severe.

Exposure may be accidental, including household material as detergents, or due occupational injury with strong chemicals as acids, alkalies and war gases.

Alkali burns:

The most serious chemical burns are produced by alkalis such as lime (CaO), KOH, NaOH, cement, plasters, aniline dyes and ammonia, which are present in household detergents, fertilizers, and refrigerants.

Lime (CaO), when combined with water of tears & tissues it transforms to Ca(OH)_2 resulting in severe heat, caustic effect penetrating deeply to the eye tissues.

Alkali burns are more severe than acid burns because of their rapid penetration, (often in less than one minute), through the cornea and anterior chamber. They combine with cell membrane lipids thereby resulting in disruption of the cells and necrosis of the tissues.

Acid burns:

Such as battery fluid (sulfuric acid) and laboratory glacial acetic acid and bleach. They cause their maximum damage within the first few minutes to hours and are less progressive and less penetrating than alkalies. Acids precipitate tissue proteins that rapidly set up barriers against deep penetration.

War gases:

Such as mustard gas can cause severe keratitis and permanent corneal scar.

Clinical picture of chemical injuries:

Symptoms:

1. Pain.
2. Lacrimation.
3. Photophobia.
4. Diminution of vision.

Signs:

1. Mild to moderate exposure:
 - a. Eyelid edema.
 - b. Chemosis.
 - c. Conjunctival injection.
 - d. Corneal abrasions.
 - e. Anterior uveitis.

2. Severe exposure:

- a. Conjunctival and episcleral whitening (coagulative necrosis).
- b. Corneal edema and opacification with corneo-scleral melting.
- c. Severe iritis.
- d. Secondary glaucoma.
- e. Posterior segment destruction.

Emergency Treatment of Chemical Burns:

- Immediate copious irrigation of the eye with antidote if available, otherwise plain water or saline for at least 1 hour in severe injuries and with several liters of water.
- In lime burn, picking of the lime particles must be done before irrigation to avoid excessive heat production.
- Irrigation should never be delayed for any reason.
- It is better to place an eye speculum and topical anesthesia in the eye before irrigation. The lower lid is pulled down and the upper lid is everted to irrigate the fornices.
- Conjunctival pH should be tested 10 minutes after cessation of irrigation using litmus paper and irrigation should be continued until neutral pH is reached (7.4).

Specific antidotes:

If the nature of chemical is known, the proper first aid is washing the eye by specific antidote for example in:

1. *Alkali burns:* Boric acid 4%, Citric acid (lemon juice) or Acetic acid (vinegar).
2. *Acid burns:* Sodium bicarbonate 3% is used.
3. *Lime burns:* Neutral ammonium tartarate 10%, Concentrated glucose 40% or saturated sugar solution.

4. *Iodine burns*: Atropine, starch suspension or milk is used.
5. *Aniline (Hair) dye burns*: Tannic acid or glycerol or dilute alcohol.
6. *E.D.T.A* 1% is a universal antidote.

In mild to moderate exposure:

1. Analgesics.
2. Topical antibiotics, cycloplegics.
3. Lubrication with eye ointments or tears substitutes to prevent symblepharon.
5. Topical steroids (in the absence of corneal abrasions) to reduce inflammation.
6. Oral Acetazolamide (Diamox) or topical beta-blockers to treat any rise in the IOP.

In severe exposure:

1. Debridement of necrotic tissue and glass rod lysis of symblepharon.
2. Topical steroids should not be used if the corneal epithelium is not intact.
3. Tarsorrhaphy in cases of lagophthalmos due to the severe damage of lids.
4. Limbal, conjunctival, and autograft transplants and even penetrating keratoplasty in cases of severe corneal melting.

Physical Injuries

The eyes may be exposed to a wide variety of electromagnetic radiations such as:

1. **Longer infrared waves:** Longer infrared waves cause cataract seen in glass blowers and furnace workers. It is prevented by the use of protective goggles.

Solar rays: Looking directly at the sun may result in a burn of the central retina. This is particularly common at the time of the solar eclipse.

2. **Shorter wavelength (ultraviolet rays):** Exposure to UV rays occurs with welding arcs and in skiing (snow blindness), if protective goggles are not used. After a latent period of 6-8hrs, severe photophobia and lacrimation occur due to multiple dense punctate corneal epithelial erosions. The photophobia lasts until the epithelium heals in 12-24 hrs. The condition is known as photophthalmia.

Treatment requires patching until the corneal epithelium heals.

3. **Microwaves:** May cause cataract.

4. **X-rays:** Therapeutic but not diagnostic doses of X-rays tend to cause cataracts and the eye should be suitably shielded during treatment.

5. **Visual display units and television sets:** Eye strain may occur after several hours of exposure.

Sympathetic Ophthalmitis

A bilateral specific diffuse inflammation of the entire uveal tract, usually following perforating trauma to one eye.

Etiology:

Allergy to uveal pigment of the injured (exciting) eye.

Predisposing factors:

- Perforating wounds especially those involving the ciliary body and associated with uveal prolapse or incarceration of tissue in the wound.
- A penetrating injury associated with retained intra ocular foreign body.

Clinical picture:

Latent period:

Usually 4-8 weeks following eye trauma.

May be short as 10 days.

May be long as 30 years.

Symptoms:

1. History of trauma to one eye in most of the patients.
2. Pain, photophobia, lacrimation and defective vision.

The symptoms are bilateral but they start in the exciting eye followed few days or weeks by the sympathizing eye.

Signs:

1. Signs of bilateral iridocyclitis with variable degree of severity.
2. Signs of trauma in the exciting eye may be evident (e.g. retained intra ocular foreign body, wound dehiscence, ciliary body or lens incarceration in the wound).

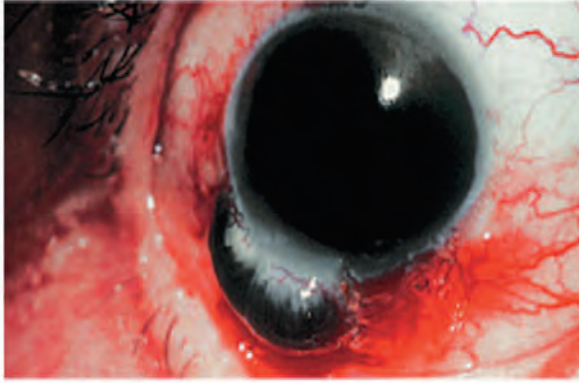
Management:

a) Prevention is very important:

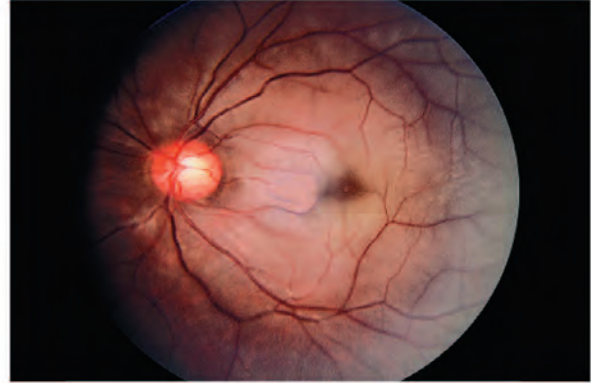
1. Enucleation of a grossly injured eye.
2. If there is hope to restore some vision: any prolapsed tissue should be excised, any foreign body should be removed and the wound properly sutured without tissue incarceration.
3. Regular examination of both eyes postoperatively to detect early signs of inflammation.

b) Treatment:

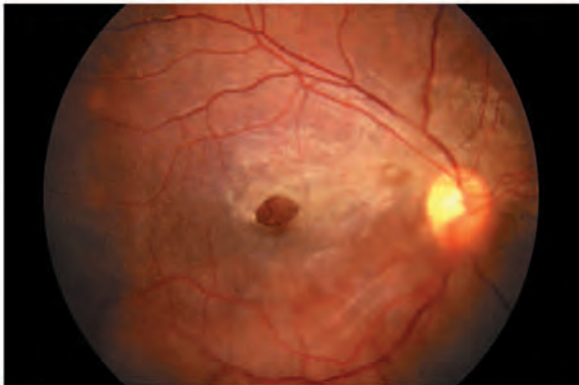1. Corticosteroids and Atropine for both eyes to quieten the inflammation in doubtful eyes. It may be required for months for fear of recurrence.
2. Enucleation of the exciting eye may be needed if there is no response to medical treatment within 2-3 weeks to save the sympathizing eye.



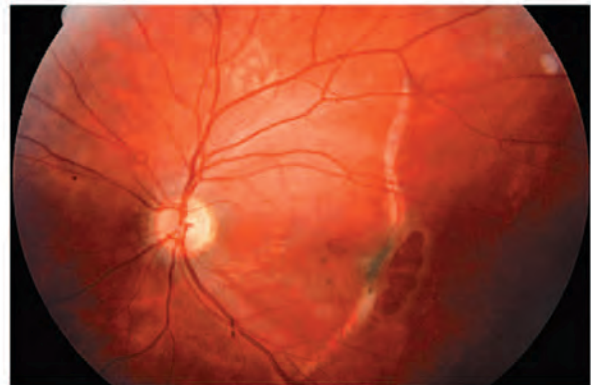
Total hyphaema and iris prolapse



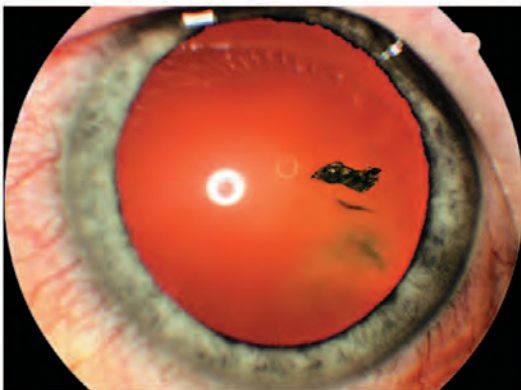Severe commotio retinae with a cherry-red spot at the fovea



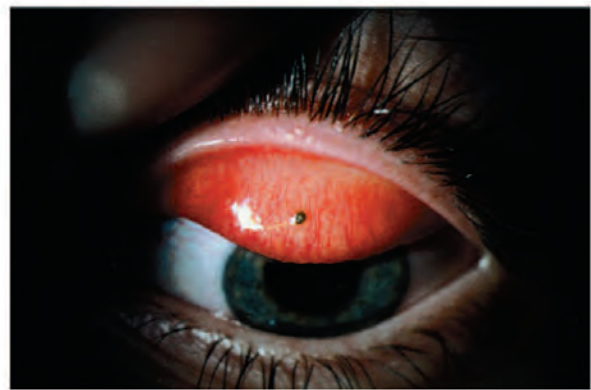Traumatic macular hole



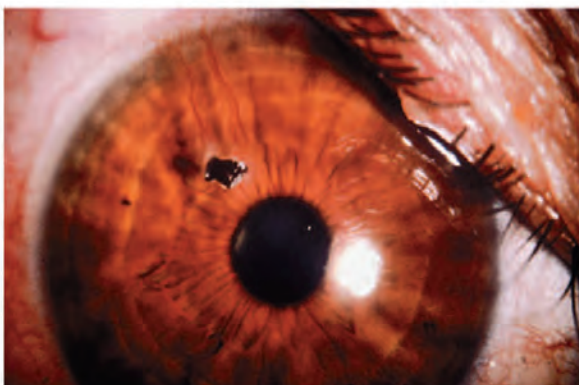
Old choroidal rupture associated with macular hole



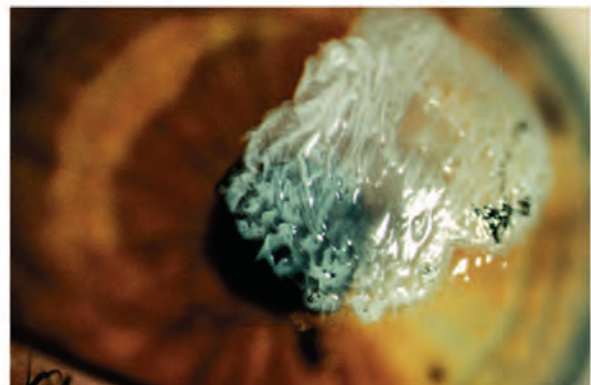
Metallic intralenticular foreign body



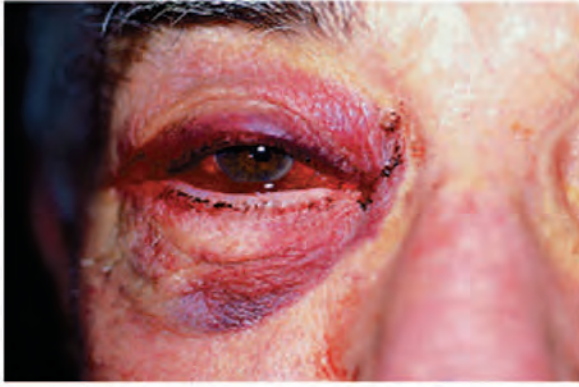Foreign body in upper palpebral conjunctiva



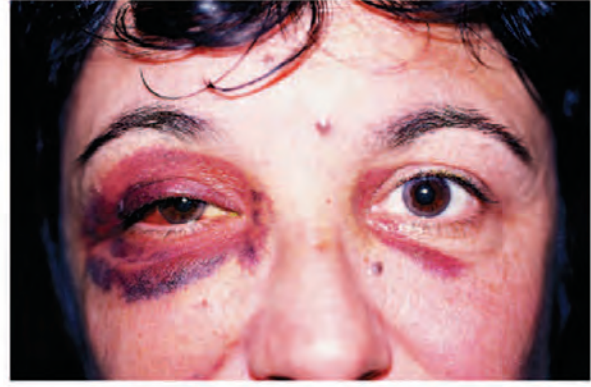A metallic corneal foreign body



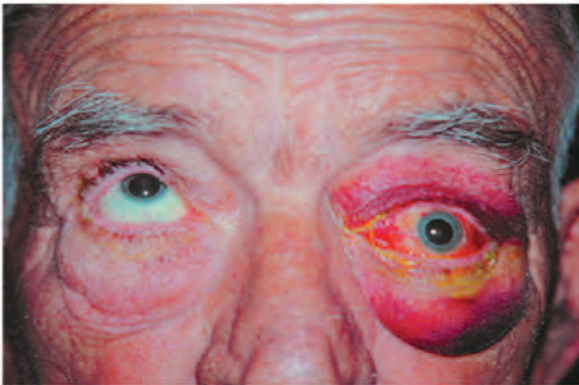Thermal burn to the cornea



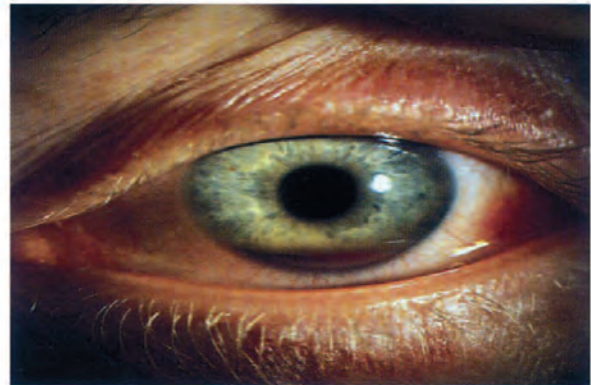
Periocular ecchymosis and subconjunctival haemorrhage



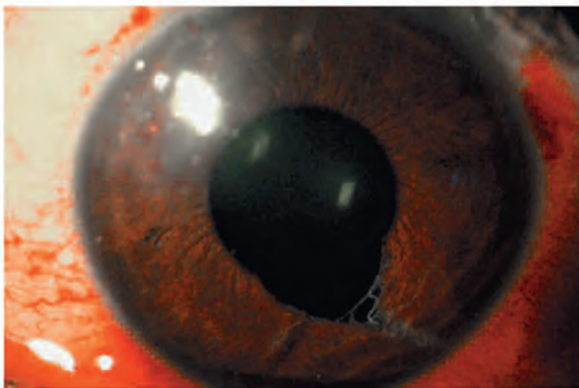
Bilateral periocular ecchymosis



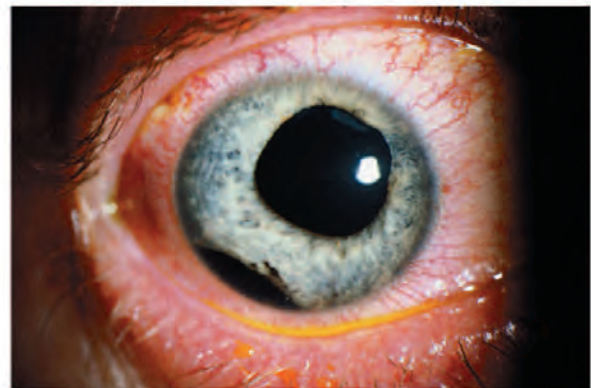
Left restriction of upgaze due to entrapment of the inferior rectus muscle



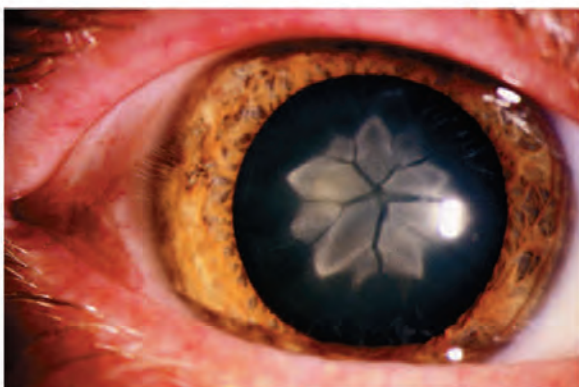
Hyphaema



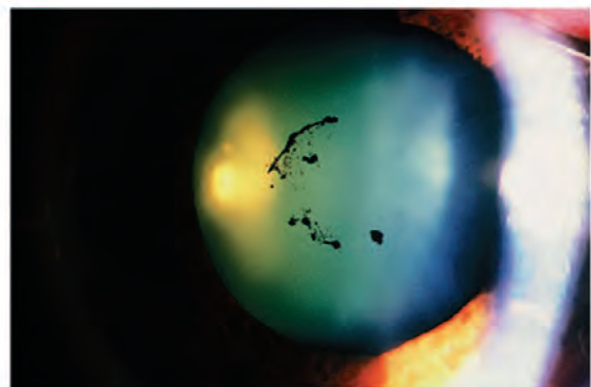
Large radial iris tear



Iridodialysis



Rosette-shaped cataract



Vossius ring

Chapter 17

Medical Ophthalmology

Eye Manifestations in Systemic Diseases

Many systemic diseases, as well as drugs used to treat them, have significant ocular manifestations. The most common systemic diseases affecting the eye include:

1. Infectious diseases.
2. Blood disorders.
3. Collagen diseases.
4. Endocrine disorders.
5. Metabolic diseases.
6. Nutritional deficiencies.
7. Intoxications.

1. Infectious Diseases

1. Kerato-Conjunctivitis:

This can be part of many viral infections as measles, chicken pox and rubella. Granulomatous infections as tuberculosis and syphilis can produce chronic granulomatous conjunctivitis.

2. Sub-conjunctival hemorrhage:

May occur in hemorrhagic fevers as in Rift valley fever, Ebola virus, and spirochaetal diseases.

3. Uveitis:

May be a manifestation of many viral infections. Metastatic purulent uveitis (Endophthalmitis) can occur with pyogenic bacteria as in intravenous drug abusers. Granulomatous uveitis occurs with tuberculosis and syphilis.

4. Retinitis:

Specific forms of retinitis may occur with cytomegalovirus infection in AIDS patients. Acute retinal necrosis can occur with herpes simplex retinitis. Congenital rubella can produce a retinitis pigmentosa like disease in the newly born (salt and pepper fundus). Cysticercosis may give rise to sub-retinal parasitic cysts and toxocara species can produce a retinal granuloma in children.

5. Optic neuritis and subsequently optic atrophy:

Can occur with encephalitis and meningitis of viral or bacterial origin. Optic atrophy may be a complication of therapy as with the use of ethambutol (anti-tuberculous drug).

6. Orbital parasitic cysts:

May be seen in hydatid disease (*Echinococcus granulosus*) and myositis of the extra-ocular muscles is a characteristic feature of *trichenella spiralis* infestation.

2. Blood Diseases

1. Coagulation disorders:

As haemophilia, thrombocytopenia and anti-coagulant therapy can produce hemorrhage anywhere in the eye. The most significant of which are vitreous and retinal hemorrhages.

2. Severe anemia:

Can produce pallor of the conjunctiva, retinal hemorrhages and optic disc edema. Sickle-cell anemia can produce retinal arteriolar occlusions and retinal neo-vascularization.

3. Hematological malignancies:

As leukemias and lymphomas can produce a wide variety of manifestations including sub-conjunctival hemorrhage, orbital infiltrations and proptosis, uveal nodules and retinal pale-centred hemorrhages (Roth spots).

3. Collagen Diseases

This is a group of diseases involving the joints and connective tissue all-over the body. They include rheumatoid arthritis, systemic lupus erythematosus, polyarteritis nodosa, scleroderma, polymyositis and Sjogren syndrome.

1. Dry eye (Kerato-Conjunctivitis Sicca):

Loss of the watery component of tears due to atrophy of the main and accessory lacrimal glands.

2. Keratitis, keratolysis:

Spontaneous sterile corneal perforations and scleritis are common manifestations of rheumatoid arthritis.

3. Irido-cyclitis:

Is common with pauci-articular juvenile rheumatoid arthritis.

4. Systemic lupus erythematosus and polyarteritis nodosa:

Produce a variety of retinal and choroidal vascular occlusions with the most common manifestation being cotton-wool spots of the retina.

4. Endocrinal Disorders

1. Metabolic cataract can be seen in diabetes, Cushing's syndrome and hypo parathyroidism.
2. Proptosis and extra-ocular muscle disorders are seen in dysthyroid eye disease.
3. Retinal changes in diabetes.
4. Optic nerve compression and bitemporal hemianopia are common manifestations of pituitary chromophobe adenomas.

Ocular Manifestations of Diabetes:

1. Lids:

- Recurrent styes.
- Xanthelasma.
- Blepharitis.

2. Cornea:

- Recurrent corneal erosions.

3. Iris:

- Rubeosis iridis.
- Diabetic iritis.

4. Retina:

- Diabetic retinopathy.

5. The lens:

- Cataract
 - a. True diabetic cataract.
 - b. Presenile cataract.

6. Changes in refraction:

- Hyperglycemia causes myopia.
- Hypoglycemia causes hypermetropia.

7. Optic Nerve:

- Diabetic neuritis.
- Optic atrophy.
- Ischemic optic neuropathy.

8. Paralytic squint: The commonest is lateral rectus paralysis.

5. Metabolic Diseases

1. Metabolic cataract (Sun-flower cataract) can be seen in Galactosaemia, renal rickets as Lowe's syndrome and in Wilson's diseases.
2. Subluxated lens is seen in Marfan's syndrome and Homocystinuria.
3. Corneal rings are seen in Wilson's disease and hyper-cholesterolaemia.
4. Corneal infiltrates and oedema is a common manifestation of Mucopolysaccharidosis and corneal crystals are seen in Cystinosis.
5. Lid nodules (Xanthelasma) are a common feature of hyper-lipidaemias.
6. Cherry-red spot of the fovea is a common finding in Sphingo-lipidoses and Muco-lipidoses as Tay-Sachs disease and Niemann-Pick disease.
7. Optic atrophy is common in many end-stage metabolic disorders.

6. Nutritional Deficiencies

1. Vitamin A deficiency:

Causes xerosis of the conjunctiva, keratomalacia in severe cases and night blindness.

2. Vitamin B deficiency:

As in beri-beri and tobacco-alcohol amblyopia can produce ophthalmoplegia, various scotomas and finally optic atrophy.

3. Vitamin C and other anti-oxidants deficiency:

May predispose to cataract and age-related macular degeneration (ARMD).

7. Drug and Chemical Intoxication

1. Blepharo-conjunctivitis:

Is common with much topical and systemic medication causing:

- Allergy as with the use of sulphonamides.
- Darkening of the conjunctiva (Argyrosis) due to prolonged use of topical and systemic Silver preparations.

- Lid and conjunctival pigmentation can occur with prolonged use of Latanoprost and Epinephrine (anti-glaucoma medications).
 - Immuno-Suppressive drugs can cause bacterial and fungal infections.
2. Corneal deposits in a vortex manner can be seen in Amiodarone therapy and various Quinine derivatives. Copper deposit causes a blue-green corneal arcus in Wilson's disease (Kayser-Fleisher ring).
 3. Cataract is a common feature of long-term corticosteroid therapy as well as open angle glaucoma.
 4. Closed angle glaucoma can occur in predisposed eyes with the use of atropine derivatives as antispasmodics and antidepressants.
 5. Changes in the pupil size occur with drugs affecting the autonomic nervous system. Paresis of accommodation is common with atropine derivatives while spasm of accommodation occurs with organo-phosphorus poisons.
 6. Paresis of the extra-ocular muscles is seen with chronic lead poisoning as well as central nervous system depressant medications leading to binocular diplopia.
 7. Retinal toxicity is a feature of chronic therapy with Phenothiazines (pigmentary retinopathy), Chloroquines (maculopathy) and Tamoxifen (used in breast cancer therapy).
 8. Papilledema and increased intra-cranial tension can occur with chronic therapy with vitamin A, Corticosteroids and Tetracyclines.
 9. Optic atrophy can occur from various intoxications as Methyl alcohol, Lead poisoning, anti-tuberculous drugs.

Chapter 18

LASER in Ophthalmology

Definition:

The word LASER is derived from a concise definition of their mechanism of action "Light Amplification by Stimulated Emission of Radiation".

Character:

1. Mono-chromatic (one wave length).
2. Uni-directional (parallel to each other with little tendency to diverge over distance).
3. Coherent (its waves moves in phase to strengthen each other).

Uses of Lasers in Ophthalmology:

According to their mechanism of action in the eye types of LASER were divided into:

- I) Photo coagulating.
- II) Photo disrupting.
- III) Photo vaporizing.
- VI) Photo dynamic.

I) Photo Coagulating Laser

Principle:

- Depends on absorption of LASER by ocular pigments such as Xanthophyl, Melanin and Haemoglobin.
- LASER energy is converted into heat to induce coagulation.

Types:

- a. Gas as Argon (wave length 532).
- b. Solid as Diode (wave length 910).

Indications:

A. Anterior Segment:

1. Removal of eye lid tumors.
2. Destroying lash roots in trichiasis.
3. Cutting sutures (after cataract & glaucoma operations).
4. Iridotomy for treatment of closed angle glaucoma.
5. Trabeculoplasty for treatment of open angle glaucoma.
6. Cyclo-photo-coagulation of the ciliary processes to treat resistant glaucoma.

B. Posterior Segment:

1. Pan Retinal Photocoagulation (PRP) the most common indication for treatment of Proliferative Diabetic Retinopathy (PDR) and central retinal vein occlusion (CRVO).
2. Macular edema.
3. Destruction of intraocular tumors.

Complications:

1. Cornea:

- Burns and erosions.

2. Iris:

- Burns, iris atrophy and sphincter damage.

3. Lens:

- Cataract.

4. Retina and Choroid:

- Foveal damage.
- Retinal and choroidal hemorrhage.
- Occlusion of retinal vein or artery.

- Night blindness due to constriction of visual field.
- Decrease in visual acuity.

II) Photo Disrupting Laser

Principle:

High power pulses causing optical breakdown of membranes or thin tissues.

Types:

Gases as Neodymium-Yttrium-Aluminium Garnet (Nd-YAG) LASER (wave length 1064).

Indications:

A. Anterior Segment:

1. Posterior capsulotomy after cataract surgery which is the most common indication.
2. Iridotomy for treatment of chronic closed angle glaucoma.
3. Breaking of synechiae following irido-cyclitis.

B. Posterior segment

- Breaking of vitreous strands or membranes.

Complications:

- Bleeding.
- Rise of intraocular pressure.
- Damage of adjacent structures.

III) Photo Vaporizing Laser

Principle:

- LASER causes breakdown of bonds between molecules of tissues leading to their vaporization.

- It can not penetrate more than few microns of tissues (hence safe for use on the cornea).

Types:

Gas as Argon- Fluoride (Excimer) LASER

Indications:

1. Correction of refractive errors (myopia, hypermetropia and astigmatism).
2. Fine excision of abnormal corneal tissues (plaques or nodules).

Complication:

1. Regression of some myopia.
2. Recurrent corneal erosions.
3. Dryness.
4. Decreased night vision.

IV) Photo Dynamic Therapy Laser (PDT):

Principle:

Depends on intravenous injection of a radio-active substance which has a great affinity to abnormal vascular tissues, then this tissues are exposed to certain types of LASER of longer wavelengths to destroy it.

Types:

Solid as Diode LASER

Indications:

Treatment of sub-retinal neo-vascular membranes at the macular area.

Complications:

1. Recurrence of the membrane.
2. Destruction of the macula.
3. Bleeding.

Chapter 19

Differential Diagnosis

Sudden Unilateral Impairment of Vision:

1. Occlusion of the central retinal artery.
2. Thrombosis of the central retinal vein.
3. Acute congestive glaucoma.
4. Massive vitreous hemorrhage.
5. Massive retinal hemorrhage.
6. Detachment of the retina involving the macular area.
7. Acute optic neuritis.
8. Ocular injuries, e.g. avulsion of the optic nerve.
9. Amaurosis fugax, i.e. a transient episode of monocular blindness, Lasting ten minutes or less. It may be caused by spasm of the central retinal artery, e.g. in severe hypertension. *Amaurosis* means blindness occurring without any apparent lesion of the eye.

Sudden Bilateral Impairment of Vision:

1. Optic neuritis caused by a demyelinating disease.
2. Uremic amaurosis (blindness due to uremia).
3. Cranial (giant cell) arteritis.
4. Severe head injuries leading to concussion blindness.
5. Hysteria and malingering.
6. Quinine poisoning.

Gradual Diminution of Vision:

1. Cornea:

- (a) Keratitis of any form.
- (b) Corneal dystrophies.
- (c) Keratoconus.
- (d) Corneal edema.

2. Refractive Errors:

- (a) Myopia.
- (b) Hypermetropia.
- (c) Astigmatism.
- (d) Presbyopia.
- (e) Refractive changes caused by mechanical lid pressure, e.g. a large chalazion of the upper lid.

3. Glaucoma:

- (a) Chronic simple glaucoma.
- (b) Secondary glaucoma from any cause.

4. Lens:

- (a) Nuclear sclerosis.
- (b) Opacification of the lens from any cause, e.g. senile cataract.
- (c) Refractive changes resulting from dislocation or subluxation of the lens.

5. Uveal Tract:

- (a) Inflammation of the uveal tract: Anterior or posterior uveitis.
- (b) Sympathetic ophthalmitis.
- (c) Neoplasm, e.g. malignant melanoma.

6. Vitreous:

- (a) Massive hemorrhage in the vitreous.
- (b) Vitreous opacities and degeneration.

7. Retina:

- (a) Thrombosis of a branch of the central retinal vein.
- (b) Macular degeneration.
- (c) Tapeto-retinal degeneration e.g. retinitis pigmentosa.
- (d) Toxic amblyopia.
- (e) Retinopathies e.g. diabetic retinopathy.
- (f) Retinal Detachment.
- (g) Retinal tumors, e.g. retinoblastoma.

8. Optic Nerve:

- (a) Chronic optic neuritis.
- (b) Optic atrophy.
- (c) Tumors e.g. glioma of the optic nerve.

Transient Visual Loss:

1. Amaurosis fugax.
2. Migraine.
3. Transient ischemic attacks (carotid artery disease).

Night blindness:

1. Vitamin A deficiency in alcoholics and nutritional disorders.
2. Congenital night blindness.
3. Retinitis pigmentosa.
4. Advanced stages of chronic glaucoma.
5. Cortical cataract.
6. High degenerative myopia.

Day blindness:

1. Central corneal opacity.
2. Nuclear cataract.
3. Macular Lesions.

Color blindness:

1. Congenital.
2. Macular lesion (e.g. senile degeneration, edema).
3. Optic nerve lesion (e.g. papillitis, papilledema).

Diplopia:

a. Monocular diplopia:

1. Iridodialysis.
2. Peripheral Iridectomy or Iridotomy.
3. Essential iris atrophy.
4. Early cortical cataract.
5. Subluxation of the lens.
6. Unilateral Aphakia (if correct with eyeglasses).
7. Eccentric IOL (Lateral, Up, Down).
8. Hysteria or as a manifestation of neurosis.

b. Binocular diplopia:

1. Paralytic squint in the direction of action of the paralyzed muscle (3rd, 4th, 6th nerve palsy).
2. Myasthenia gravis.
3. Proptosis (Lateral, Up, Down).
4. Decompensated latent squint.
5. Convergence insufficiency.
6. Thyrotoxicosis.

7. Disseminated sclerosis.
8. Diabetes mellitus.
9. Intra-cranial neoplasms.

Defective near vision:

1. Presbyopia.
2. Hypermetropia.
3. Paralysis of accommodation (e.g. atropine).
4. Aphakia.

Photophobia:

1. Congenital glaucoma.
2. Foreign body (corneal or conjunctival).
3. Corneal abrasion or ulcer.
4. Iridocyclitis.
5. Keratitis.
6. Acute angle closure glaucoma.

Pain:

1. Burning: Catarrhal or viral conjunctivitis.
2. Itching: Spring catarrh, angular conjunctivitis.
3. Gritty = Sandy = Foreign Body Sensation: Foreign Body, follicular conjunctivitis, papillary conjunctivitis, PTDs.
4. Aching: Errors of refraction, latent squint.
5. Neuralgic (Neurogenic): Keratitis, Iritis, Cyclitis.
6. Bursting: Acute congestive glaucoma.
7. Throbbing: Stye, Hordeolum Internum, Endophthalmitis, Panophthalmitis.

Orbital pain:

1. Retrobulbar neuritis.
2. Orbital cellulitis.
3. Orbital periostitis (injury, TB, syphilis, extension from sinus disease).
4. Myositis (Collagen disease, myositis).
6. Trauma to the orbit.

Acute proptosis:

1. Traumatic (Hemorrhage & emphysema).
2. Orbital cellulitis.
3. Cavernous sinus thrombosis.
4. Panophthalmitis.
5. Acute ethmoiditis.
6. Acute dacryo-adenitis.
7. Acute periosteitis.

Vitreous floaters (musca volitanis):

1. Vitreous degenerations.
2. Posterior uveitis
3. Vitreous hemorrhage.
4. Vitreous detachment.

Leukocoria (Amaurotic Cat's Eye):

1. Cataract.
2. Retinoblastoma.
3. Retinopathy of prematurity (ROP).
4. Persistent hyperplastic primary vitreous (PHPV).
5. Coat's disease.
6. Endophthalmitis.
7. High myopia with chorioretinal degeneration.
8. Cyclitic membrane.
9. Medullated nerve fibers of retina.

Mydriasis:

- 1. Physiological:** Myopia, blue irides, general anesthesia.
- 2. Drugs (Pharmacological):** Phenylephrine, Adrenaline, Atropine, Homatropine, Hyoscine, Cyclopentolate, Tropicamide.
- 3. Ocular diseases:** Acute angle closure glaucoma, absolute glaucoma, optic atrophy, **CRAO**, retinal detachment, trauma.
- 4. Neurological:** Oculomotor nerve palsy, coma.

Miosis:

- 1. Physiological:** (hypermetropia, dark irides, third stage of anesthesia).
- 2. Drugs (Pharmacological):** Eserine, Pilocarpine, Carbachol, Phospholine iodide.
- 3. Ocular diseases:** (acute iritis, trauma).

4. **Neurological:** (Horner's syndrome, Argyl- Robertson pupil, pontine hemorrhage, Hutchinson's pupil in extradural hemorrhage).

Irregular pupil:

1. Anterior & posterior synechiae.
2. Leucoma adherent.
3. Iridodialysis.
4. Congenital coloboma.
5. Post-operative sector iridectomy.

Cherry Red Spot:

1. Central retinal artery occlusion.
2. Quinine poisoning.
3. Commotio retinae (central retinal edema).
4. Cerebro-Macular degeneration: Tay Sach's disease.

Retinal Hemorrhage:

1. Diabetic retinopathy.
2. Retinal Vein occlusion.
3. Hypertensive Retinopathy.
4. Papilledema & Papillitis.
5. Blood diseases (anemia, leukemia).
6. Systemic infections (AIDS, subacute bacterial endocarditis).

Subretinal Hemorrhage:

1. Trauma.
2. Choroidal tumors (malignant melanoma, hemangioma).
3. Sub-retinal choroidal neovascular membranes (CNV).

Hard Retinal Exudates (Serofibrinous & Cholesterol):

1. Diabetic retinopathy.
2. Hypertensive retinopathy.
3. Toxemia of pregnancy (Eclamptic retinopathy).
4. Malignant hypertensive retinopathy.
5. Renal failure (Uremic retinopathy).
6. Papilledema (macular star).
7. Old cases of retinal vein occlusion.
8. Age related macular degeneration.

Corneal pannus:

1. Trachoma.
2. Phlycten.
3. Spring catarrh.
4. Degenerative.
5. Leprosy.

Shallow Anterior Chamber:

1. Short axial length: Hypermetropia and microphthalmos.
2. Acute angle closure glaucoma.
3. Pupillary block: Intumescent cataract, anterior dislocation of the lens and occlusio pupillae.

Deep Anterior Chamber:

1. Aphakia.
2. Posterior dislocation of the lens.
3. High myopia.
4. Hypermature dry type of cataract.
5. Buphthalmos.

Irregular anterior chamber:

1. Leucoma adherent.
2. Subluxation of the lens.
3. Anterior staphyloma.
4. Iris bombe.
5. Iris tumors.

Corneal Hypoesthesia & Anesthesia:

1. Herpetic keratitis.
2. Neuropathic Keratopathy.
3. Leprosy.
4. Glaucoma (Acute & Absolute).
5. Corneal dystrophies.
6. Anesthetic eye drops: (Benoxinate, Tetracaine, Proparacaine).

Hyphema (Blood in anterior chamber):

1. Trauma.
2. Severe iritis e.g. herpetic.
3. Intra-ocular tumor.
4. Neovascularization of Iris (Rubeosis irides).

Rubeosis Irides:

1. Proliferative Diabetic Retinopathy (PDR).
2. Central Retinal Vein Occlusion (CRVO).
3. Chronic uveitis (Tuberculosis & Syphilitic).
4. Intra-ocular tumors.

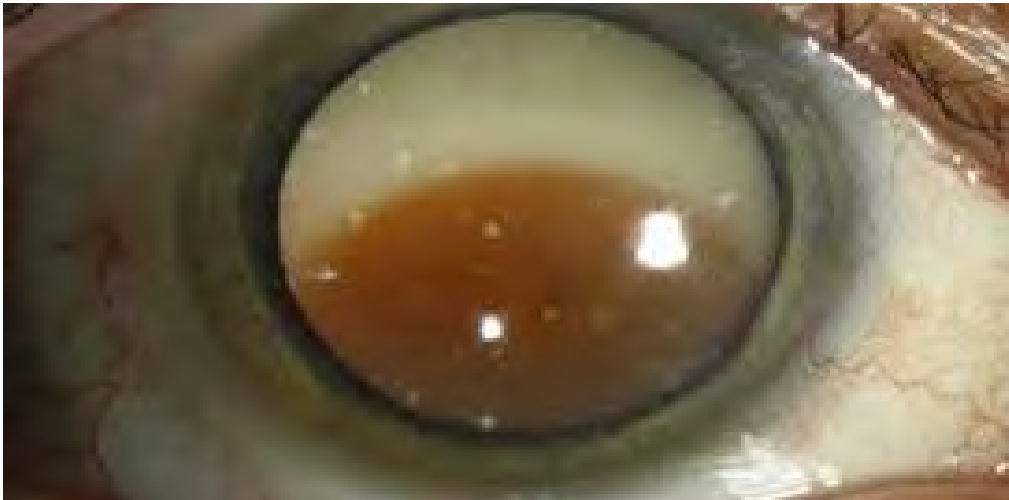Hypopyon (Pus in anterior chamber):

1. Hypopyon corneal ulcer.
2. Acute iridocyclitis.
3. Necrotic intra-ocular tumors.

Chapter 20

Problem solving

Case 1:



A 68-year-old man complained of a painless gradual fall in vision over the last 12 months. He experienced difficulty with vision for both near and distance. He had to stop driving.

- A) List 3 major diagnostic possibilities for painless gradual diminution of vision.
- B) What is your diagnosis? stage and type.
- C) Name 3 complications of this stage.

.....

.....

.....

.....

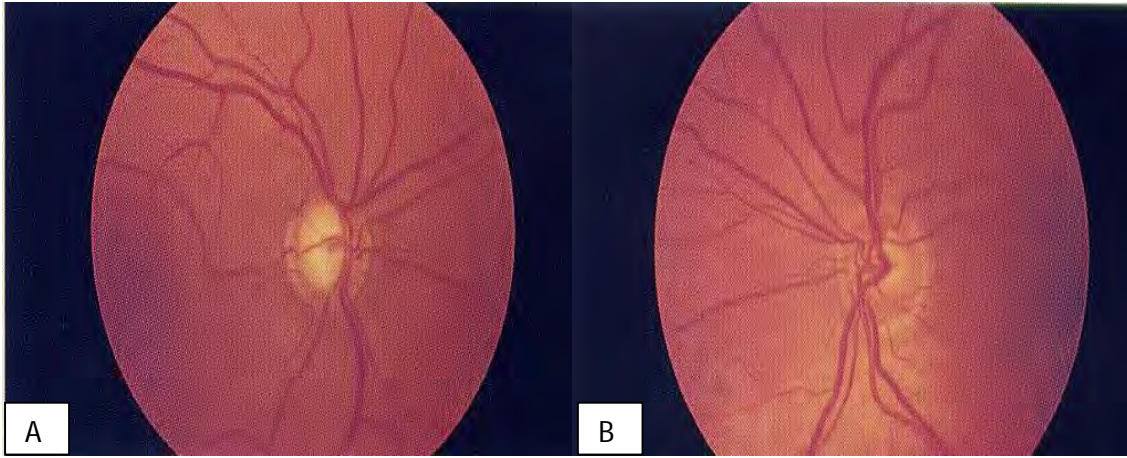
.....

.....

.....

.....

Case 2:



A 56-year-old lady complained of a painless gradual fall in vision over the past few months. She failed to notice objects and people approaching from the side. When crossing the road, she had to turn her head to be sure of seeing approaching traffic.

- A) Which disc shows advanced stage in these pictures?
- B) What diagnosis would you consider?
- C) What are investigations that must be done?
- D) When crossing the road, she had to turn her head to be sure of seeing approaching traffic. What is the possible cause for this complain?
- E) What is the first line of treatment. Mention another line of treatment.

.....

.....

.....

.....

.....

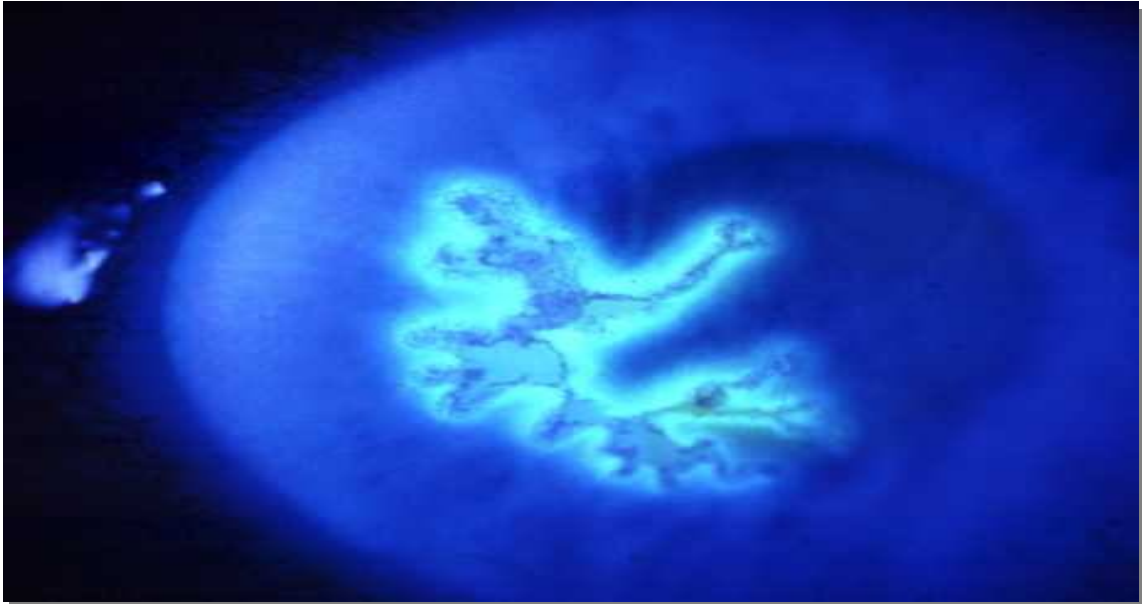
.....

.....

.....

.....

Case 3:



A 35-year-old complained of redness of left eye for the past few days. The conjunctiva was diffusely hyperemic with profuse watery discharge.

- A) What is your diagnosis?
- B) What is the causative organism?
- C) What stain is used in this picture?
- D) Name 2 different medications for treatment of this condition.
- E) Mention one drug contraindicated in that condition.
- F) List 2 important causes of acute red eye with diminished visual acuity and 2 other causes with preserved visual acuity.

.....

.....

.....

.....

.....

.....

.....

.....

.....

.....

.....

.....

.....

.....

.....

.....

.....

.....

.....

.....

.....

.....

Case 4:



A two years old child is brought to clinic by his mother who has noticed a 'white pupil ' in the right eye.

- A) The external appearance examination shows an abnormal ocular position. What is it?
- B) What is the most serious cause of a white pupil in this age?
- C) What is the most common cause of a white pupil in this age?
- D) What is the most important diagnostic investigation for a white pupil?

.....

.....

.....

.....

.....

.....

.....

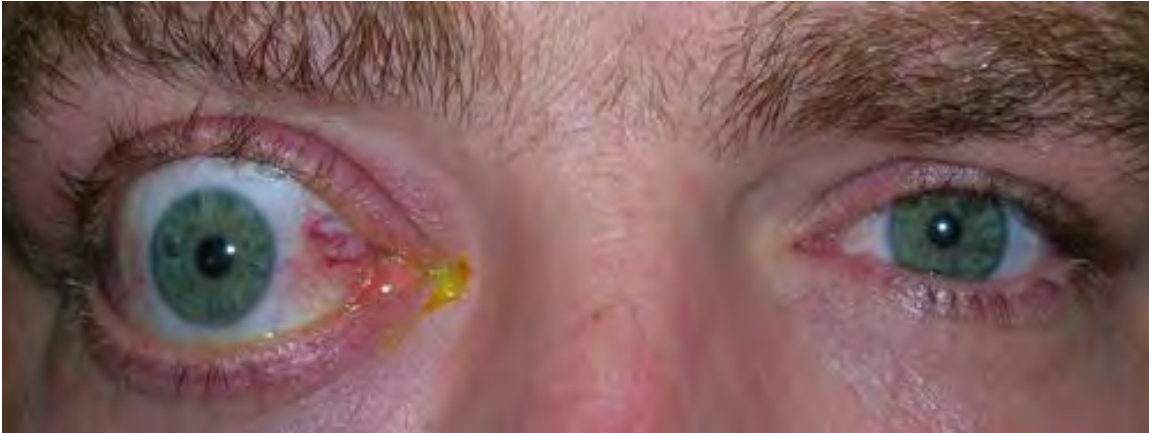.....

.....

.....

.....

Case 5:



A 45-year-old patient complained of increasing protrusion of the right eye and double vision.

Visual acuity is 6/18 in the right eye and 6/9 in the left eye both aided and unaided. Examination reveals the presented picture.

- A) What is the most common cause of unilateral proptosis?
- B) Mention types of diplopia. How do you differentiate between them?
- C) Name 2 different signs seen in the right eye in the presenting photo.

.....

.....

.....

.....

.....

.....

.....

.....

.....

.....

.....

.....

.....

.....

.....

.....

.....

.....

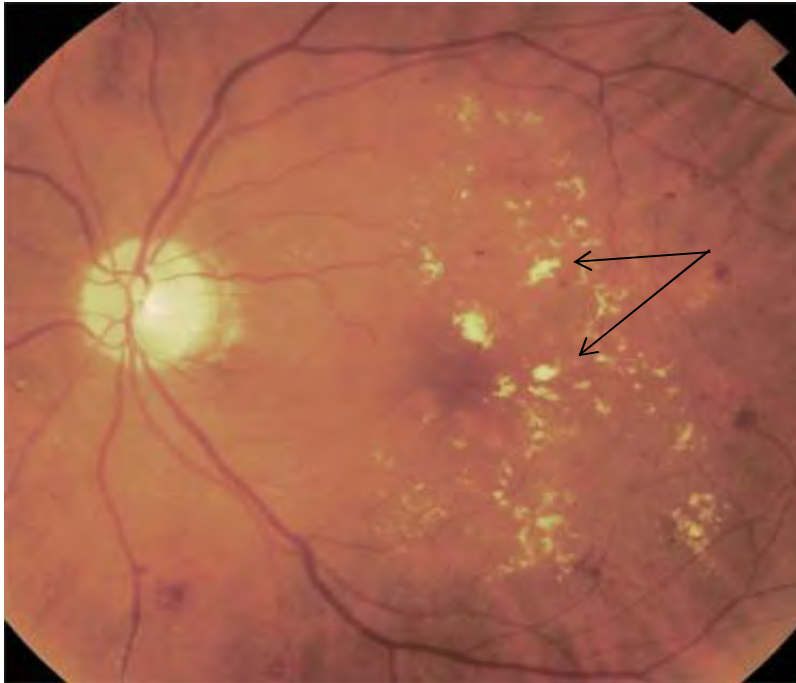
.....

.....

.....

.....

Case 6:



A 59-year-old diabetic patient complained of gradual diminution of vision in his left eye. His vision is 6/6 in the right eye and 6/24 in left eye.

His cornea and lens are clear. His left fundus examination revealed this picture.

- A) What is your diagnosis?
- B) What are the most important two risk factors for this condition?
- C) What do the black arrows point to?
- D) Name one important ophthalmological investigation for the management of this patient.

.....
.....
.....
.....
.....