

ACUTE LIMB ISCHEMIA

AMR M. ELSHAFEI

LECTURER OF VASCULAR SURGERY

DEFINITION

- A sudden decrease of limb perfusion causing a potential threat to limb viability

CAUSES

- **Embolic**

Atrial Fibrillation, Bacterial endocarditis, Myocardial Infarction, arterial aneurysm

- **Thrombotic**

Atherosclerosis, hypercoagulable states, arterial dissection, intraarterial injection

- **Trauma**

stab, gun shot

- **Iatrogenic** accidental ligation

PATHOPHYSIOLOGY

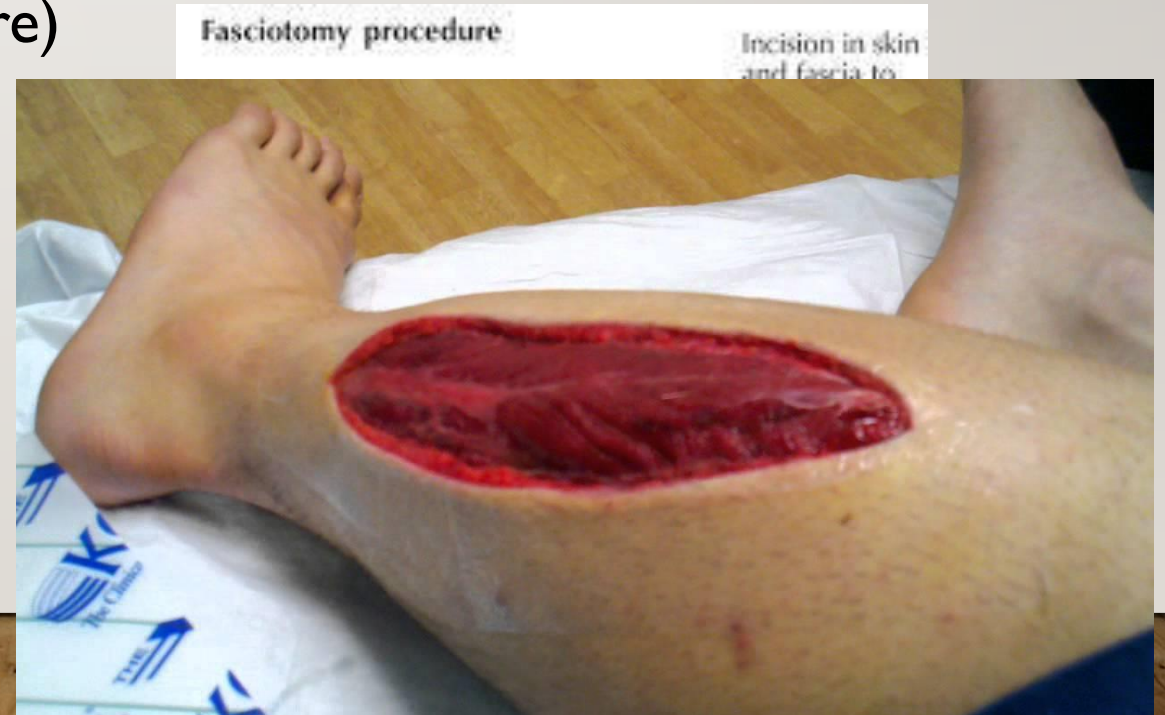- The clinical outcome of any acute ischemia depend on
 1. Size of vessel involved
 2. Degree of obstruction
 3. Amount of collateral blood flow
 4. Timing of intervention

PATHOPHYSIOLOGY

- Ischemia can be aggravated by
 1. Propagation of thrombus
 2. Associated venous thrombosis
 3. Distal migration of embolus

PATHOPHYSIOLOGY

- Systemic effect of acute ischemia
 1. Reperfusion syndrome (muscle infarction, myoglobinemia, myoglobinemic renal failure)
 2. Compartment syndrome



DIAGNOSIS OF ACUTE ISCHEMIA

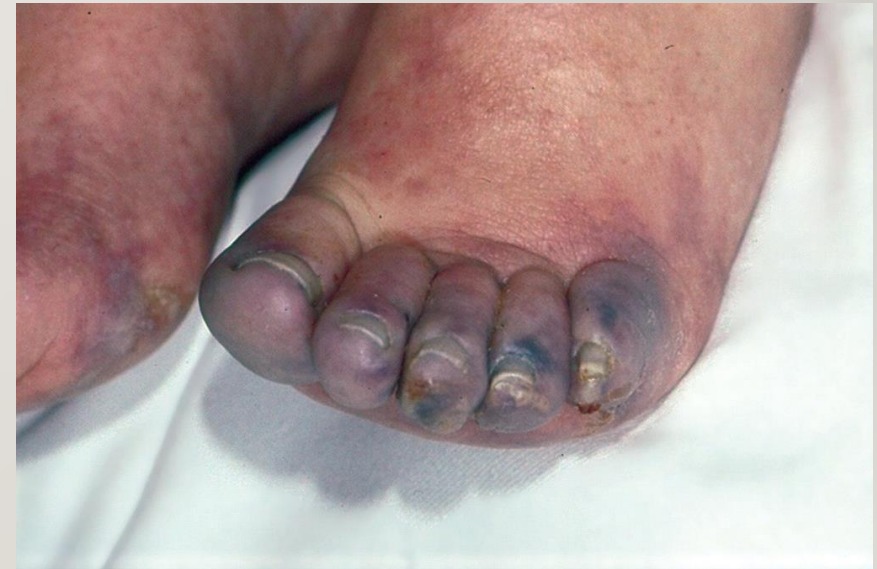

COMPLAINT (SYMPTOMS)

- **pain** severe calf pain and frequently resistant to analgesia.
- **Paralysis** loss of foot movement due to muscle ischemia
- **paraesthesia** tingling and abnormal sensation due to nerve ischemia

HISTORY

- Cardiac problems:
 1. Atrial fibrillation
 2. Valve replacement
 3. Myocardial infarction
- Leg problems : intermittent claudication, trash foot
- Hematological problems:
 1. Protein C deficiency
 2. Protein S deficiency
 3. Factor V leiden mutation
- Malignancy or chemotherapy
- Intra arterial injection

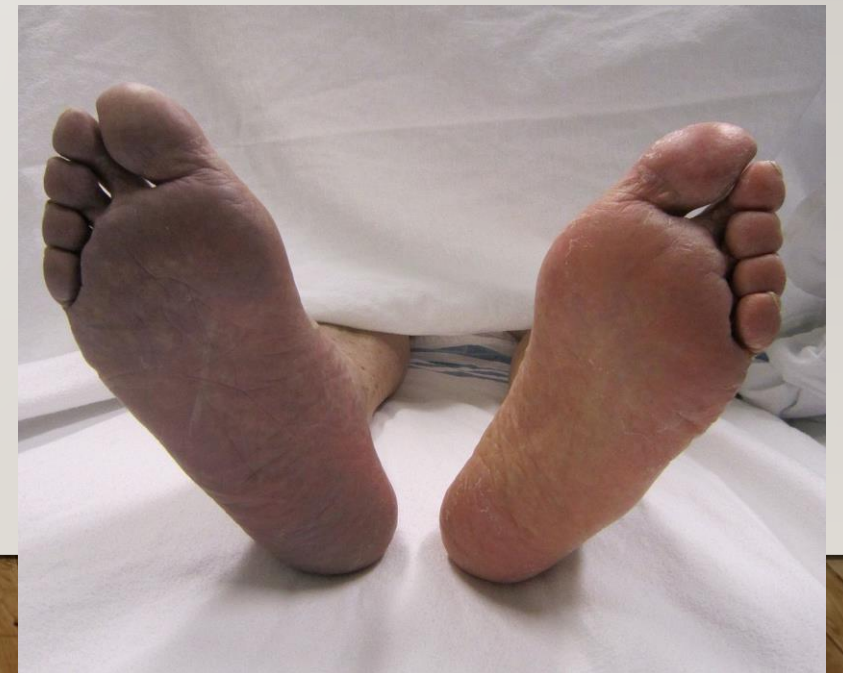
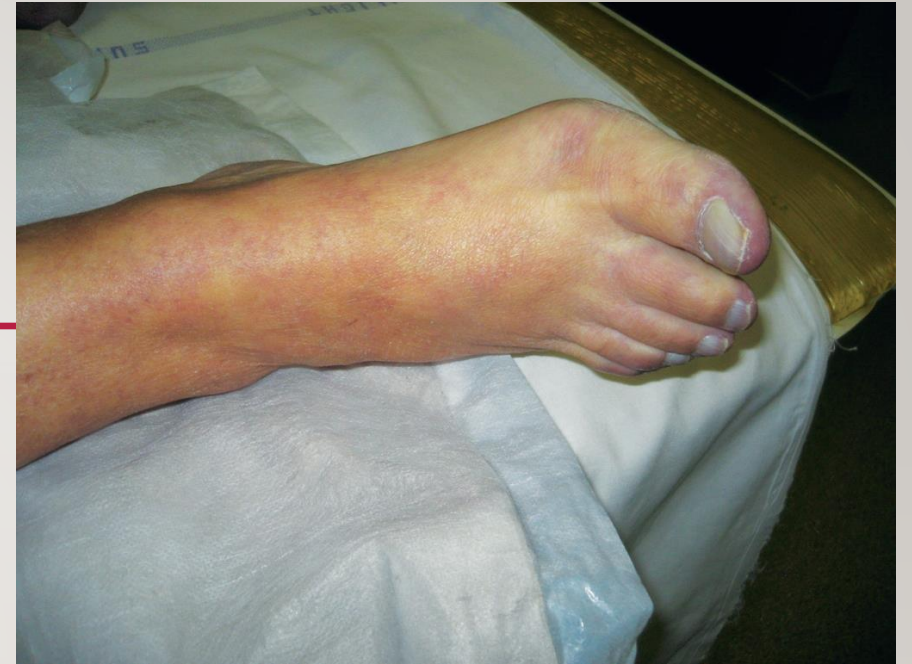
GENERAL EXAMINATION

- Full cardiac assessment including Pulse rhythm: regular or irregular
- Abdominal exam to reveal abdominal aortic aneurysm

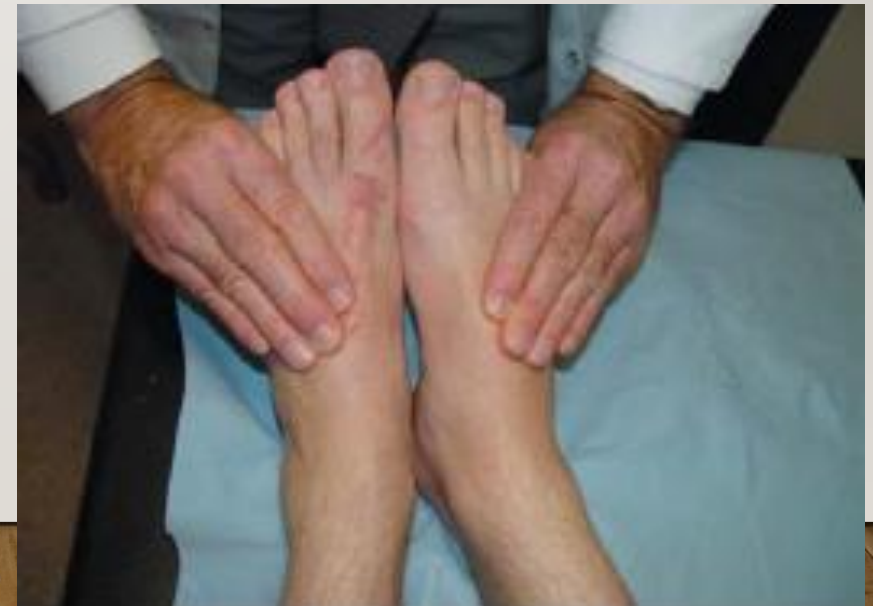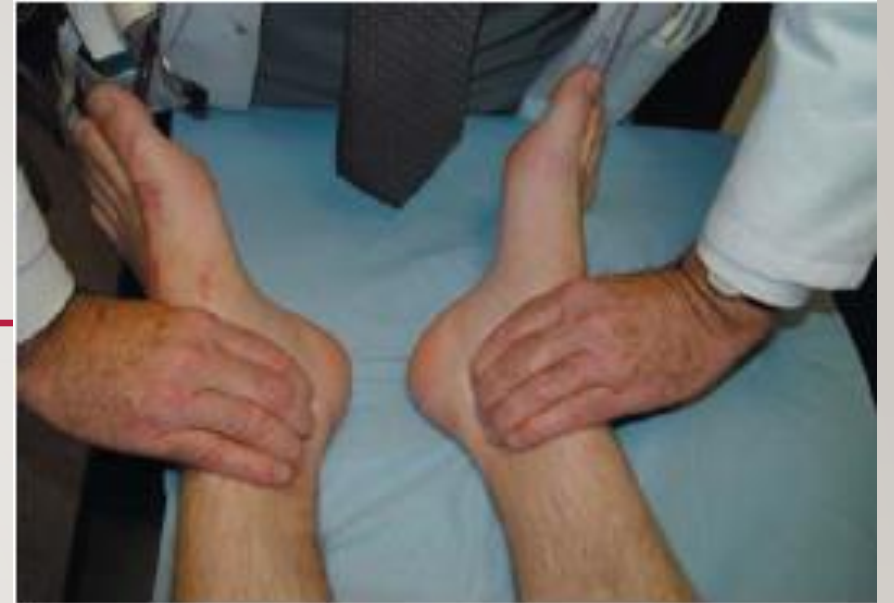LOCAL EXAMINATION INSPECTION

- Color changes
 1. Pale white due to arterial spasm
 2. Mottling due to opening of collaterals (which maybe inadequate) that blanches on pressure
 3. Cyanosis due to dilatation of post capillary venules
 4. Fixed mottling or fixed cyanosis due to disruption of the capillaries that fail to blanch on pressure



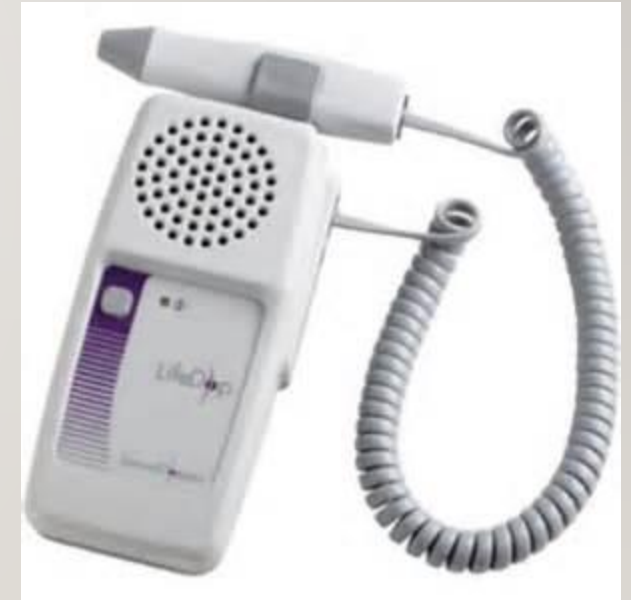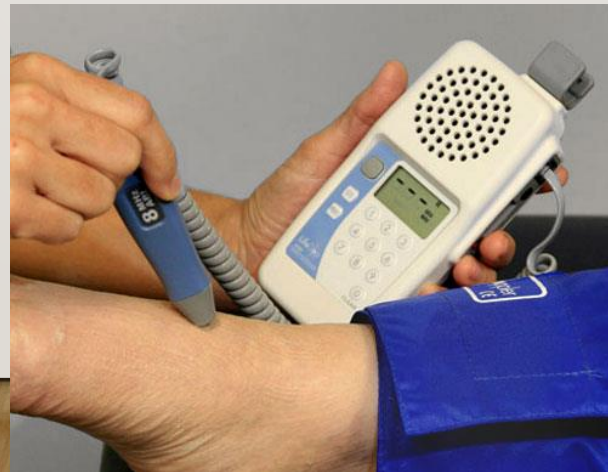LOCAL EXAMINATION PALPATION

1. Feel the temperature
2. Examine the pulses
3. Tenderness of calf muscles
4. Tension of leg compartments
5. Exclude any popliteal, femoral swelling
6. Examination of cervical rib



DOPPLER EXAMINATION

- Reveal reduced or absent pedal arterial signal
- Can assess the patency of venous system
- Strong biphasic arterial signal can exclude the diagnosis of acute ischemia

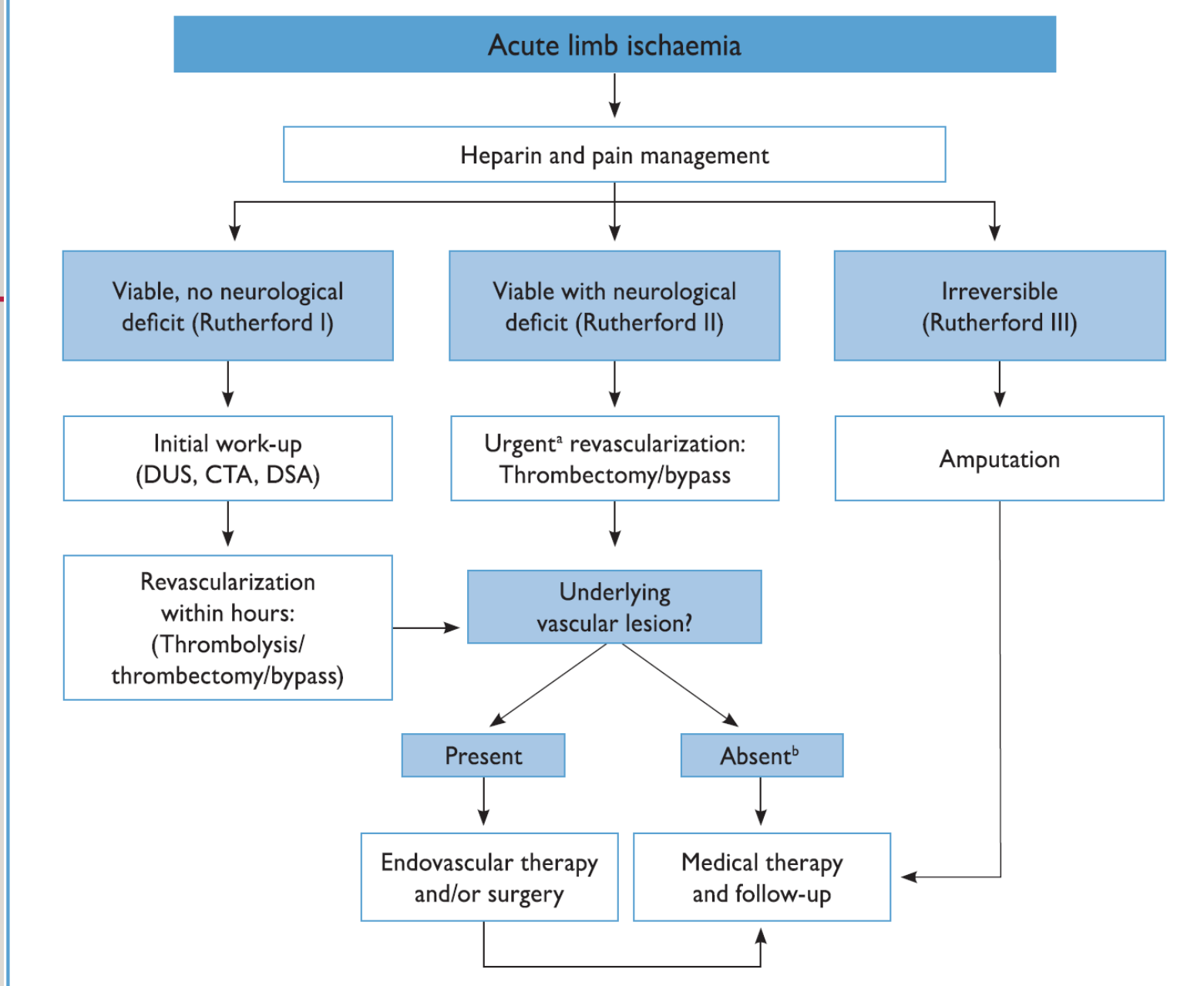


ASSESSMENT OF LEG VIABILITY

Category	Description/Prognosis	Findings		Doppler Signals	
		Sensory Loss	Muscle Weakness	Arterial	Venous
I. viable	Not immediately threatened	NON	NON	Audible	Audible
I.Threatened a.Marginally	Salvageable if promptly treated	Minimal or non	non	Often inaudible	audible
	Salvageable with immediate revascularization	More than toes, often rest pain	Mild, moderate	Usually inaudible	audible
b- Immediately					
III-Irreversible	Major tissue loss or Permanent nerve damage inevitable	Profound, anesthetic	Profound, paralysis (rigor)	inaudible	inaudible

INVESTIGATIONS

- **Computed Tomographic Angiography**
- **Ultrasound**
- **Transfemoral Arteriography**
- **Magnetic Resonance Angiography**



CTA = computed tomography angiography; DSA = digital subtraction ultrasound; DUS = duplex ultrasound.

^aImaging should not delay revascularization.

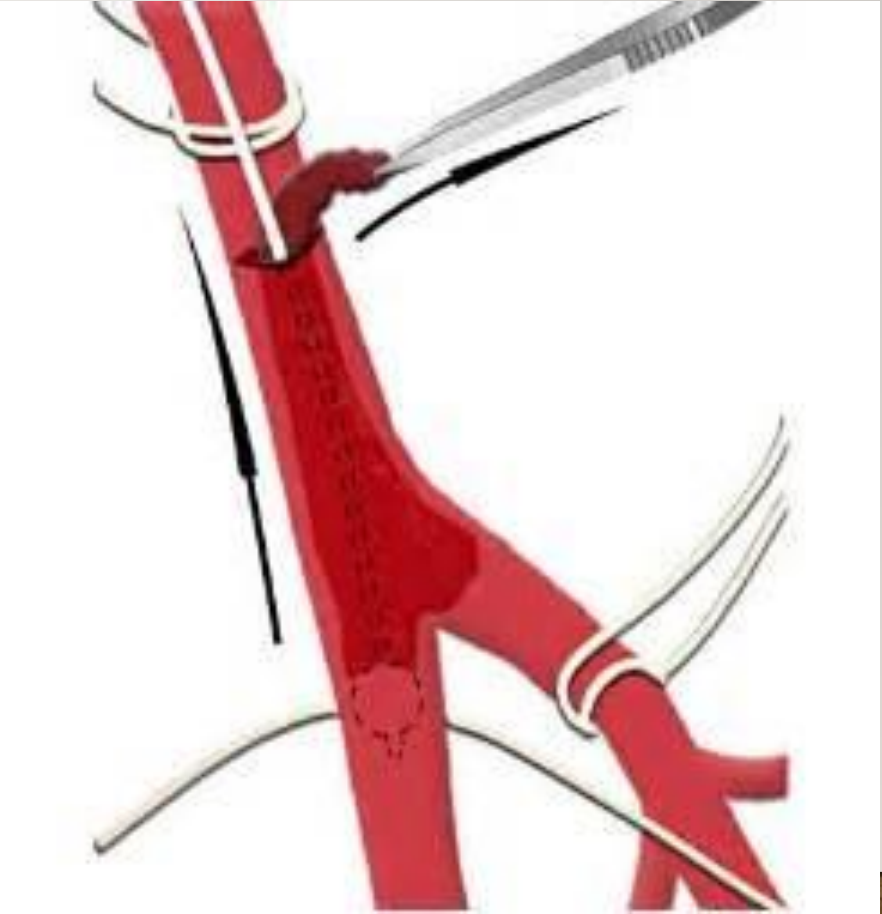

^bSpecific etiological work-up is necessary (cardiac, aorta).

Figure 7. Management of acute limb ischaemia.

MANAGEMENT

- **ENDOVASCULAR TREATMENT**
 - Catheter directed thrombolysis
 - Pharmacomechanical Thrombectomy
 - Percutaneous Mechanical Thrombectomy
- **SURGICAL REVASCULARIZATION**
 - Balloon Catheter Thrombectomy or Embolectomy
 - Bypass Procedures
 - Endarterectomy

TREATMENT



THANK YOU

